

A Cooke's Tour of some recent Parasitology cases

Professor Robin A. Cooke



Infections caused by parasites are usually thought of as being managed by the Microbiology section of a Pathology Department.

However, they are very frequently first diagnosed in the Anatomical Pathology section.

Malaria

is such an important and common disease in the 'Tropical world' that it should be mentioned first

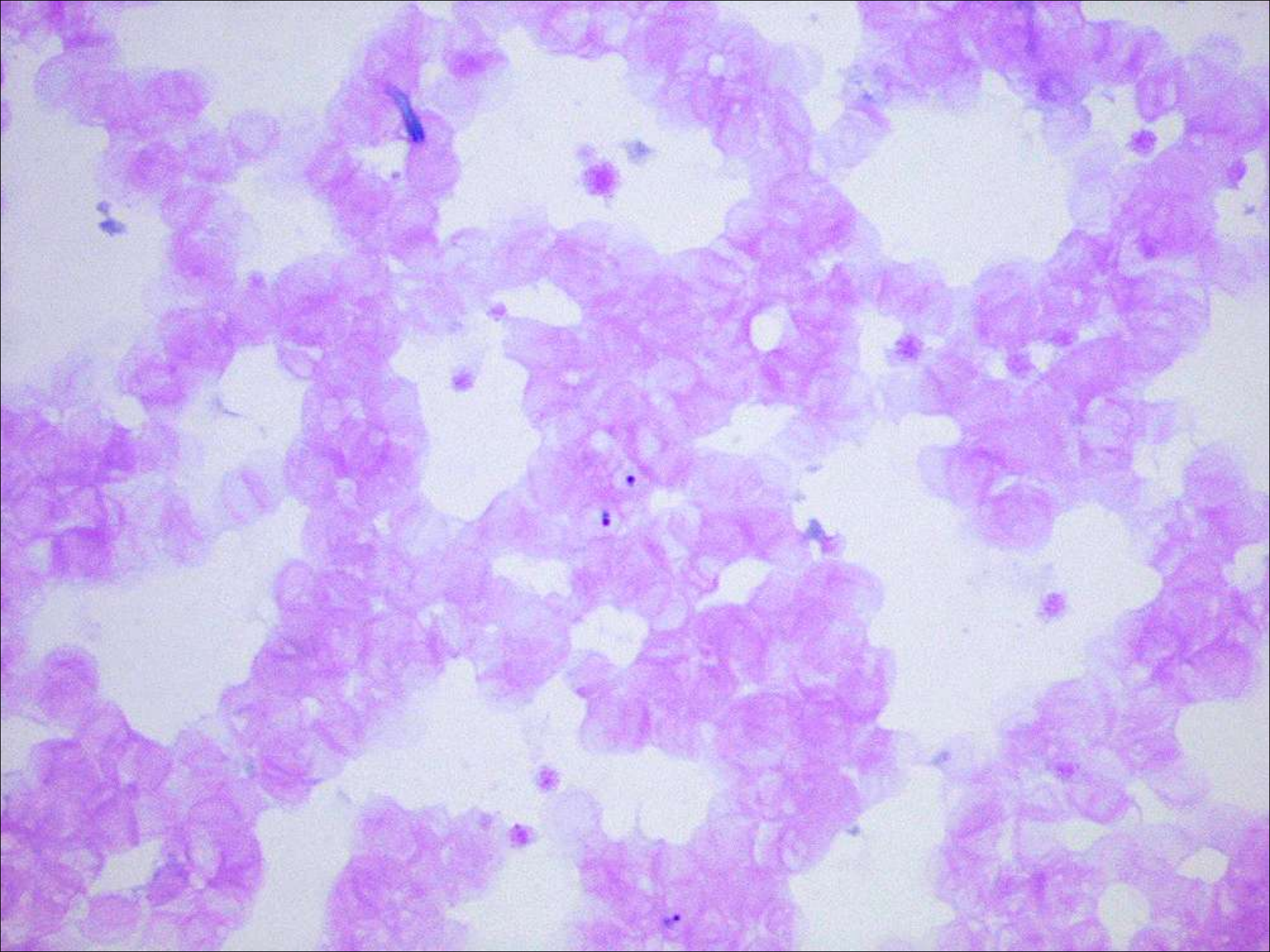
Some clinical features

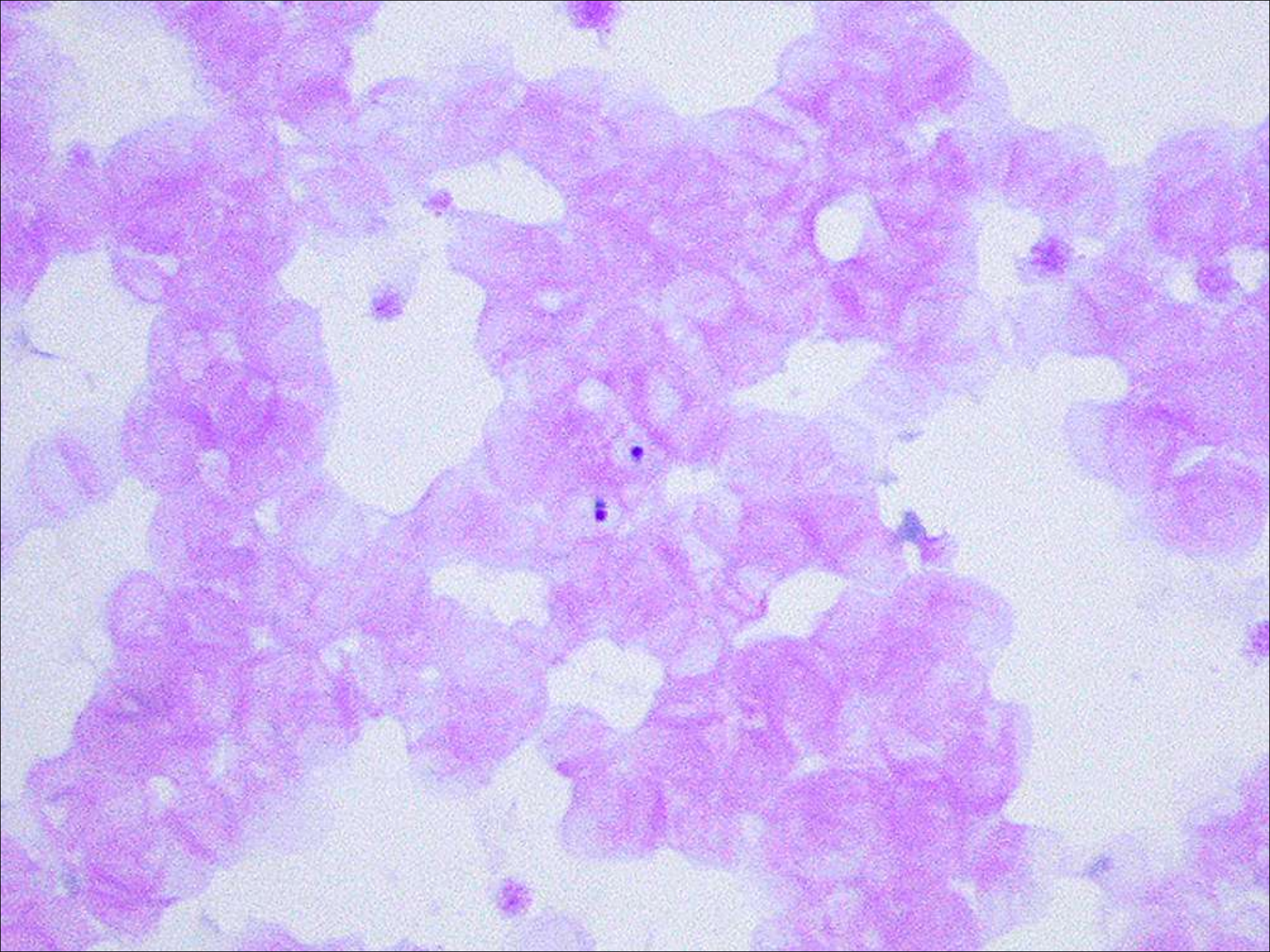
A female aged 40 years presented with a history of two episodes of lethargy, fever, chills and severe headache in the preceding 4 days.

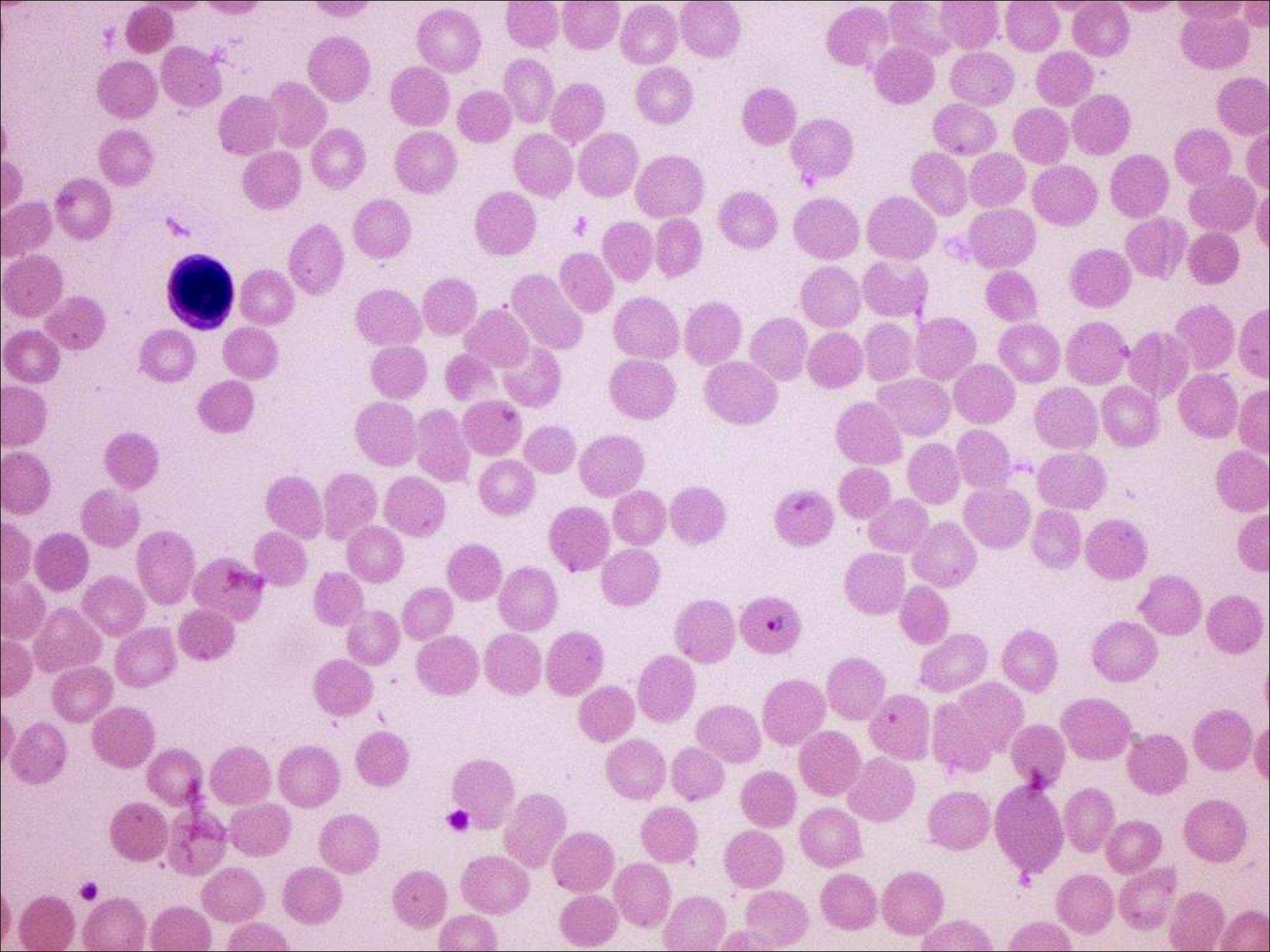
On admission to hospital on 26 May 2009 her temperature was 35.9° C.

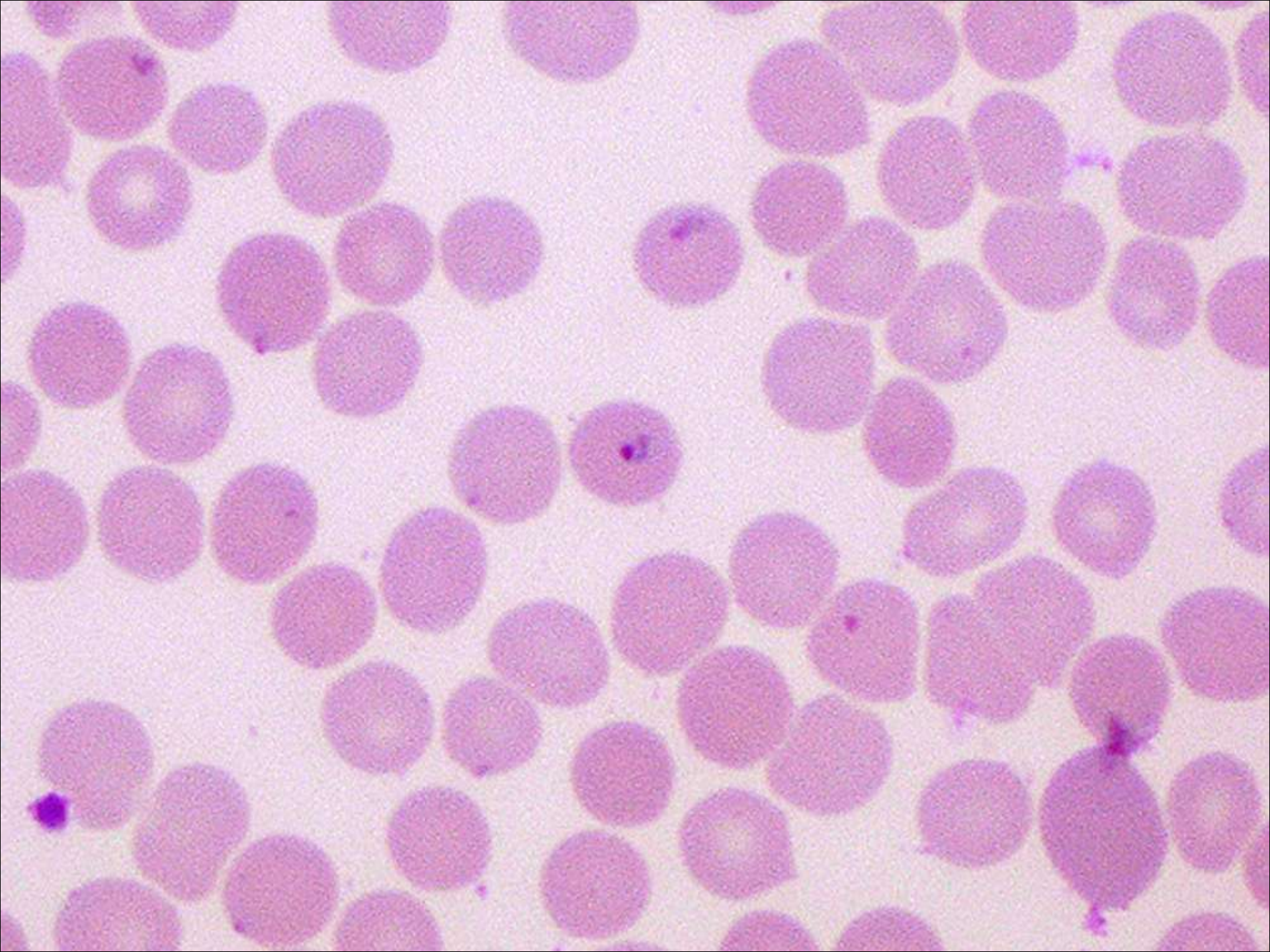
She had no splenomegaly.

Full blood count was done and it showed a low normal WCC with a moderate neutropaenia and moderate numbers of trophozoites (ring forms) of *P. falciparum* present in the red blood cells.









She was treated with Riamet
(Artemether 25 mg tabs) 4 at once,
4 at 8 hours later then another
4 at 24, 36, 48 and 60 hours.

She recovered and went home.

Further history: She was Sudanese and had emigrated to Australia 16 years ago.

9 days before admission she had returned from a 1 month visit to relatives in Kampala, Uganda.

She did not take any malaria prophylaxis.

Cerebral malaria

Presents with many different neurological manifestations

The most bizarre are psychiatric symptoms

One young man was acting very strangely and phoned the police to come and save him from the giant cockroaches that were running around his room.

The policeman thought he was sick and took him to the local hospital.

On admission he was thought to be 'high' on drugs.

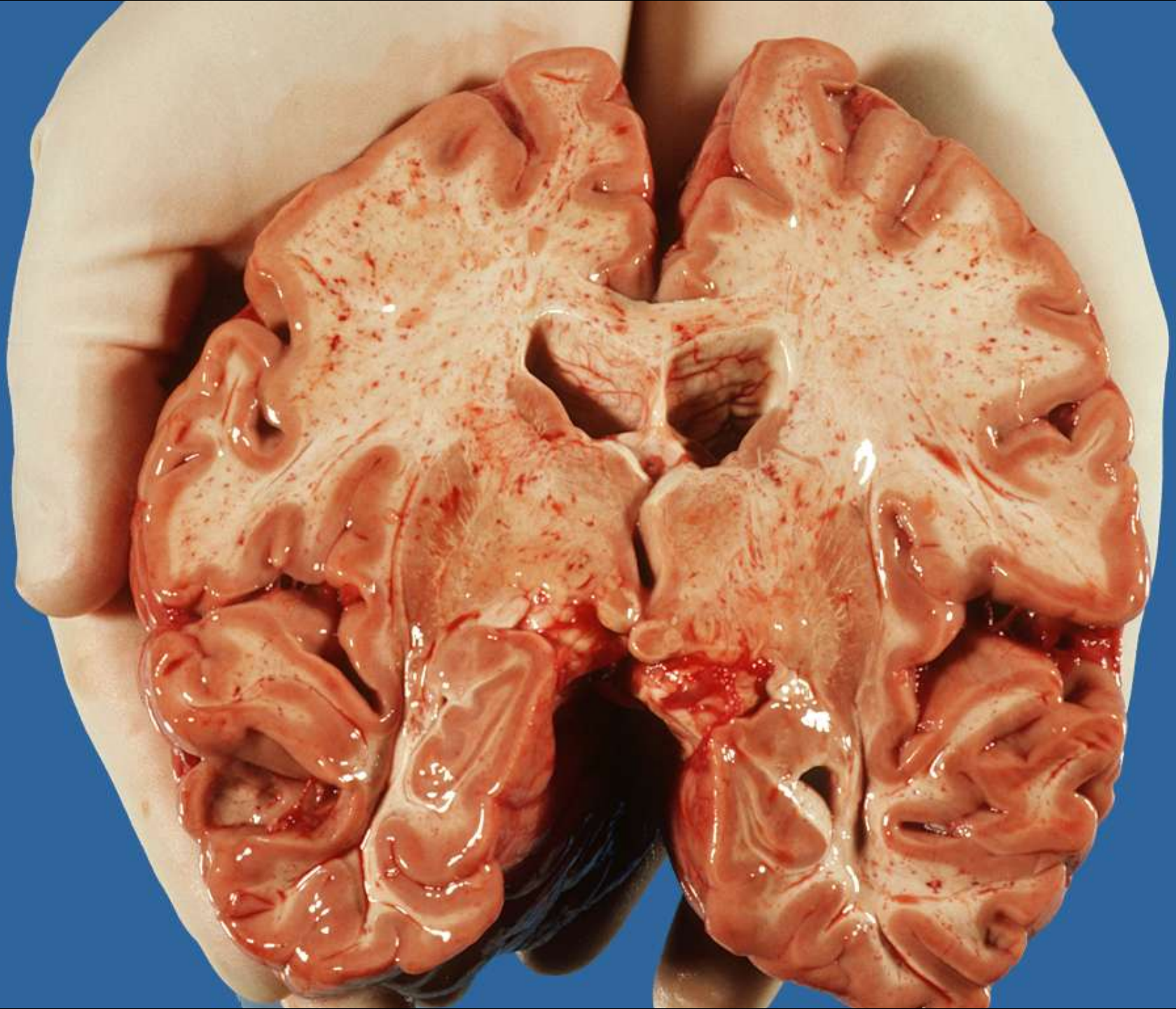
Blood smear showed ring forms and schizonts of *P. falciparum*.

This is usually fatal if it is not treated as a medical emergency.

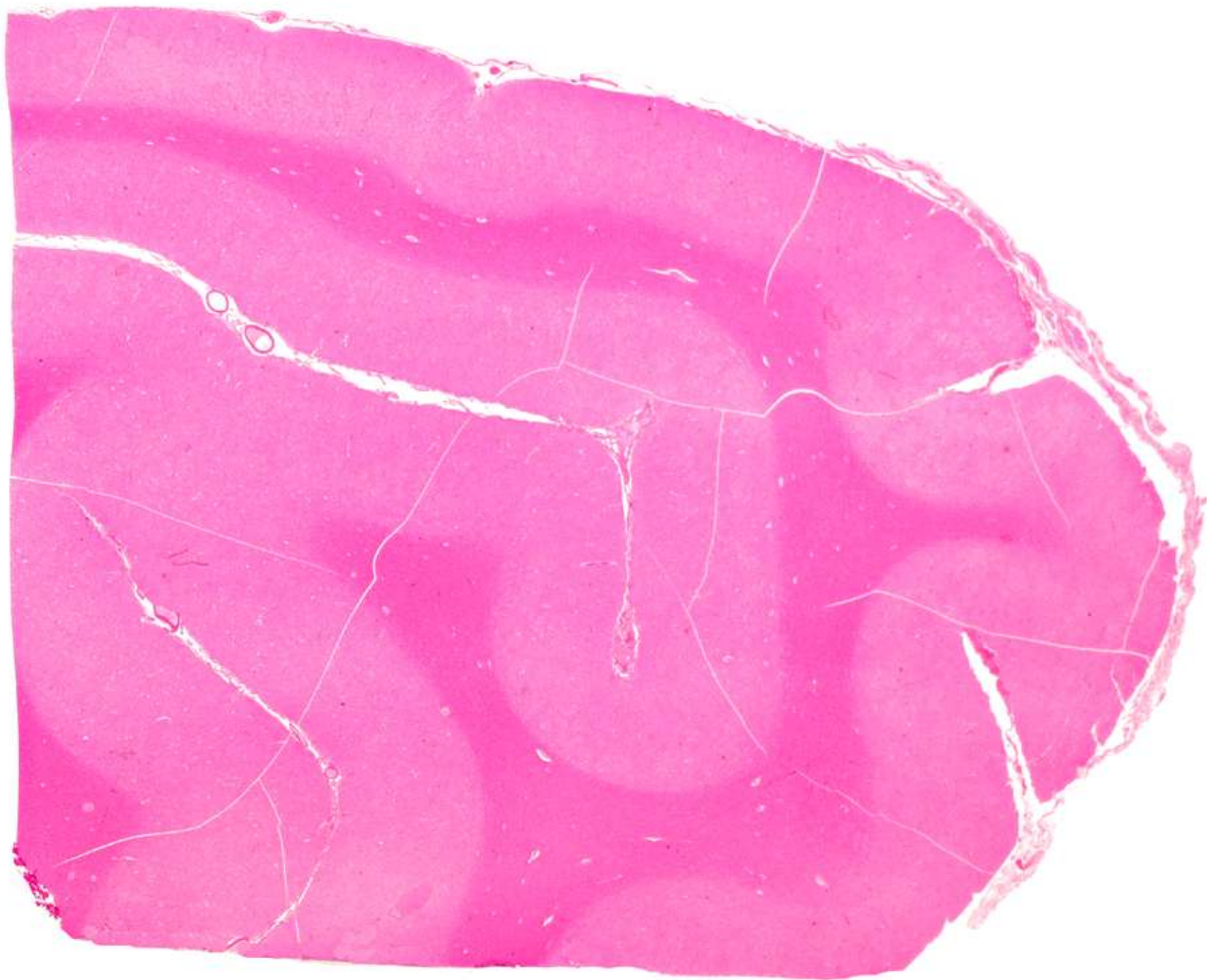I/V quinine sent the cockroaches away and he recovered within a few days.

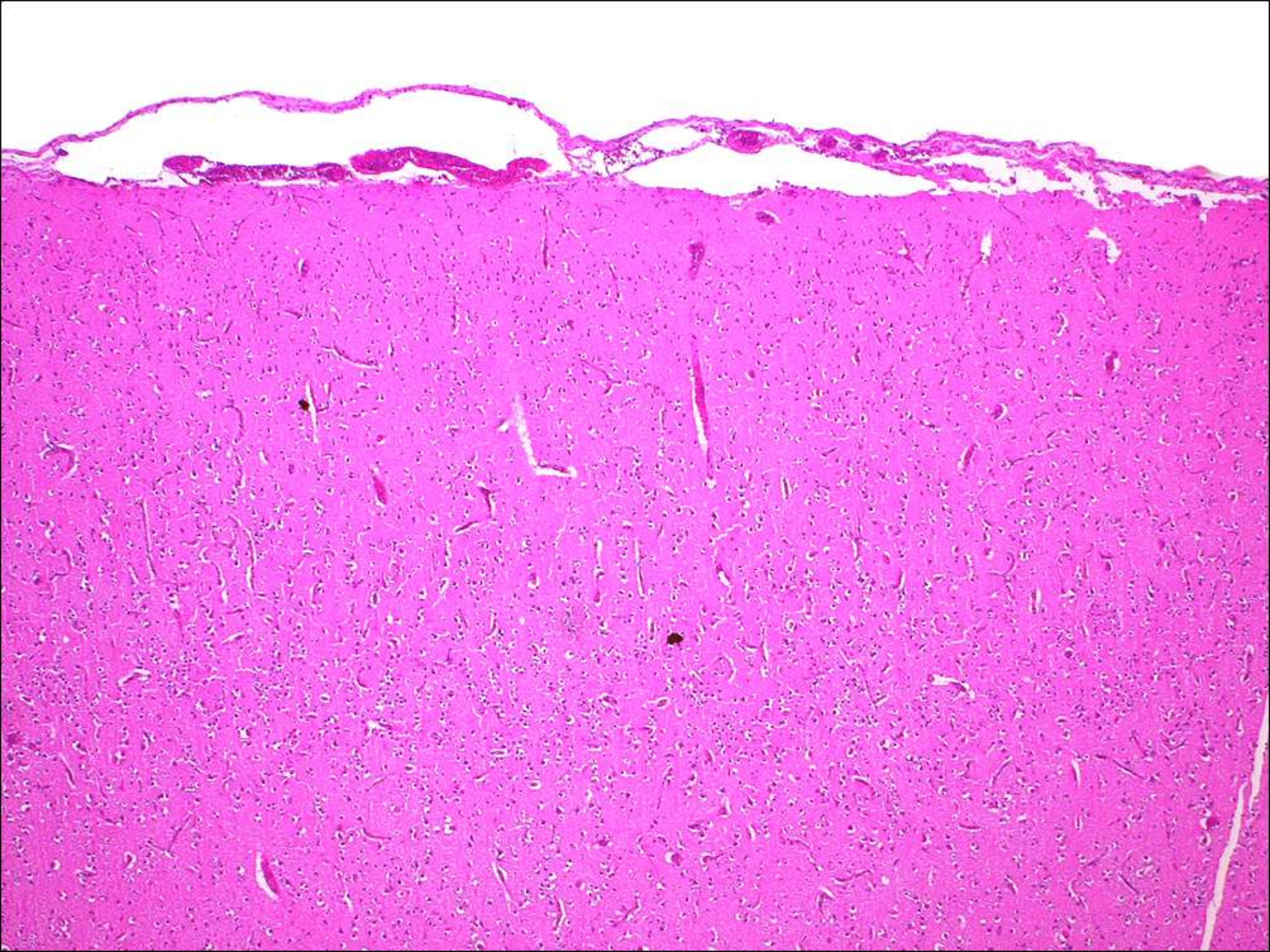
Cerebral malaria

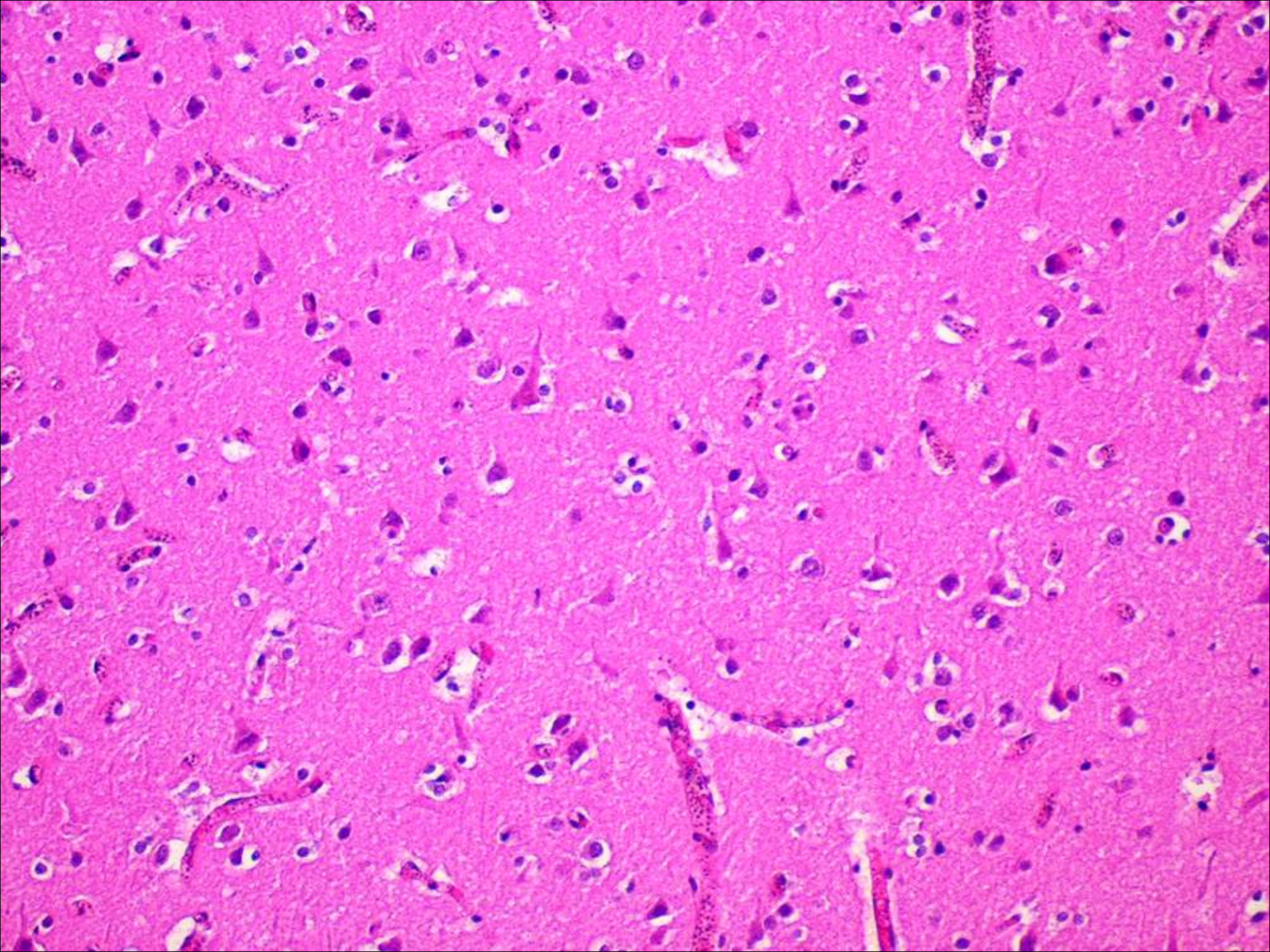
pathological features



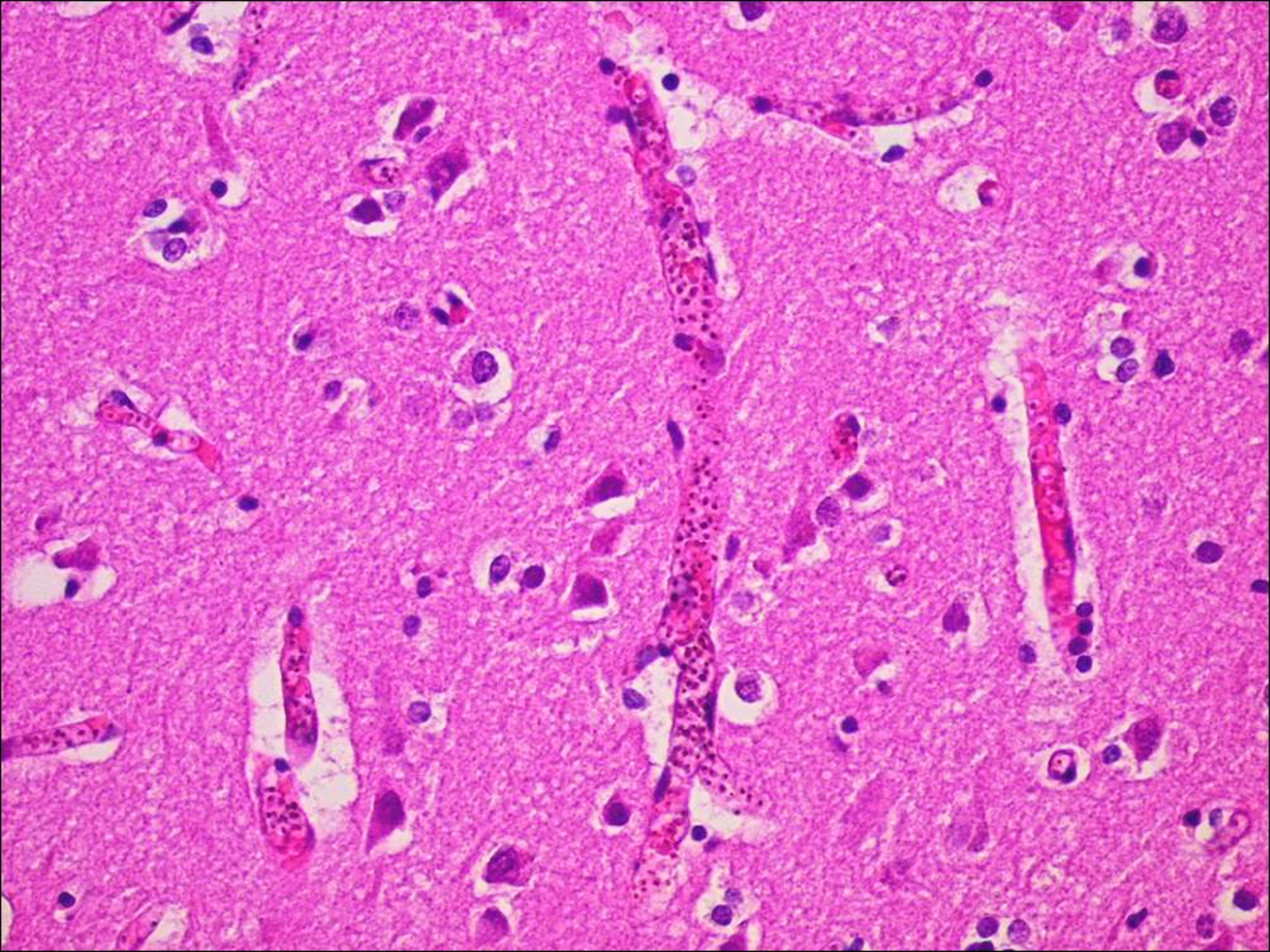
At low magnification the brain looks to be normal.

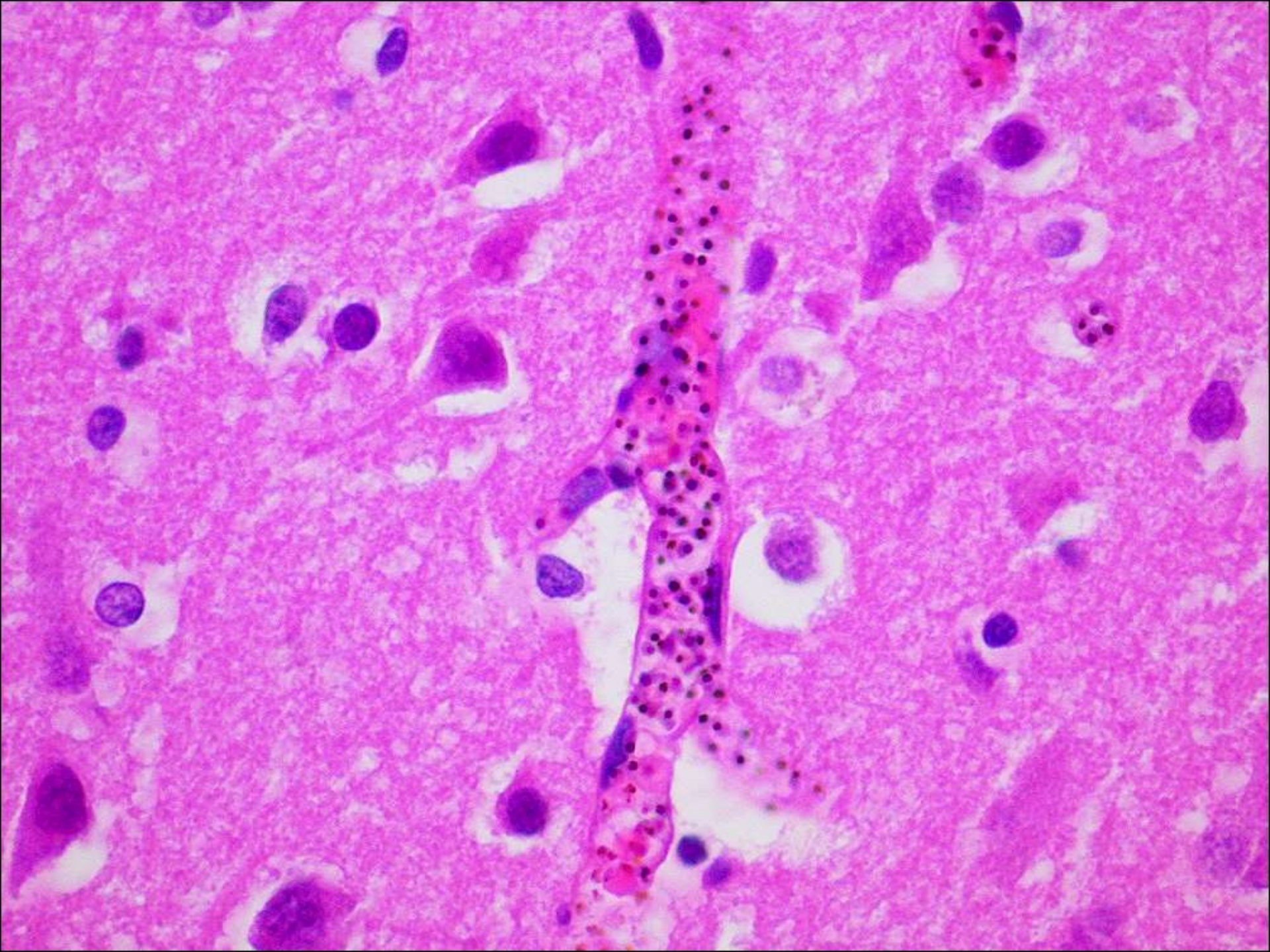


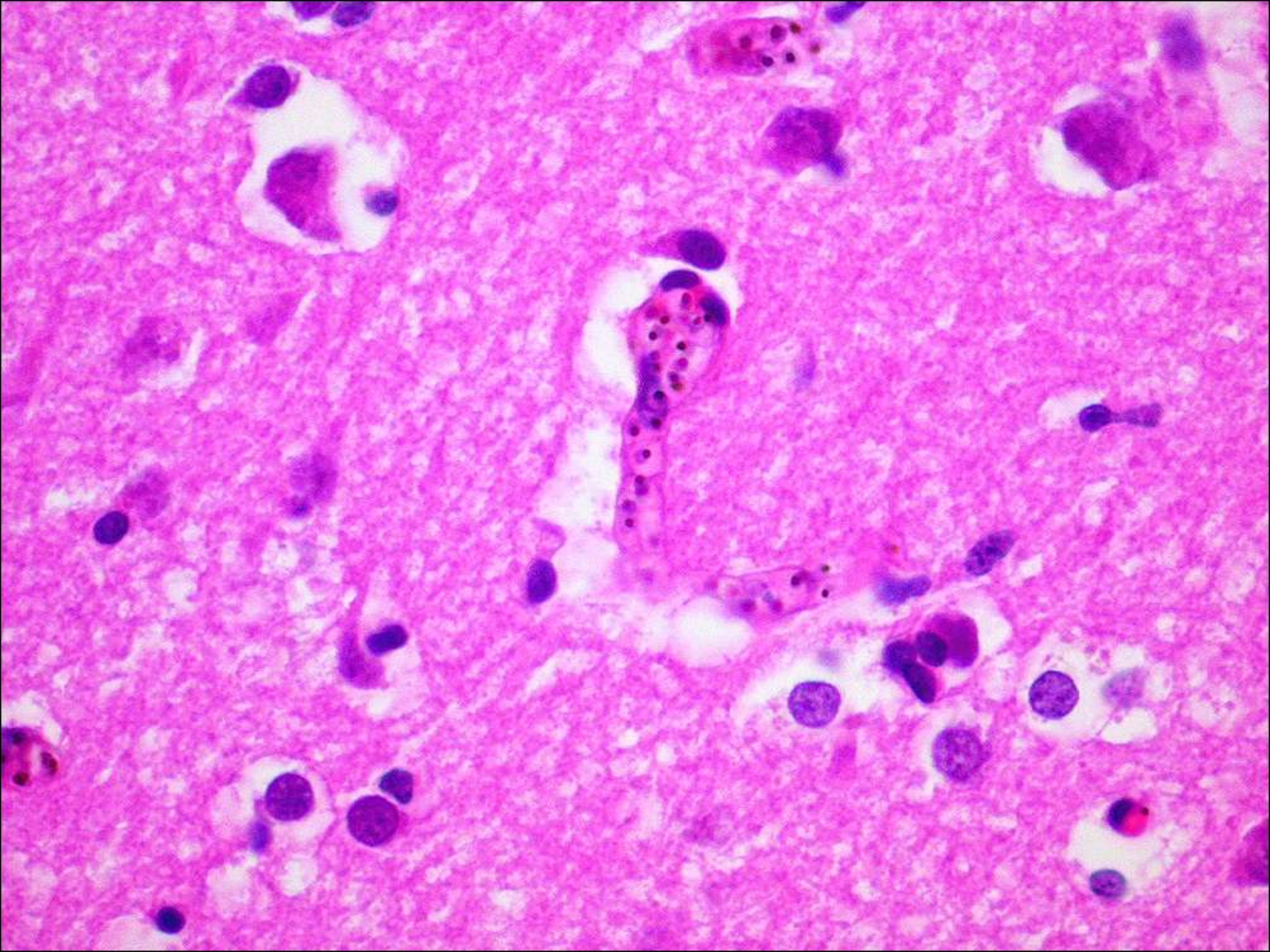




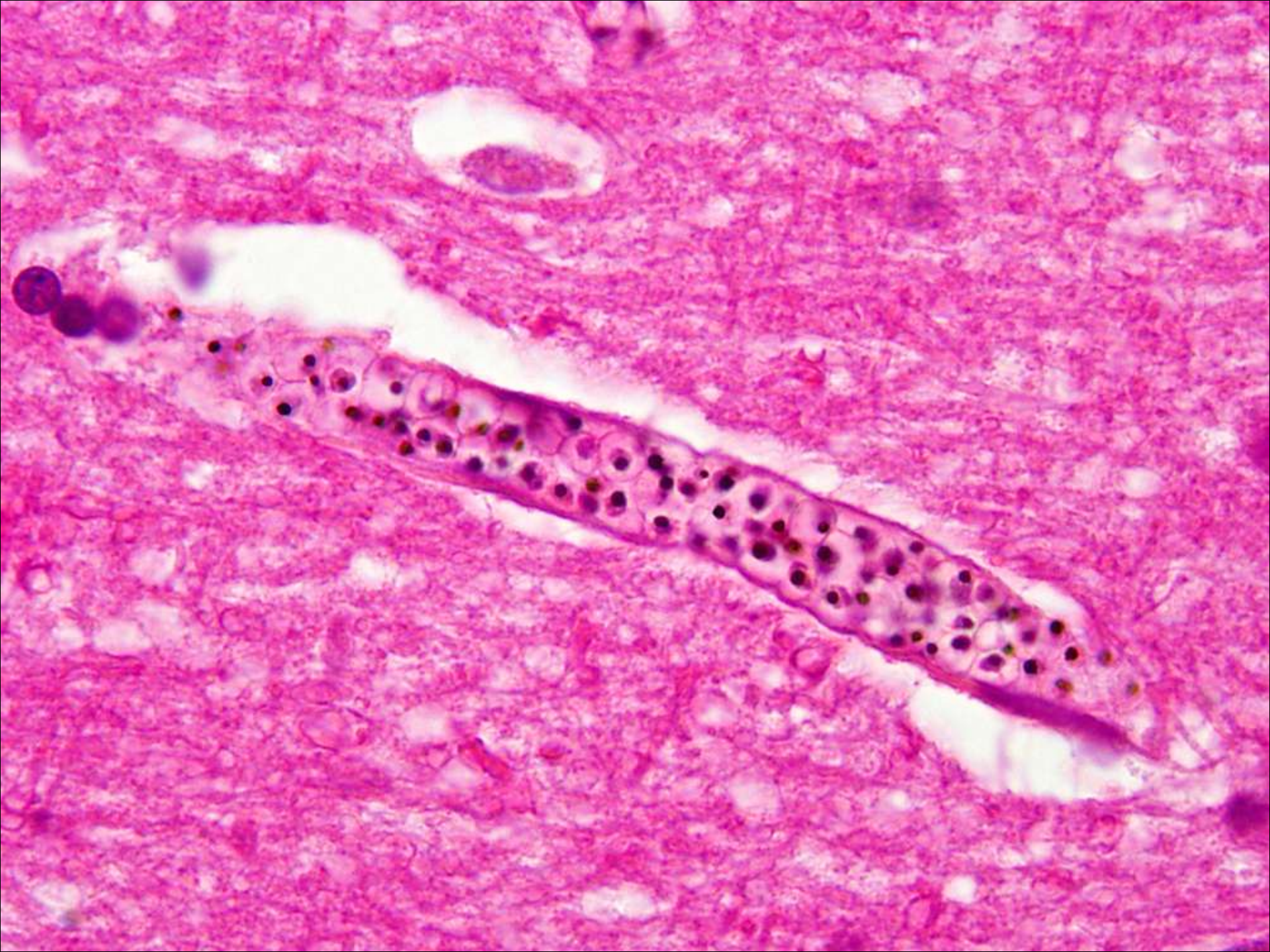
However, at higher magnification one sees a lot of pigment in the red blood cells in the cerebral capillaries.







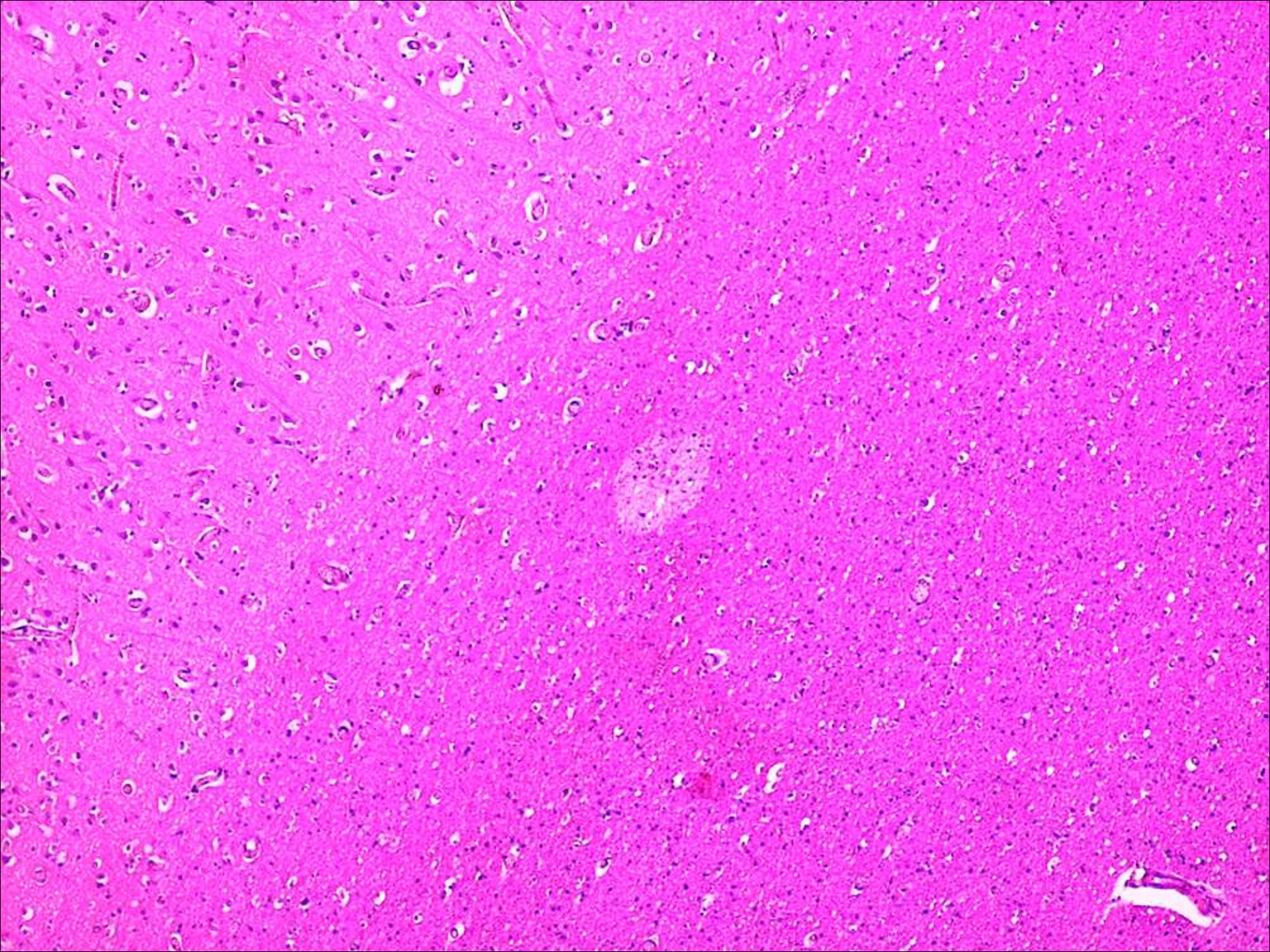
In rare cases ring forms of
P. falciparum can be seen
in the RBCs

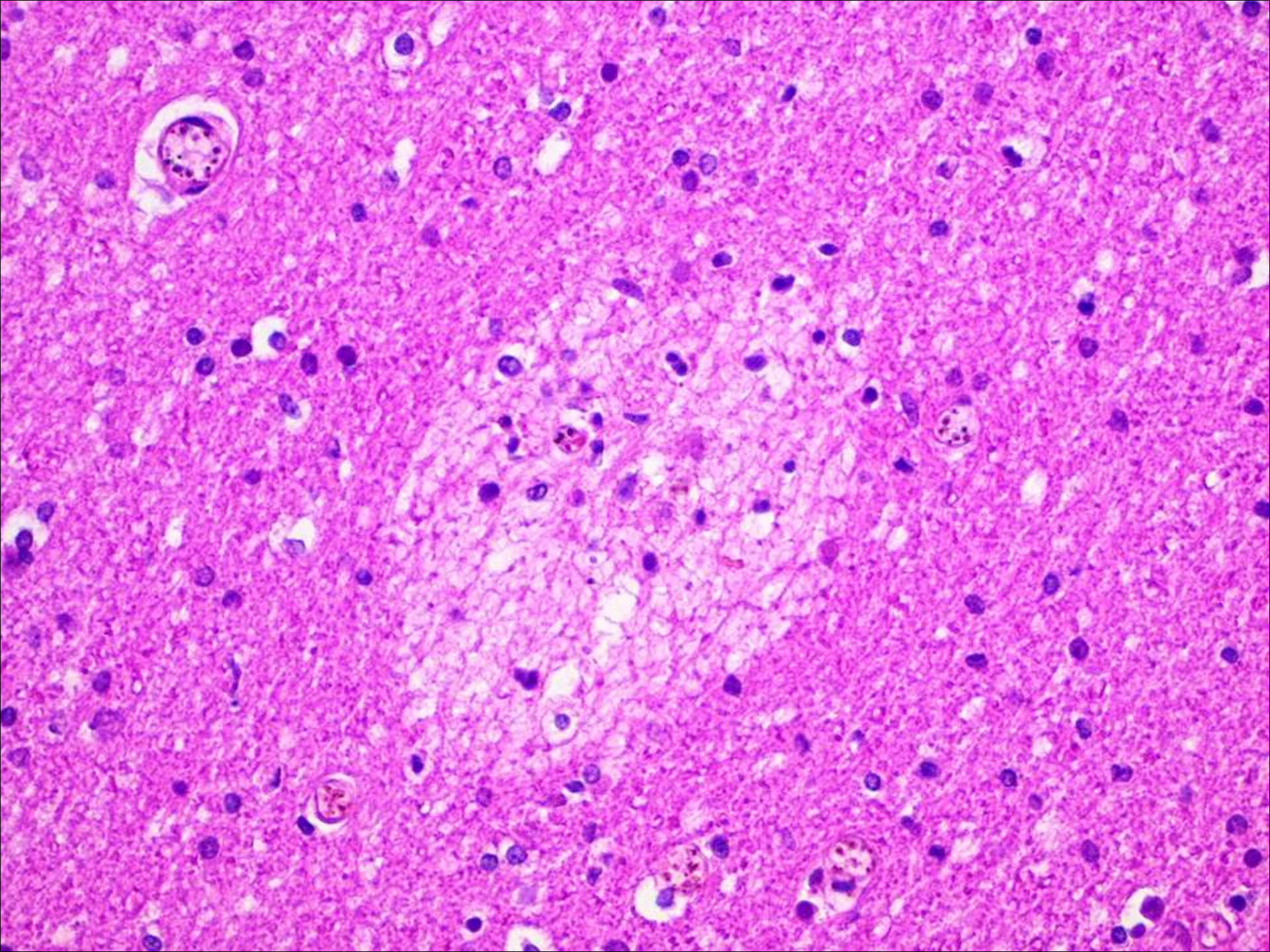


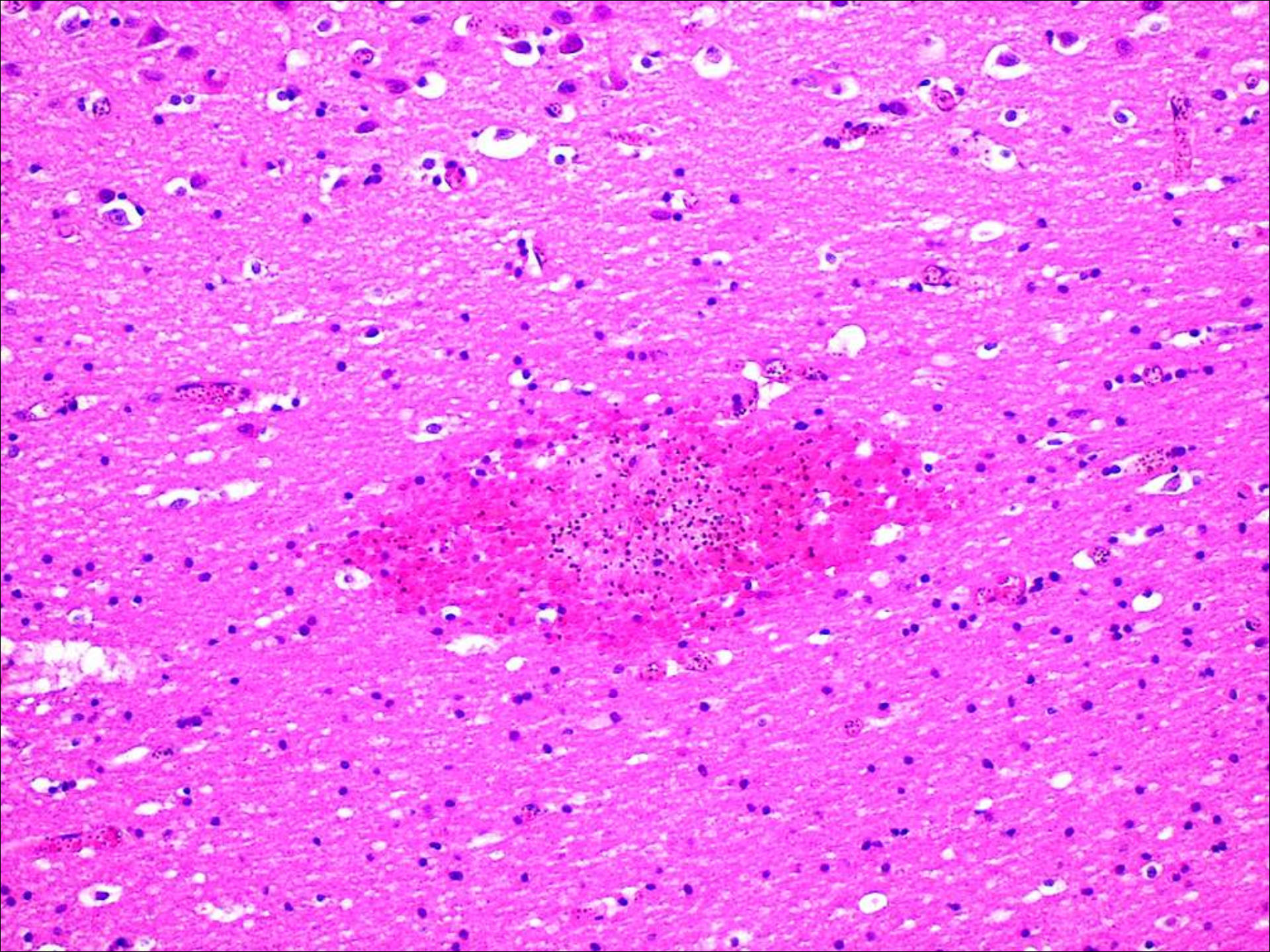
In the white matter of the brain one may see focal areas of demyelination.

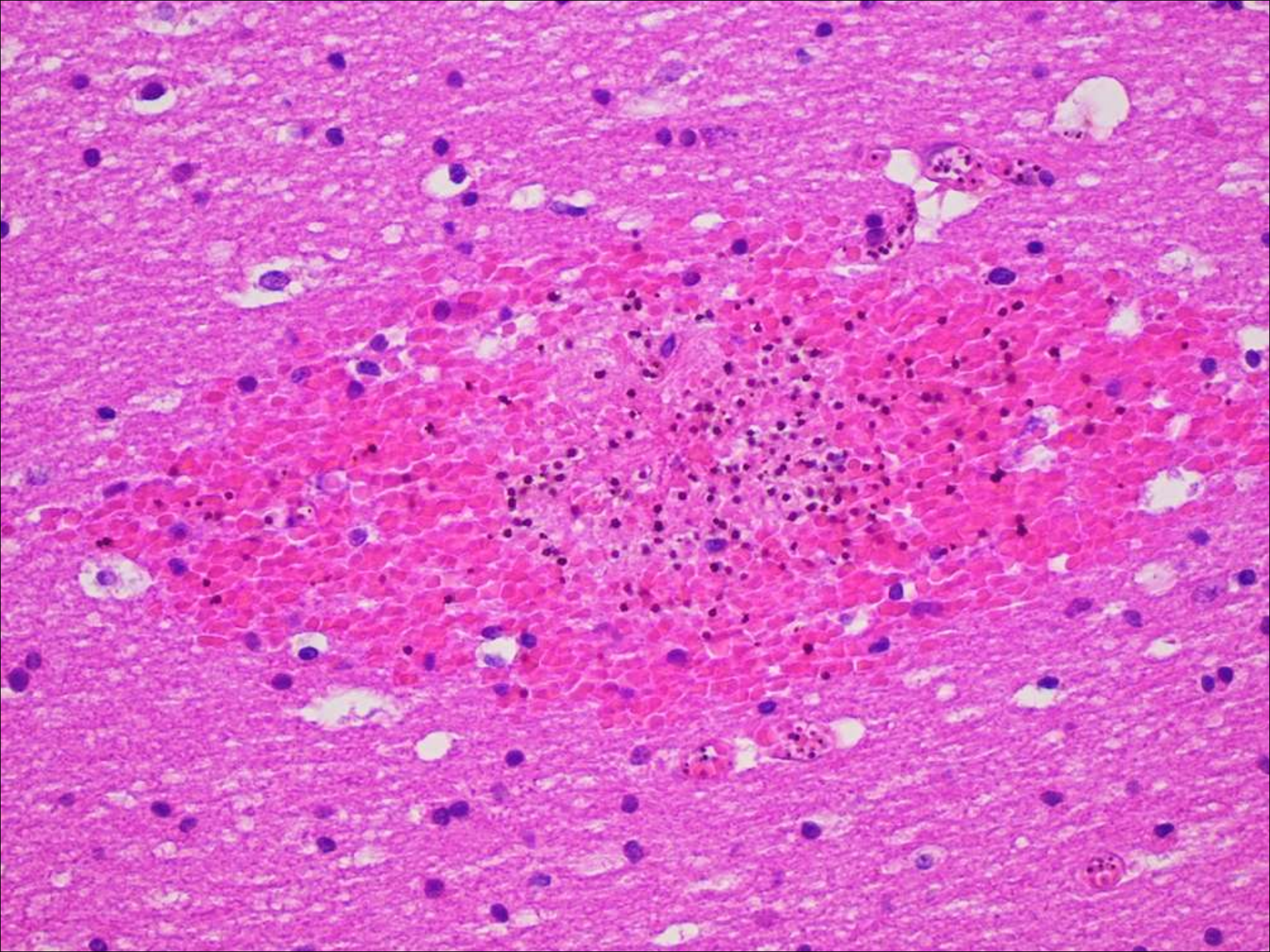
These are associated with rupture of capillaries.

This accounts for the appearance of micro haemorrhages in the white matter.



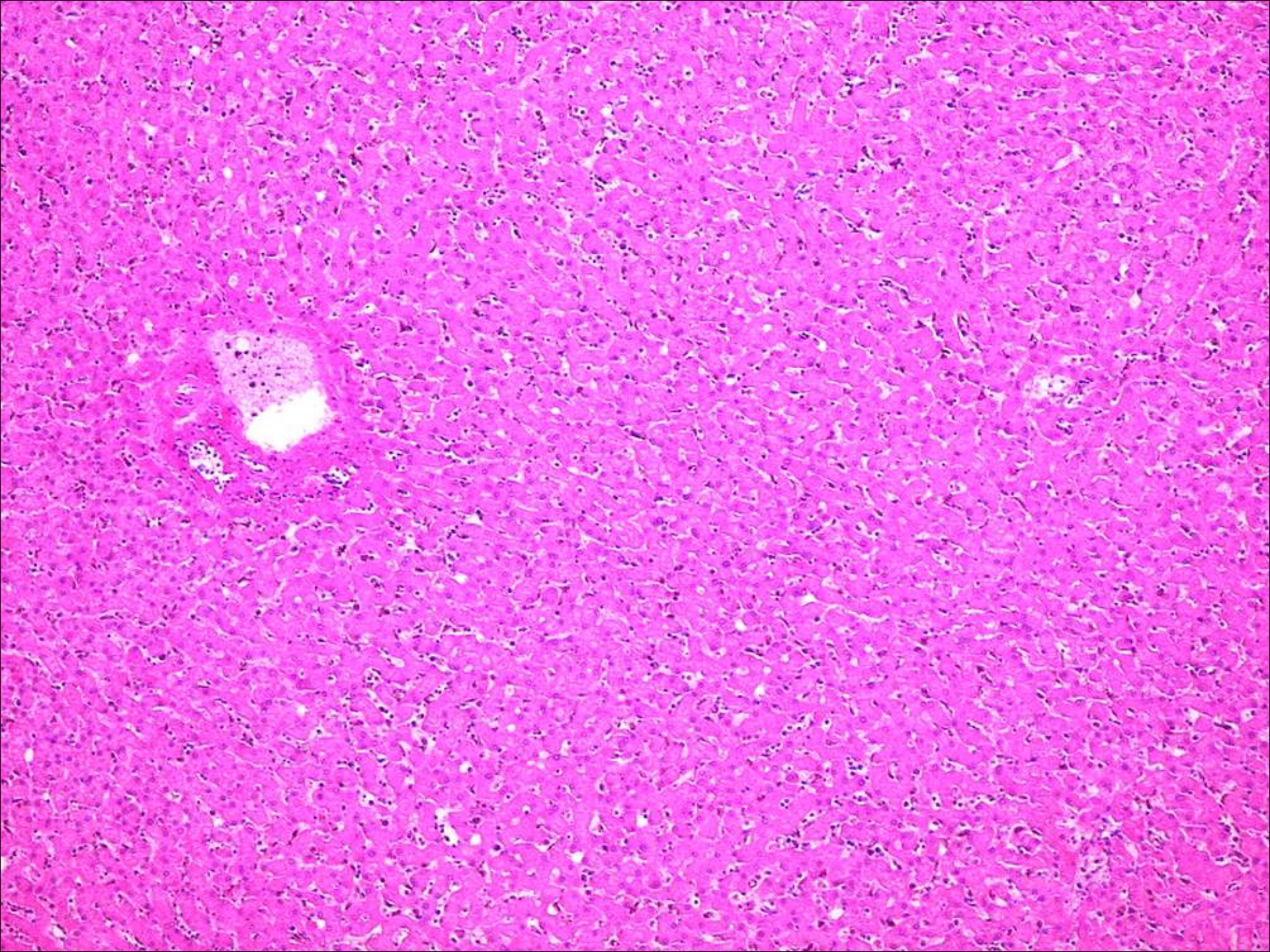

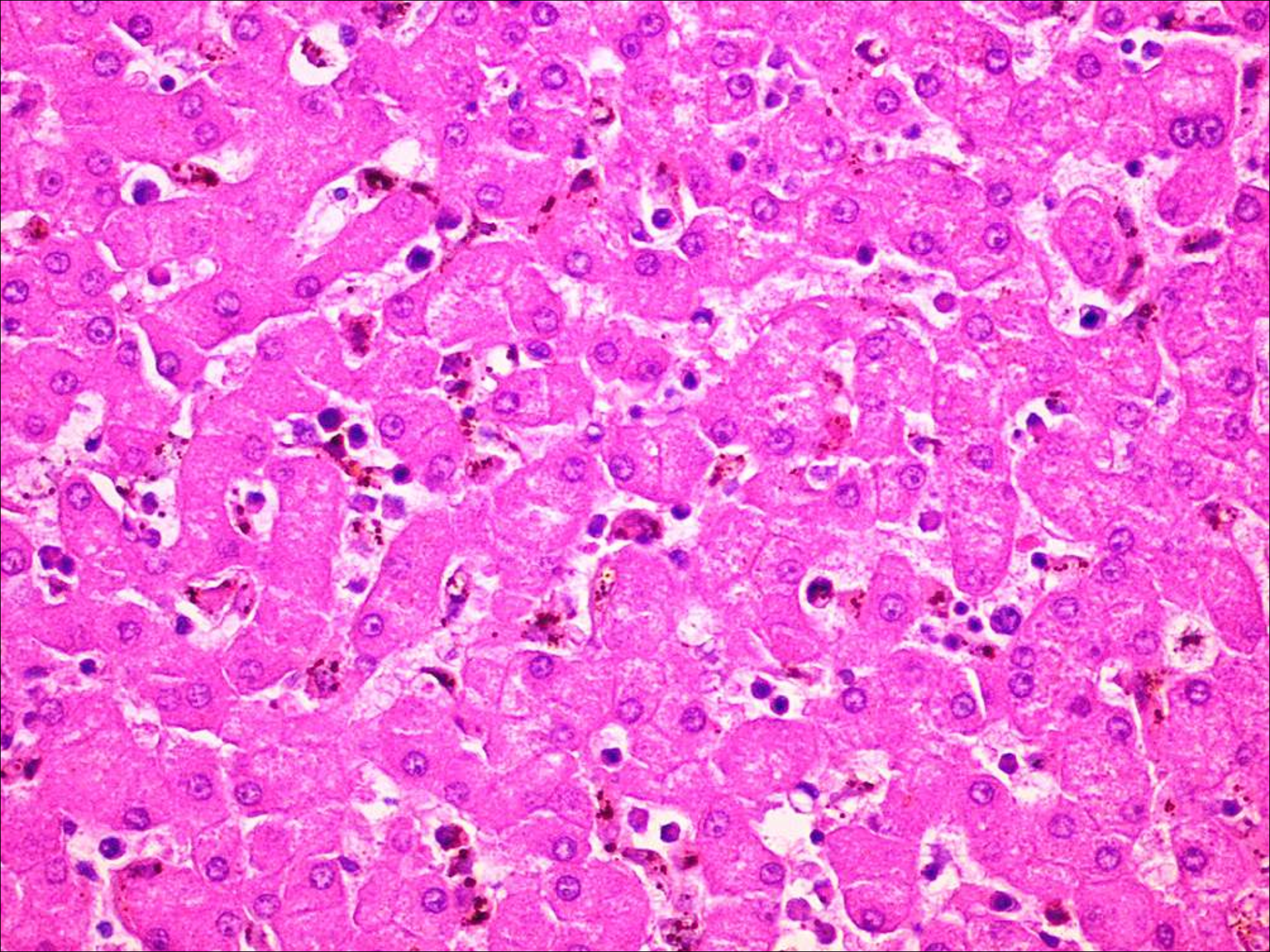


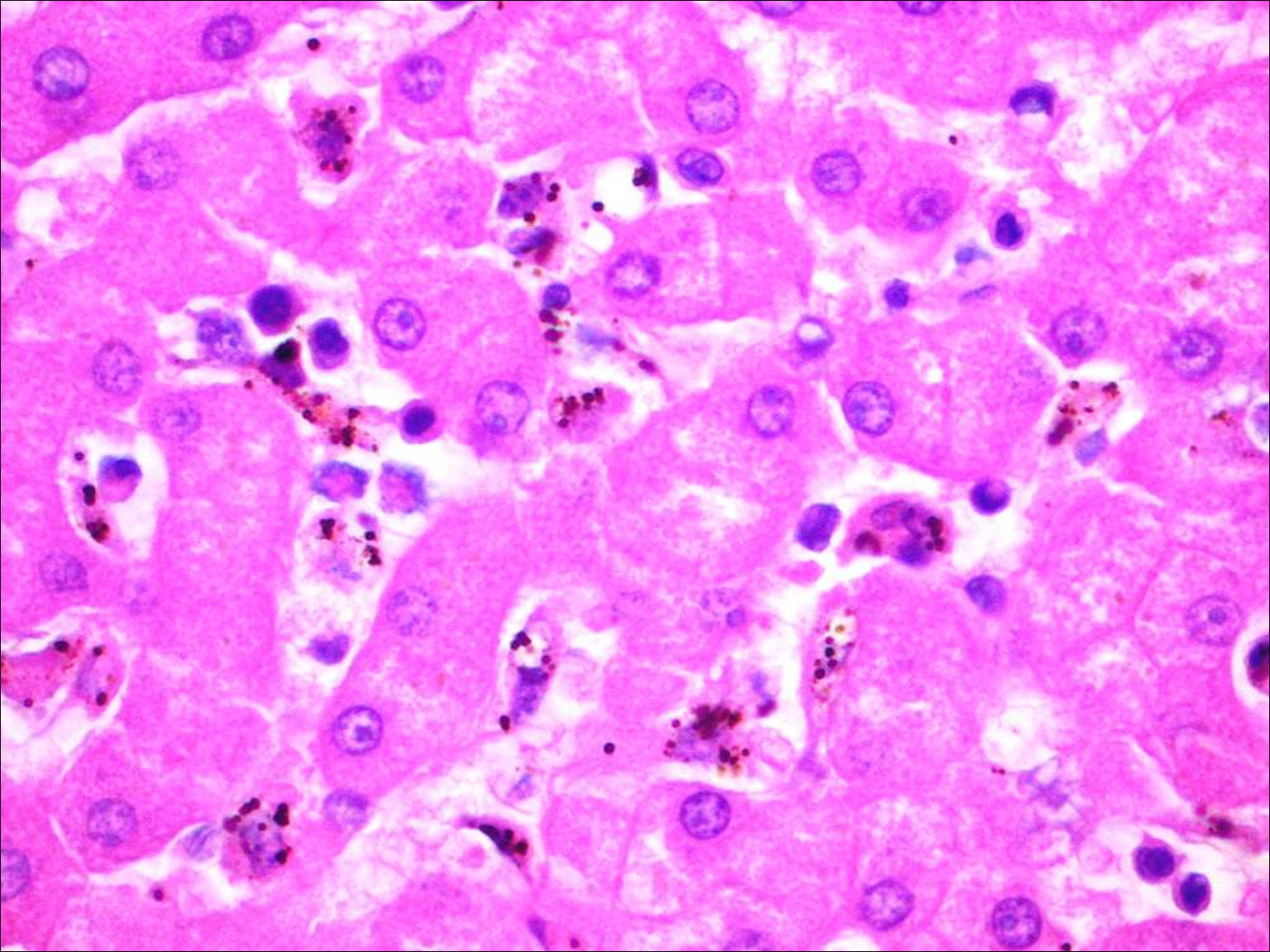


The other organs appear to be microscopically normal except for the presence of malaria pigment in the capillaries.

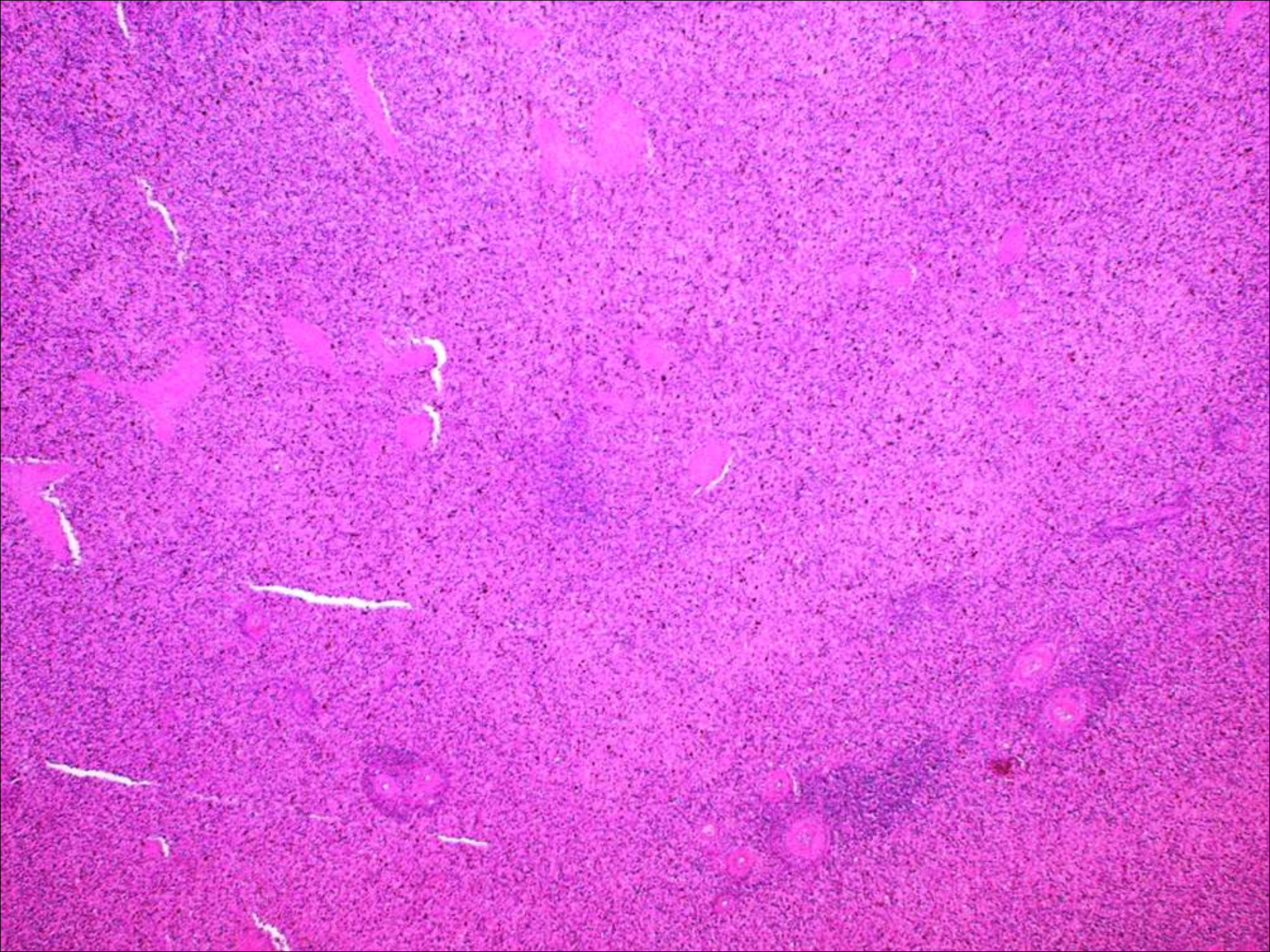


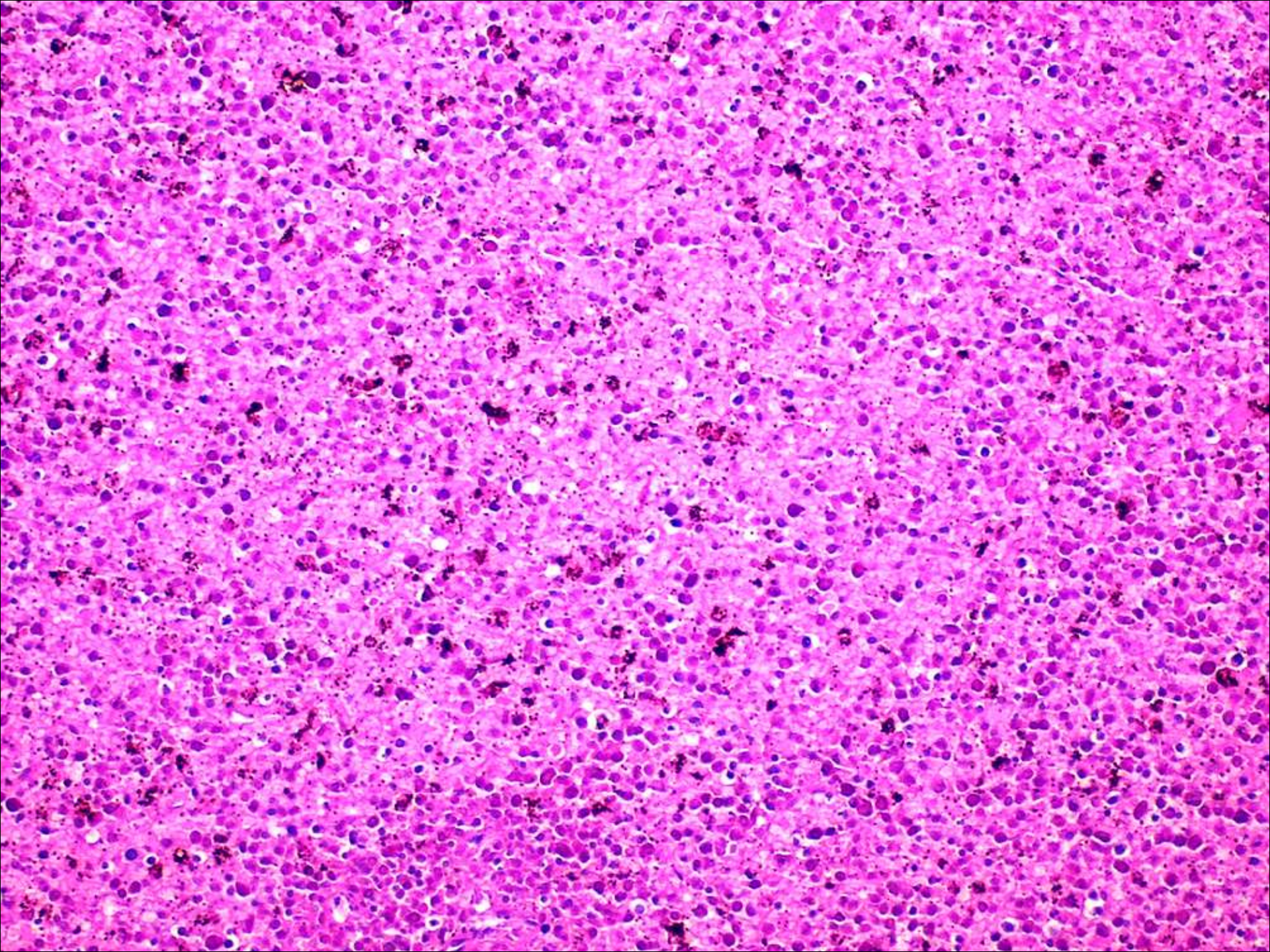


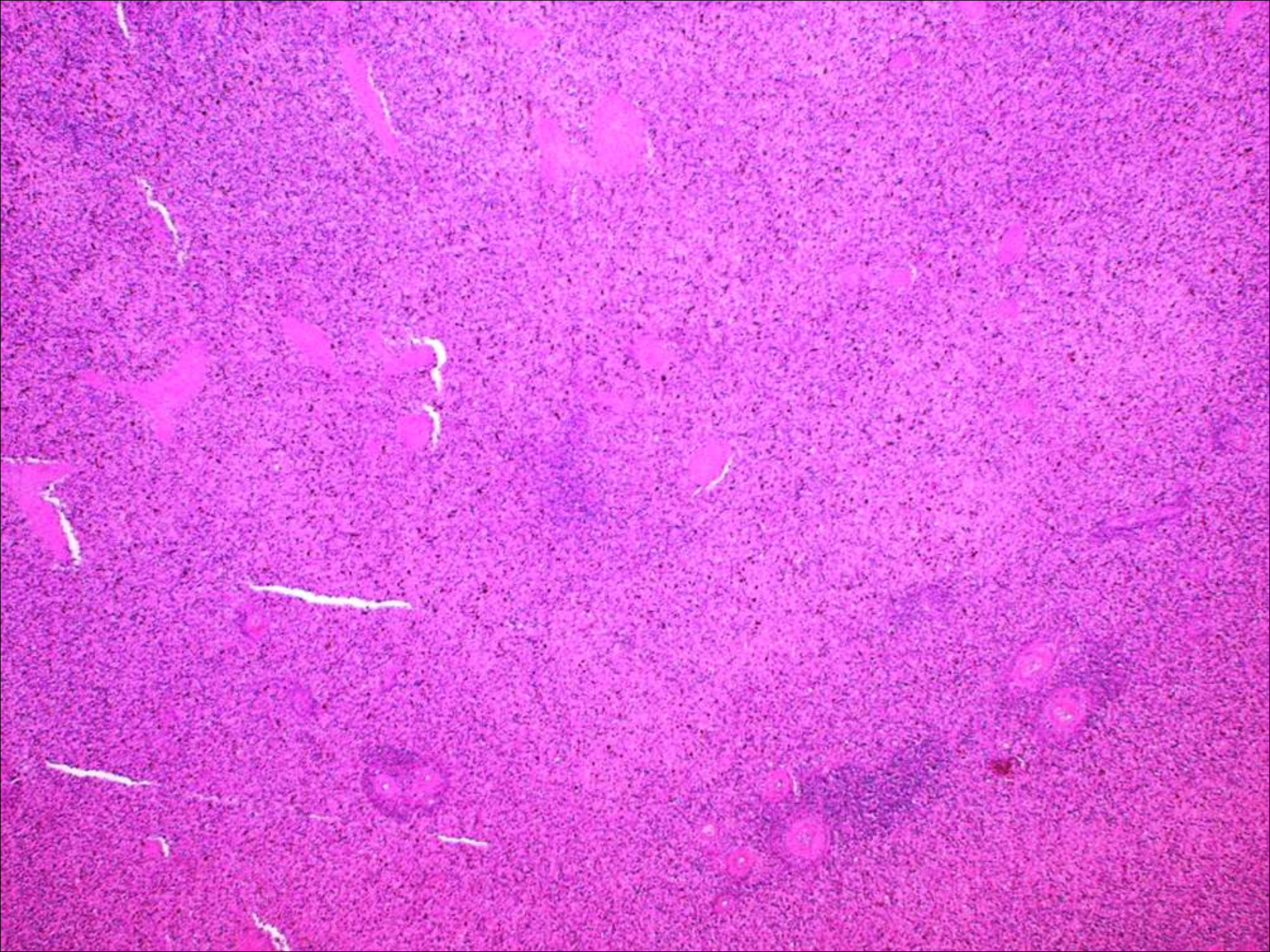


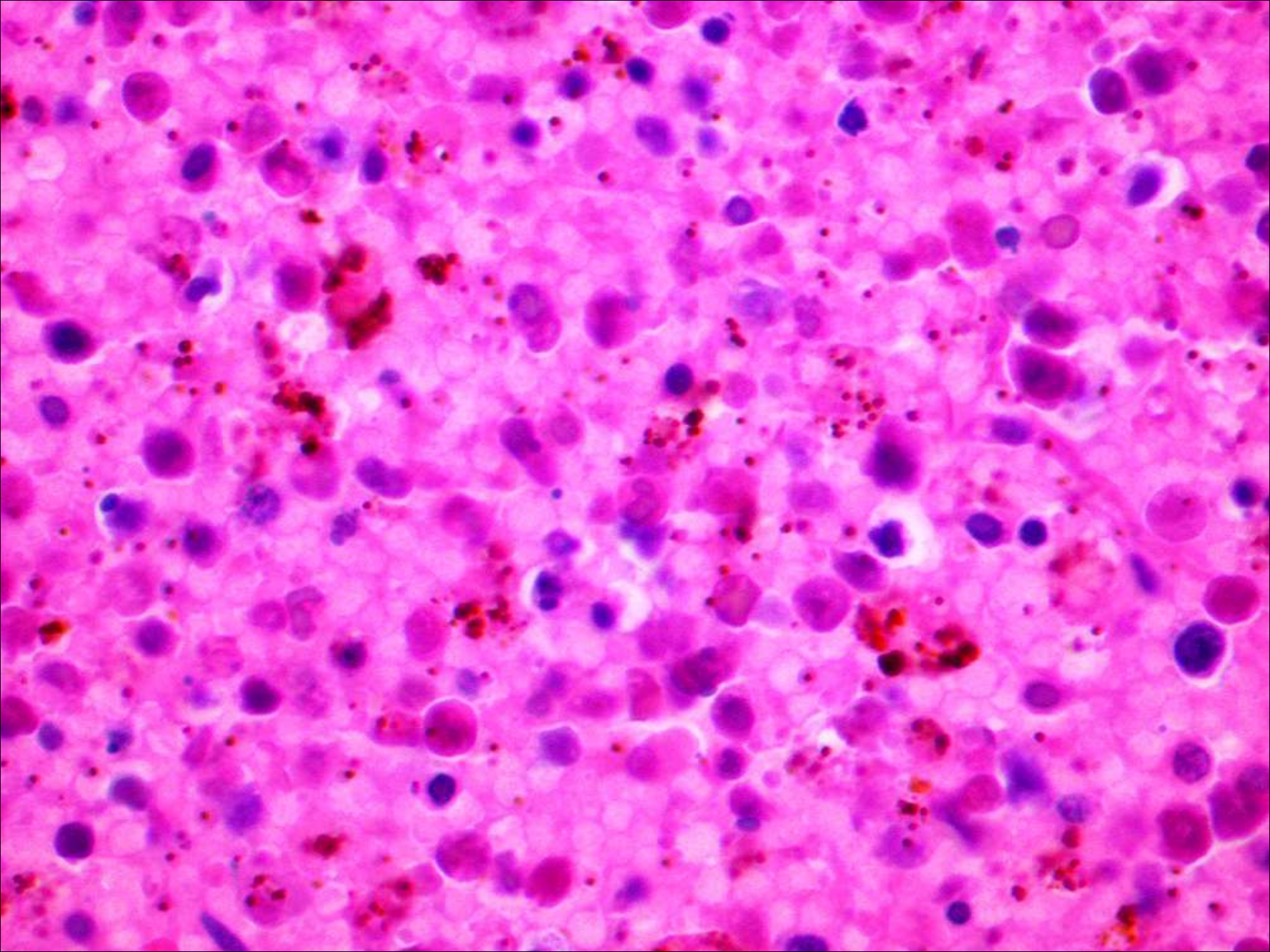


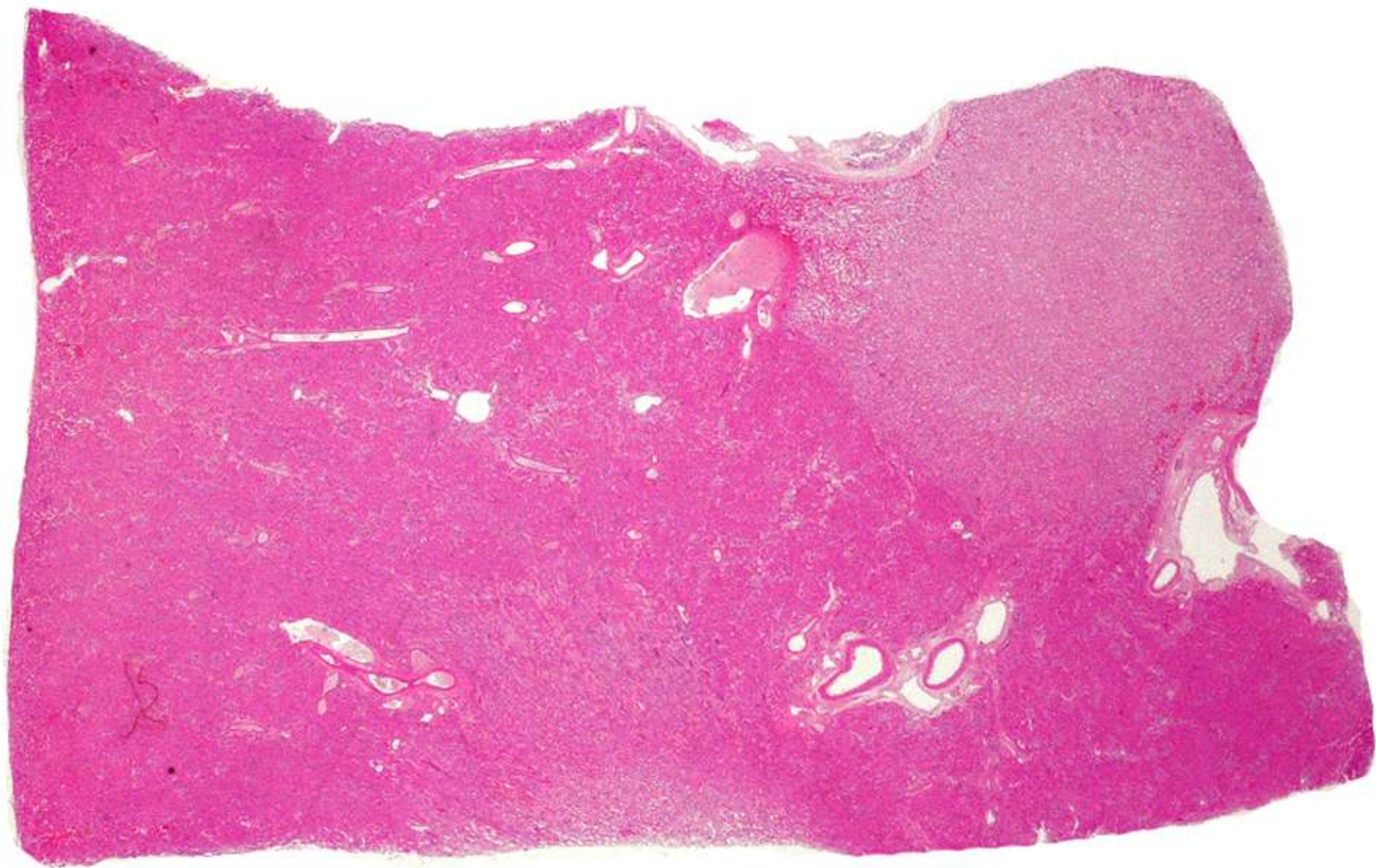


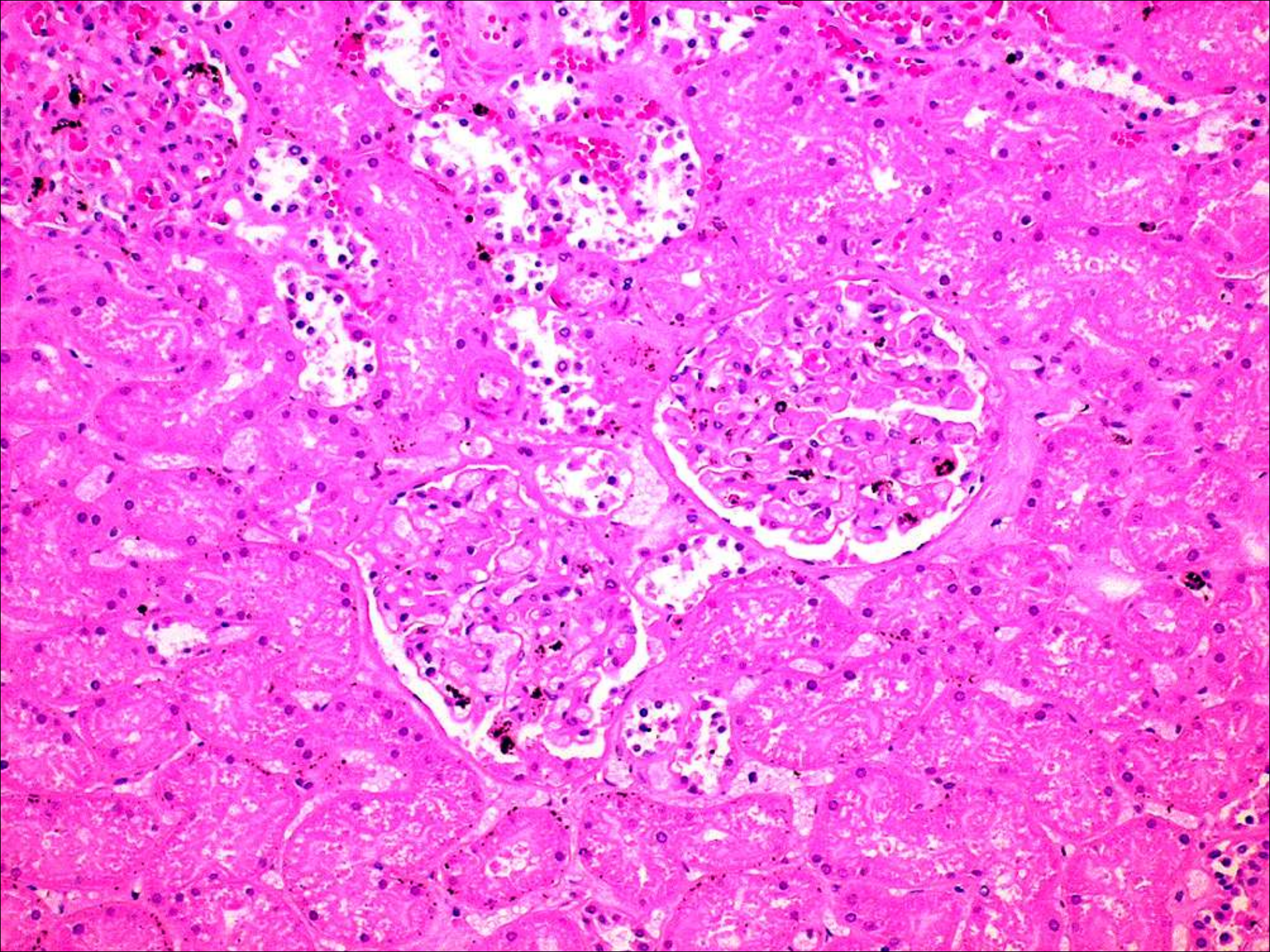


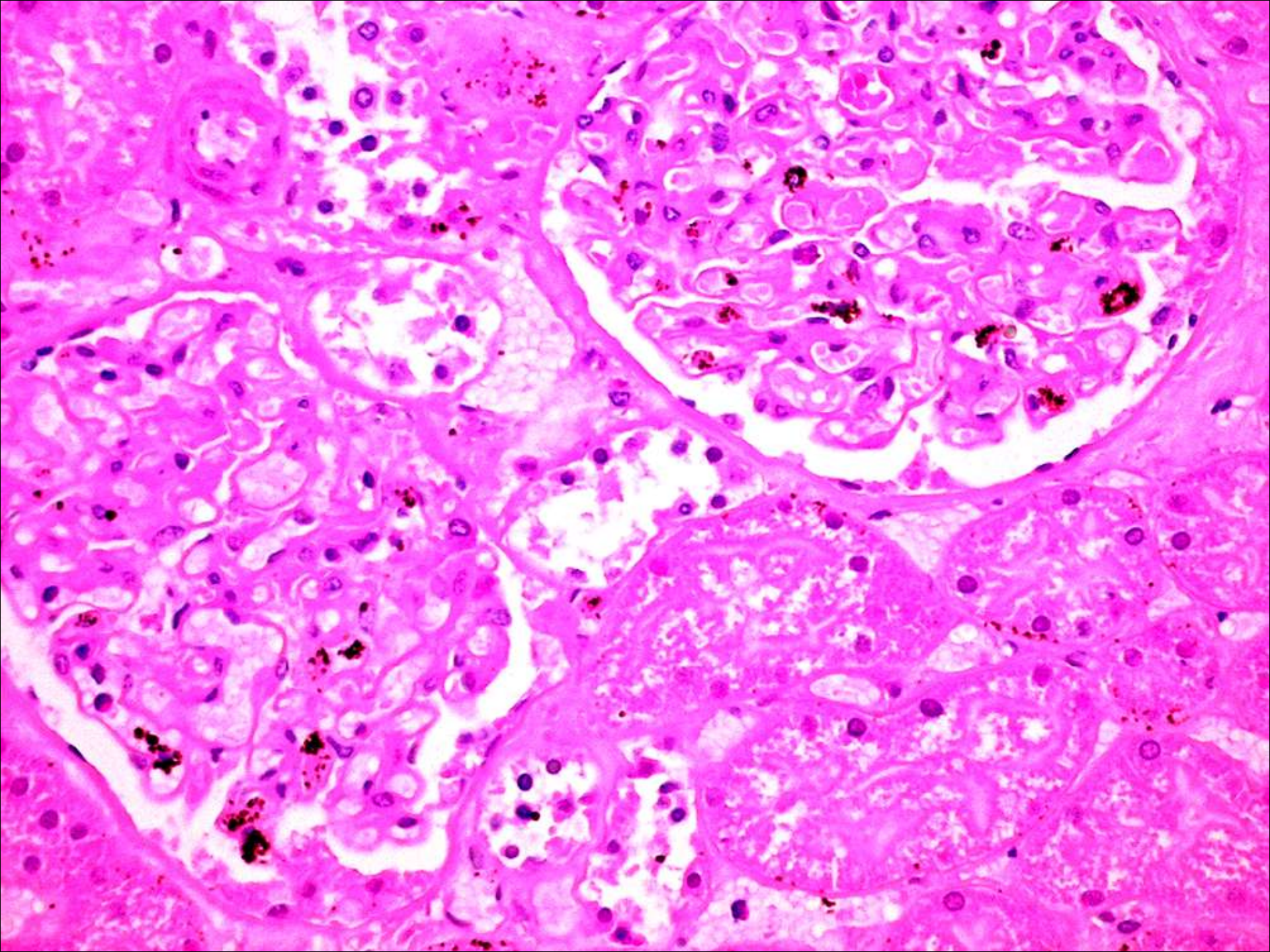


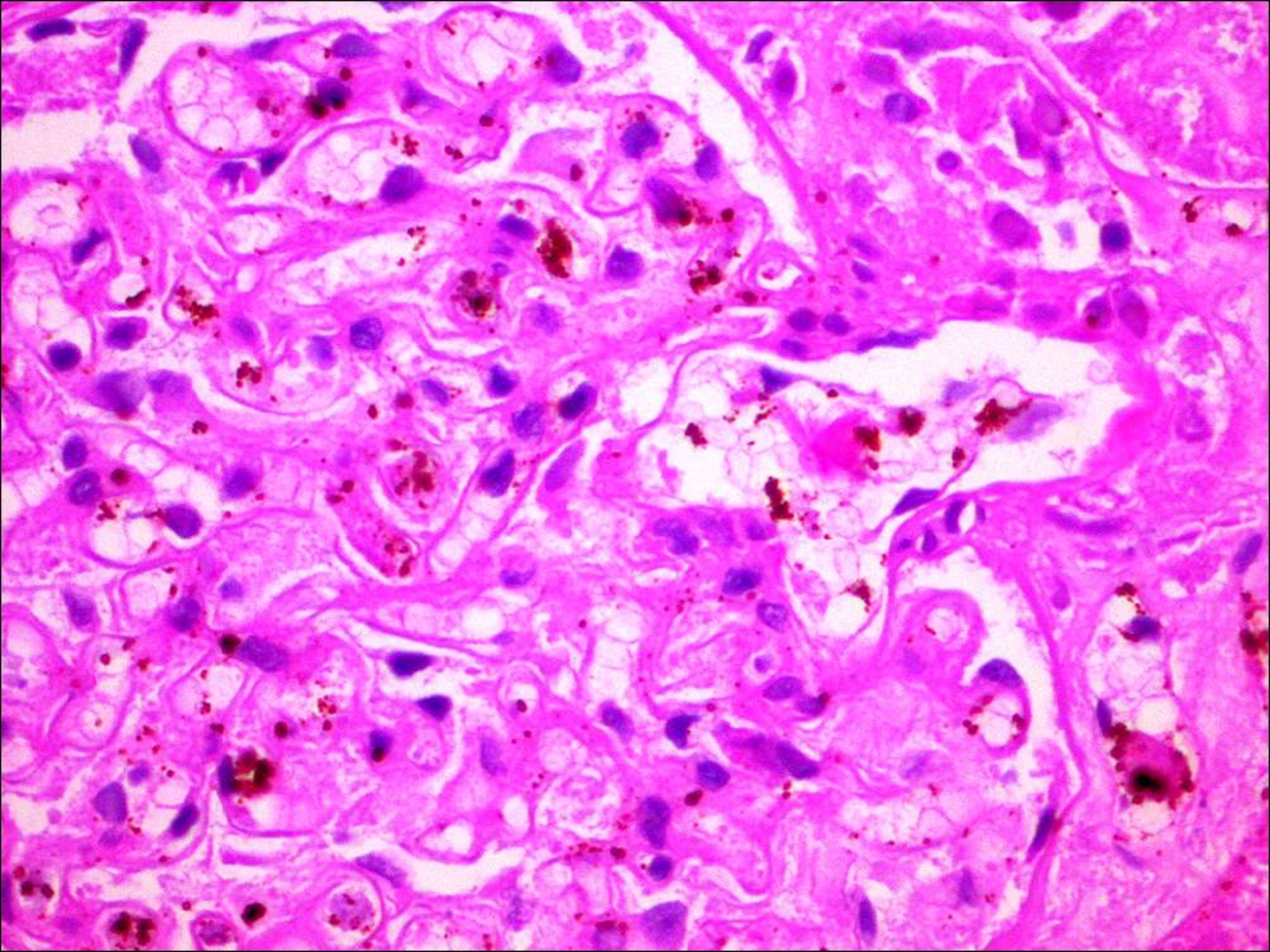


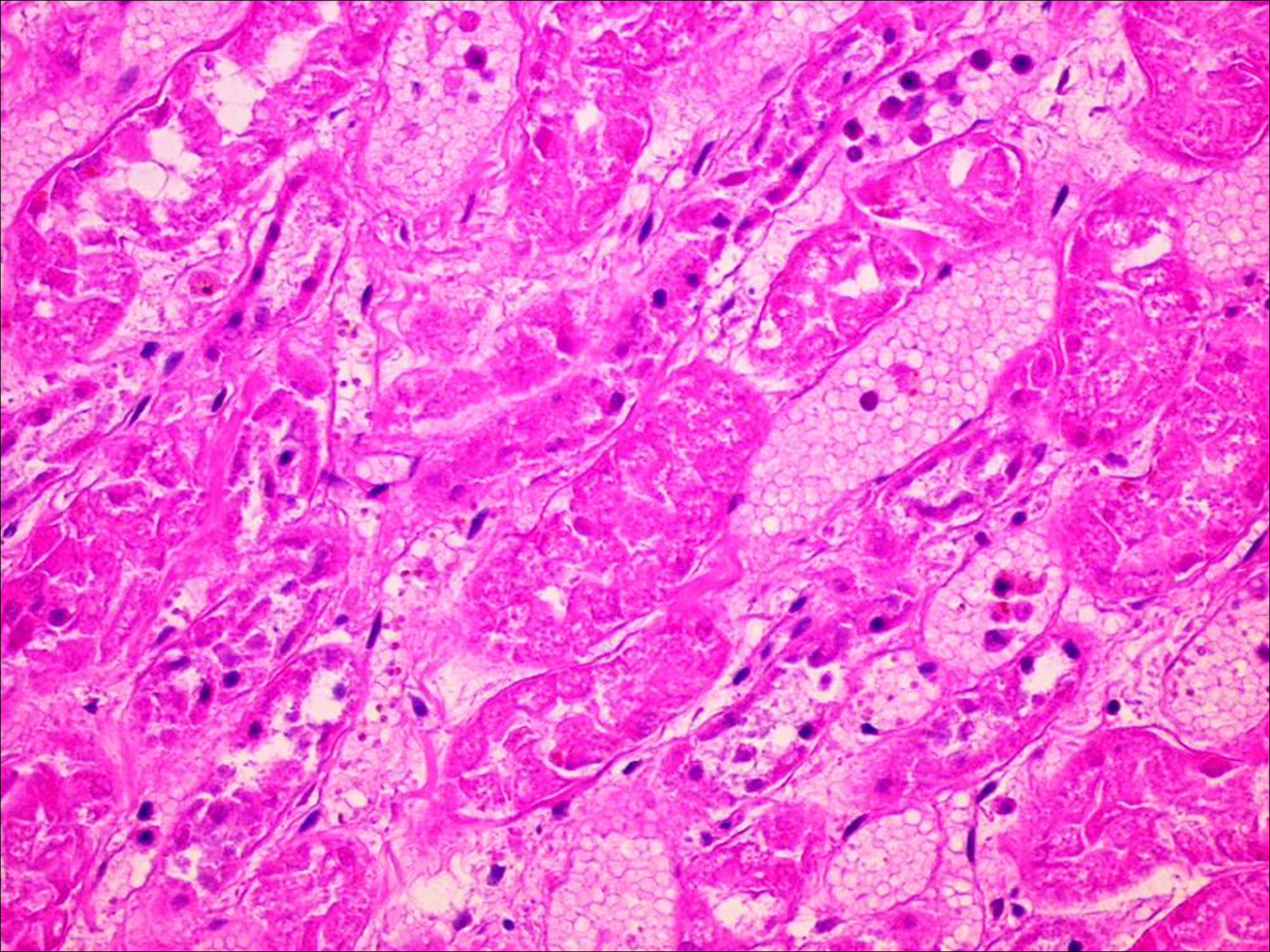


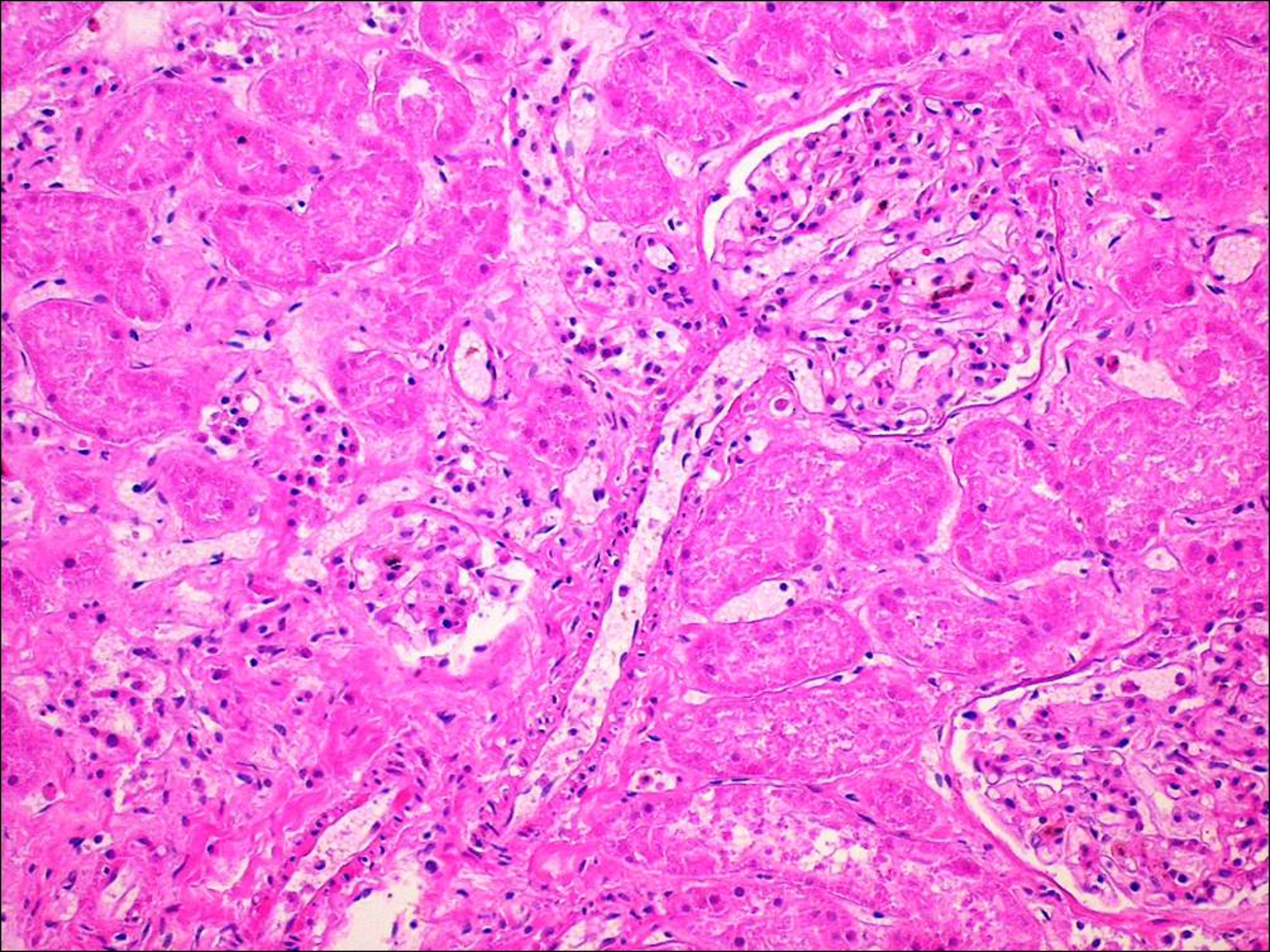










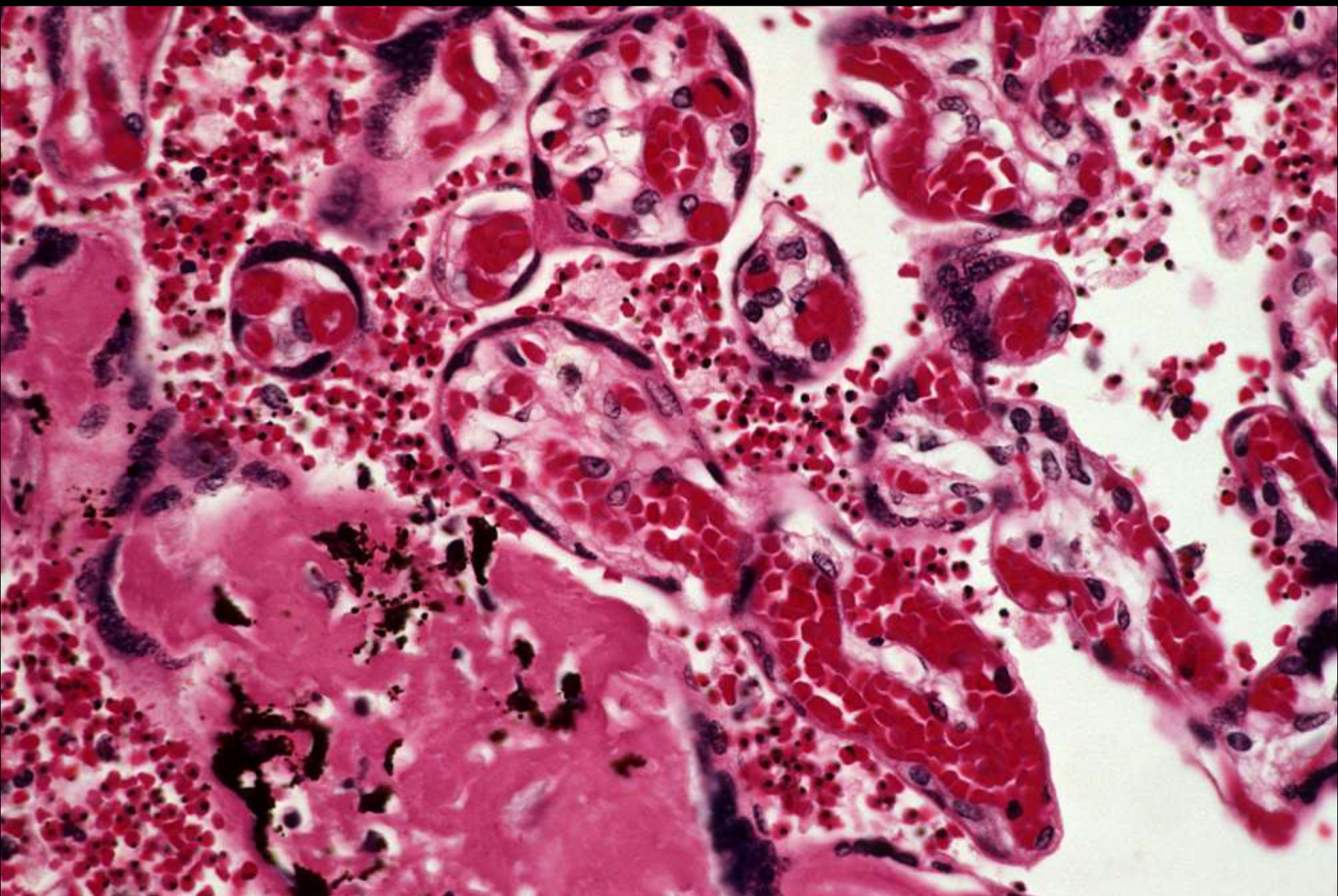


Malaria in Pregnancy

May cause abortion or premature labour

P. vivax may cross the placenta

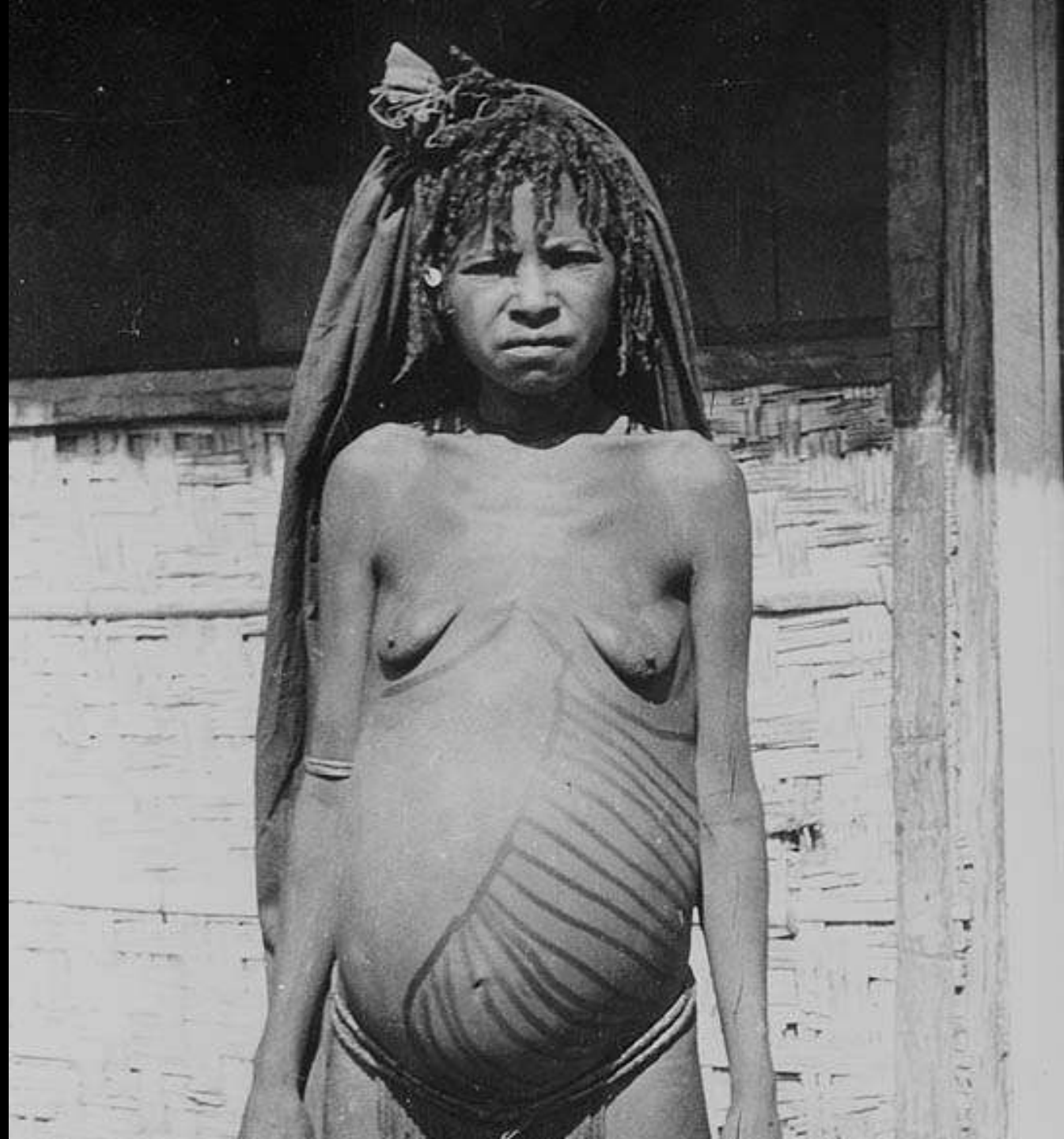
Pigment in the maternal RBCs



Chronic malaria causes gross splenomegaly

The spleen is liable to rupture

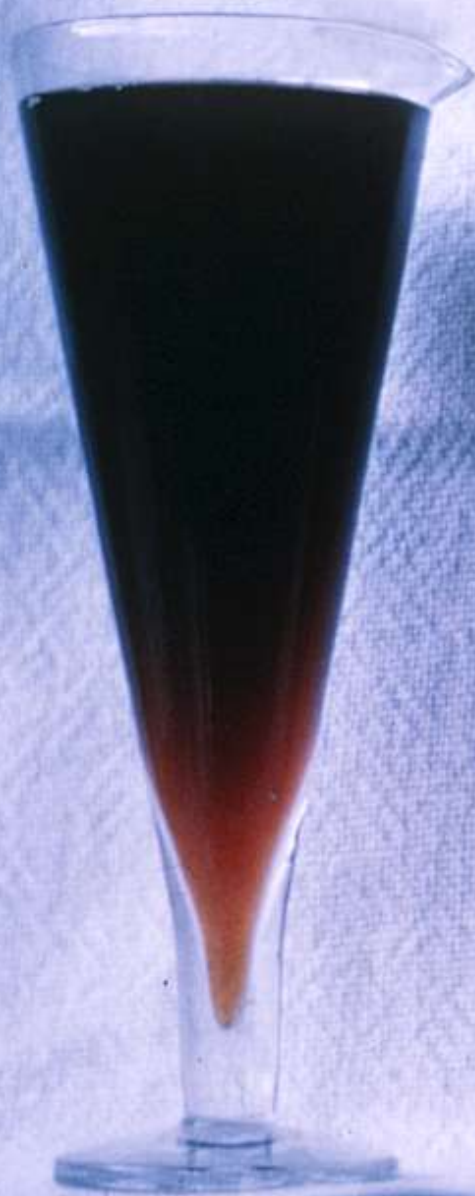
Tropical splenomegaly with suppression of the bone marrow







Blackwater fever and renal failure

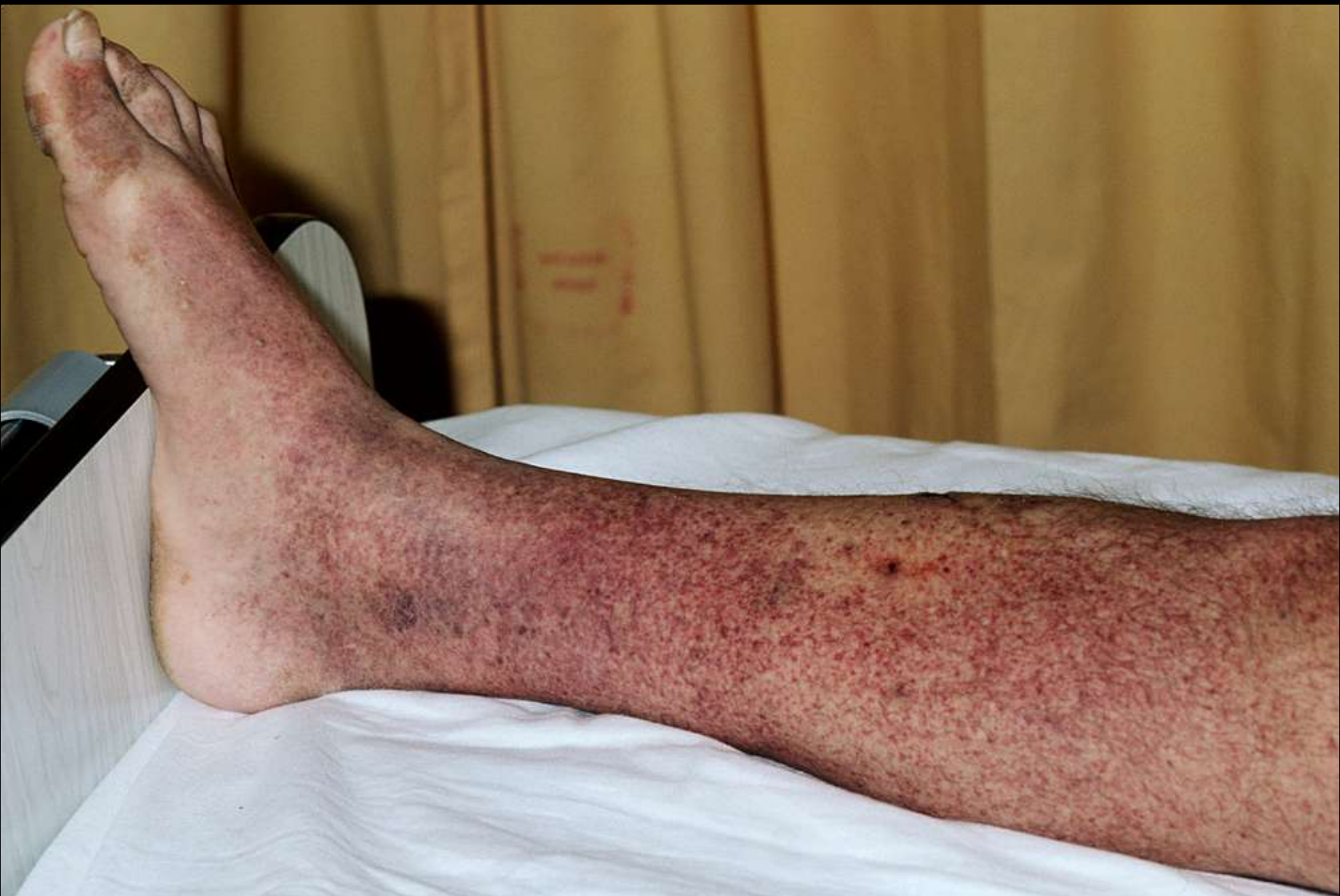



Normal
plasma

Blackwater
fever
plasma

Bleeding from platelet suppression



Hydatid cyst

A 59 year old woman presented in Aug 2008 complaining of headache and dizziness for about 4 weeks.

Past history: 25 years ago she had a hydatid cyst removed from the liver.

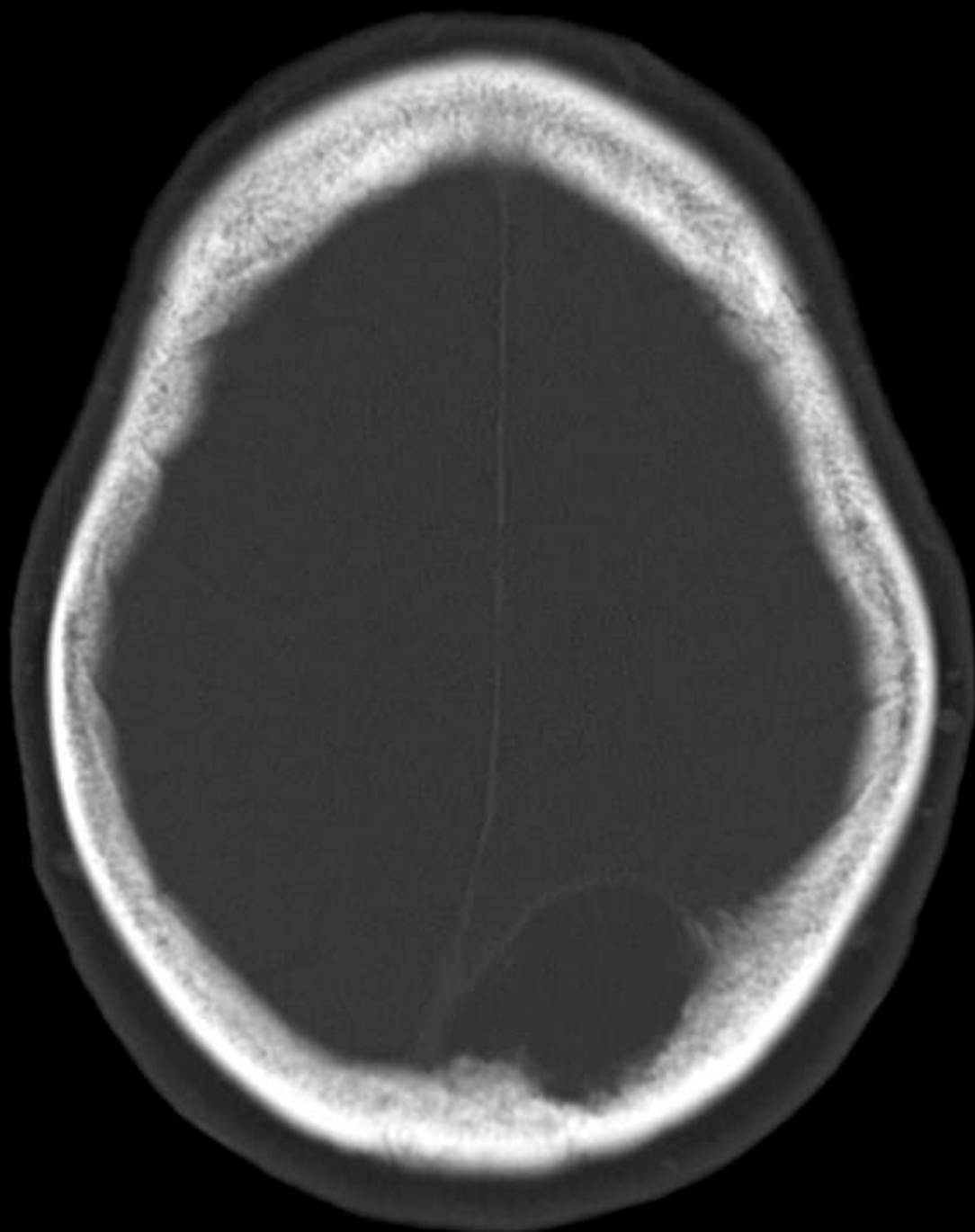
A hydatid cyst was also present in the lung.

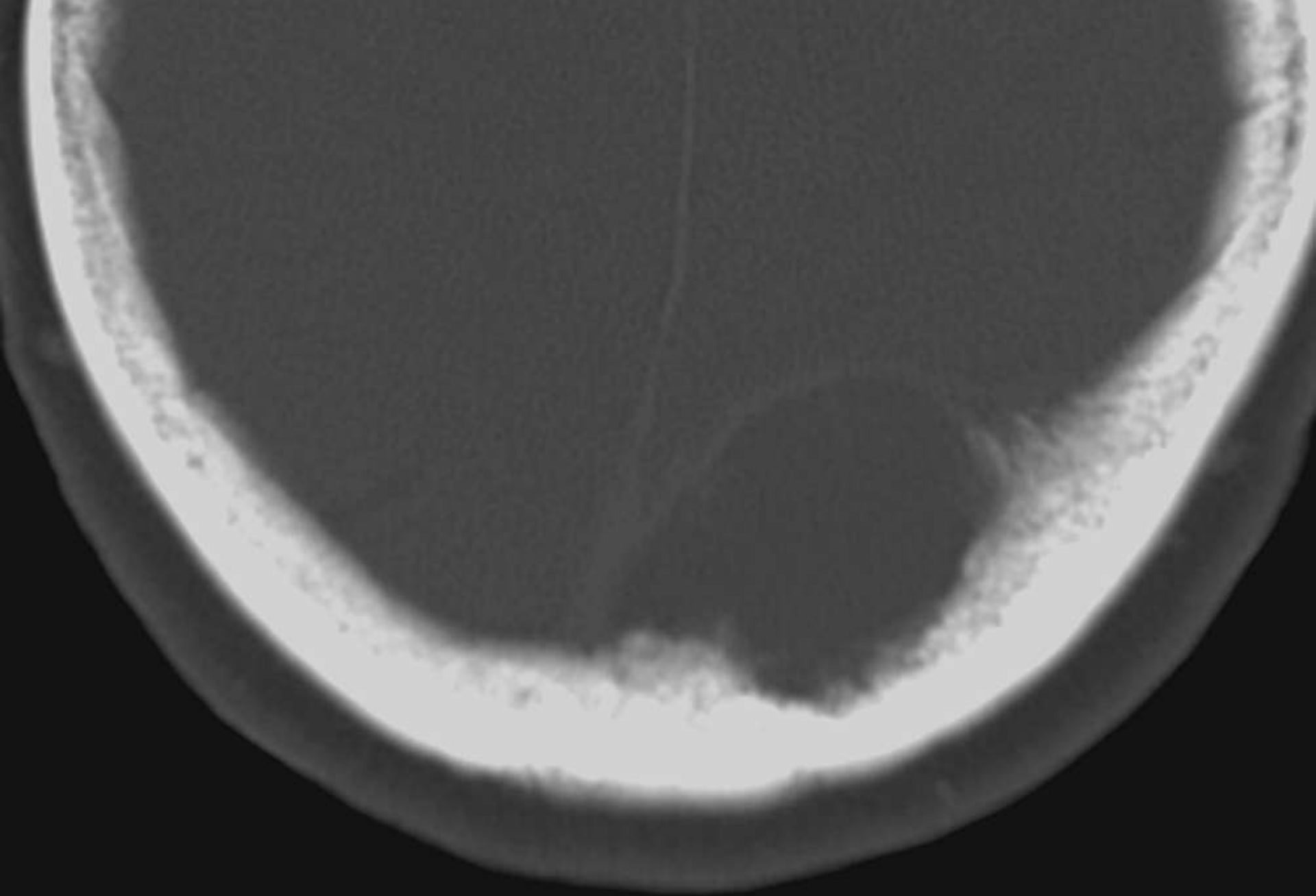
This ruptured spontaneously via the bronchi.

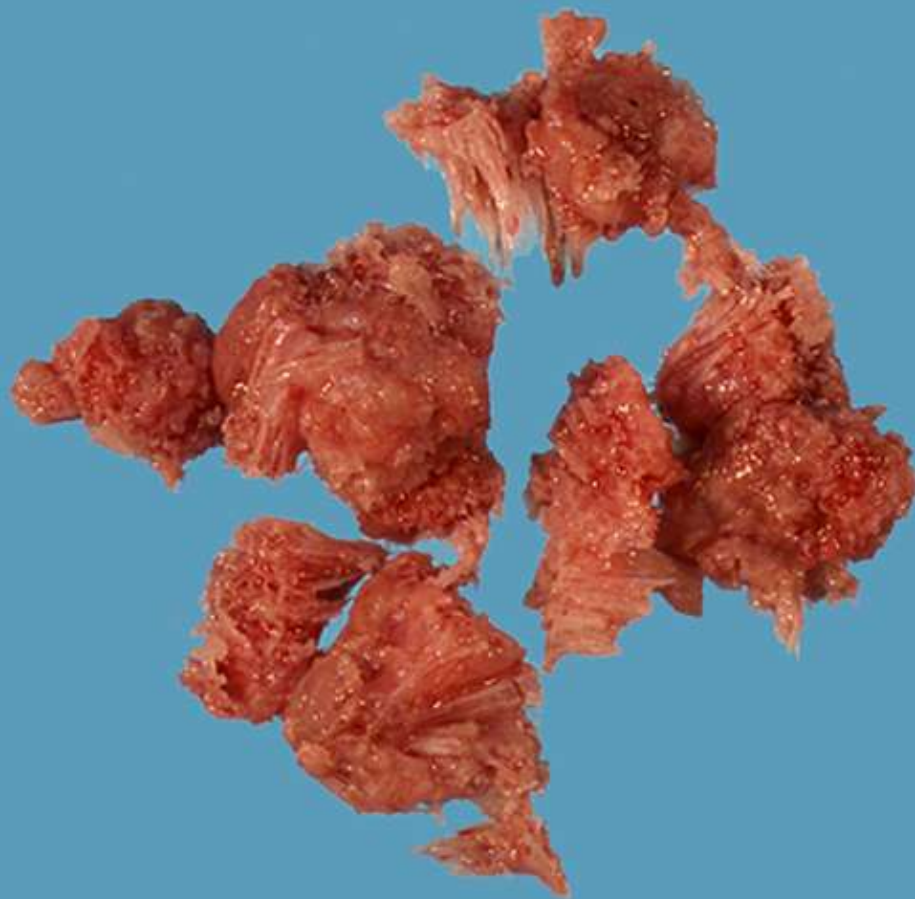
MRI showed an extra dural cyst compressing the right parietal lobe.

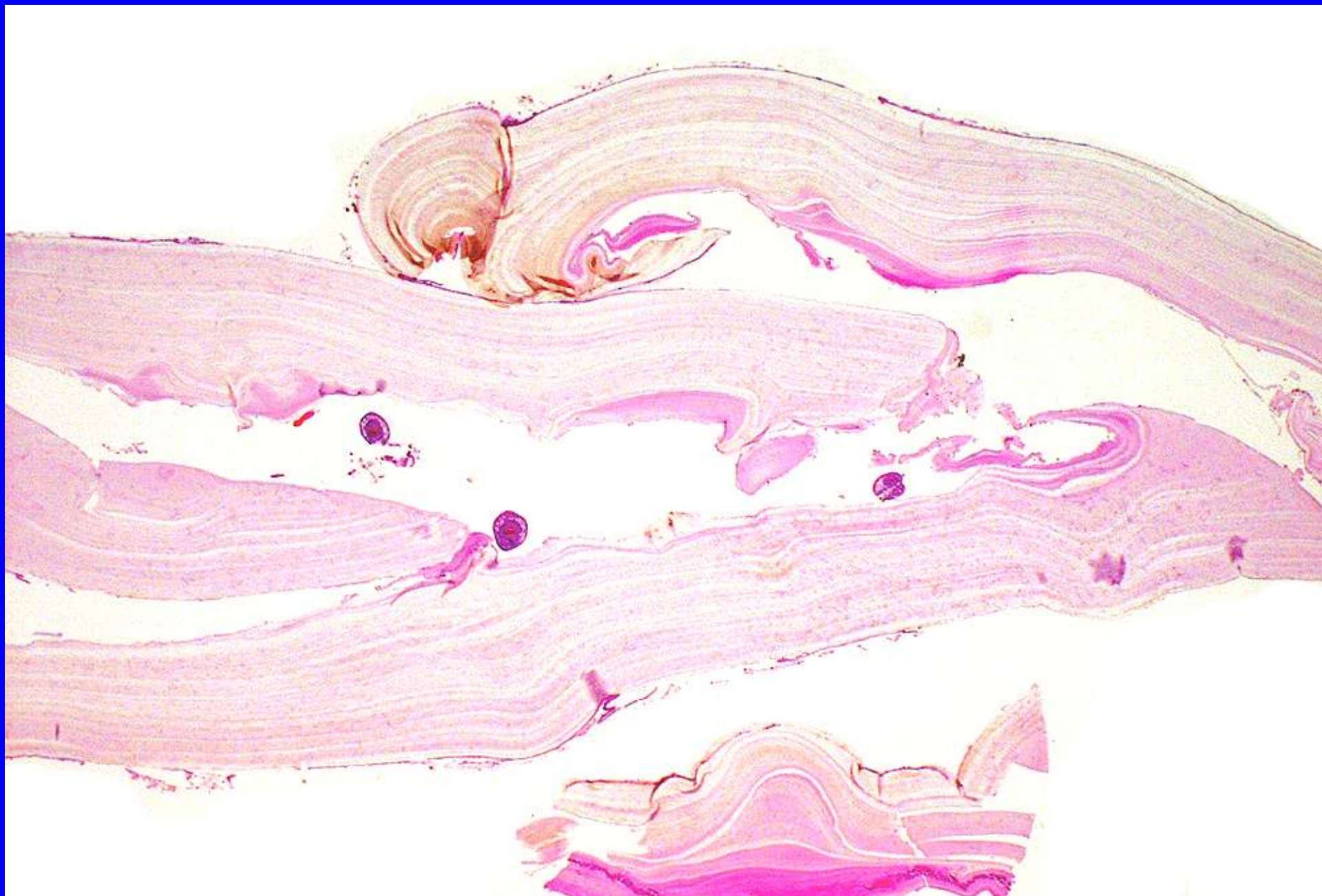
There appeared to be erosion of the bone of the overlying skull.

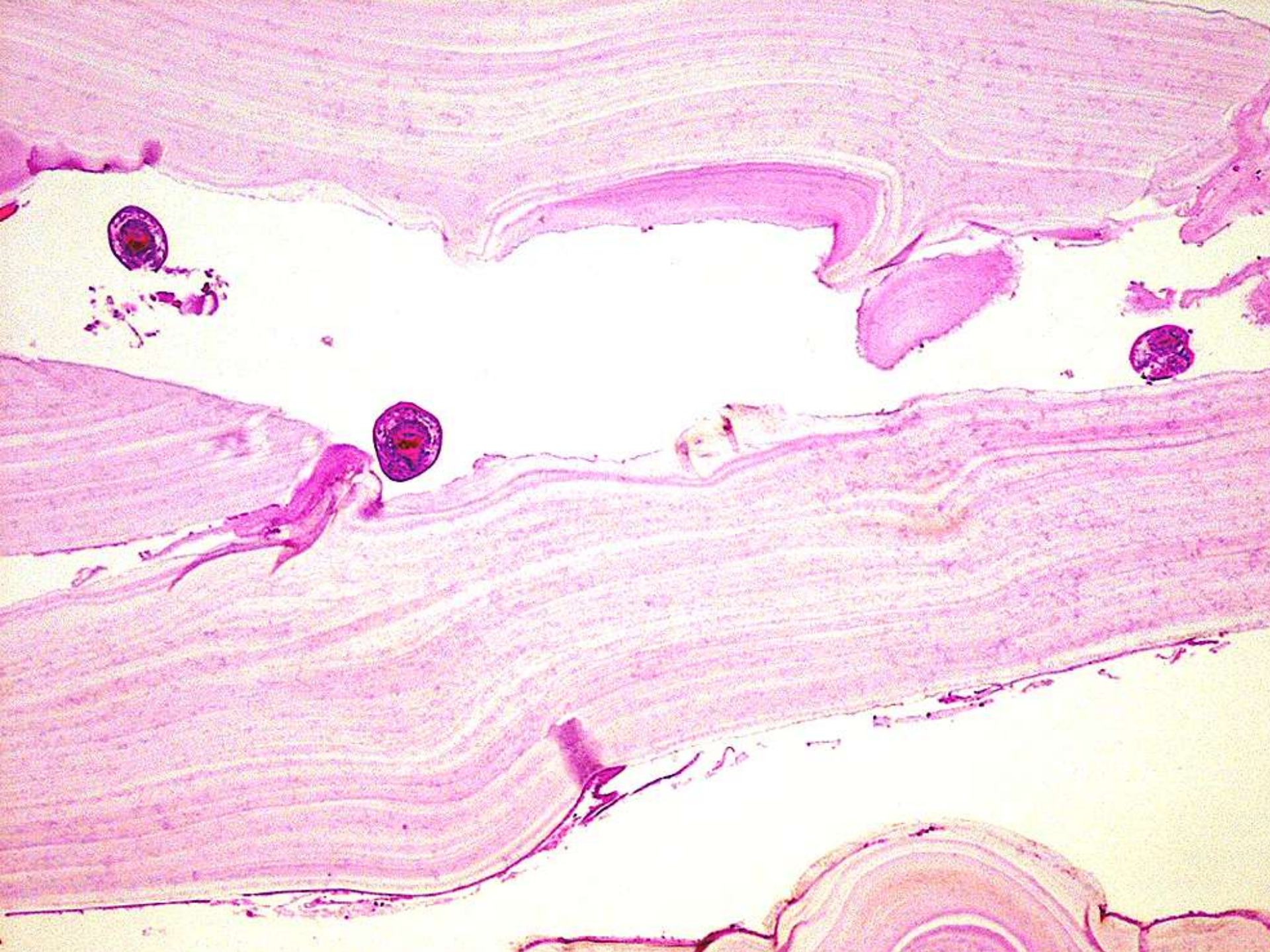The membrane was peeled off the dura and a small hole was made in the dura. Underlying brain seemed to be normal.

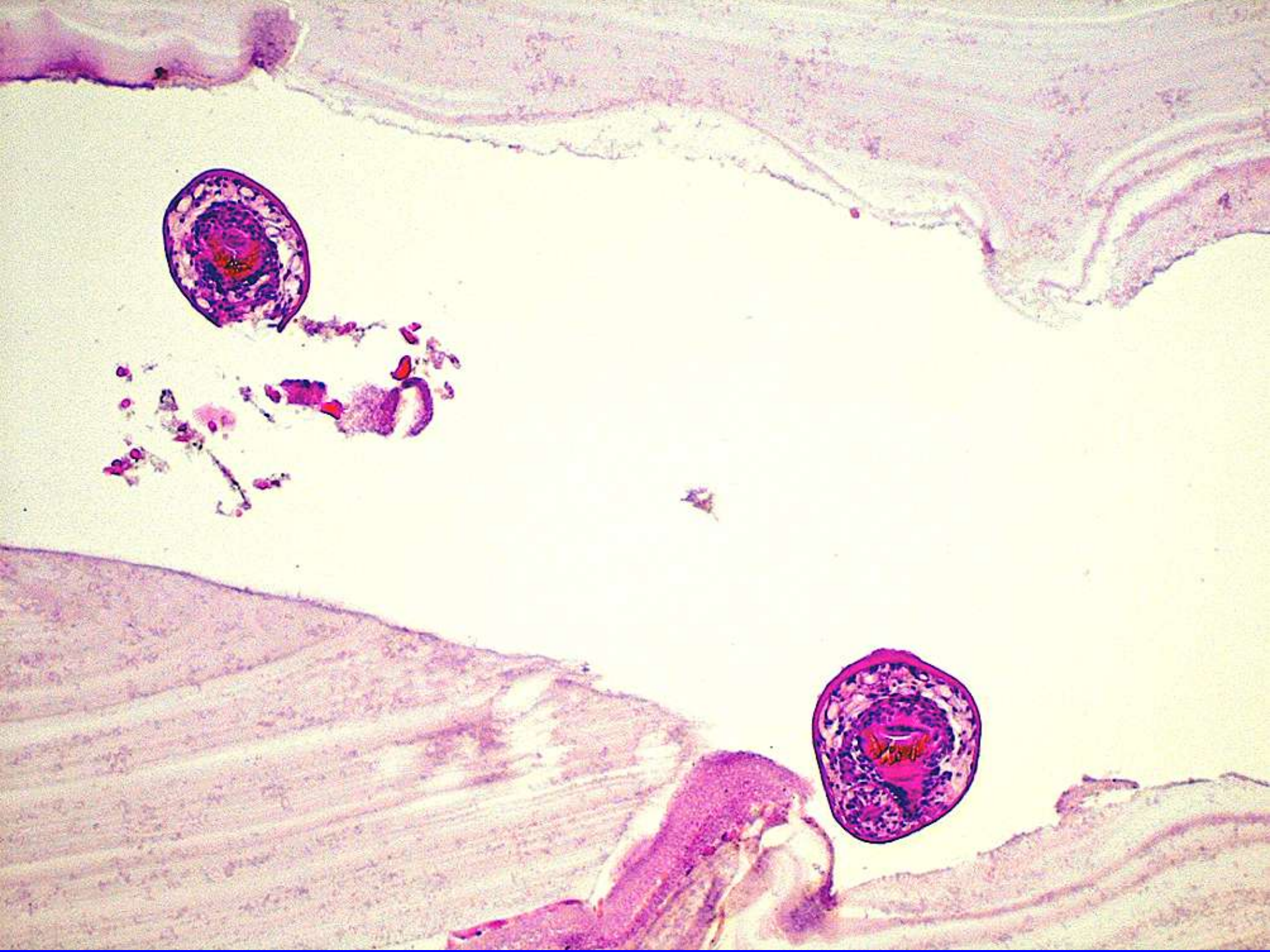


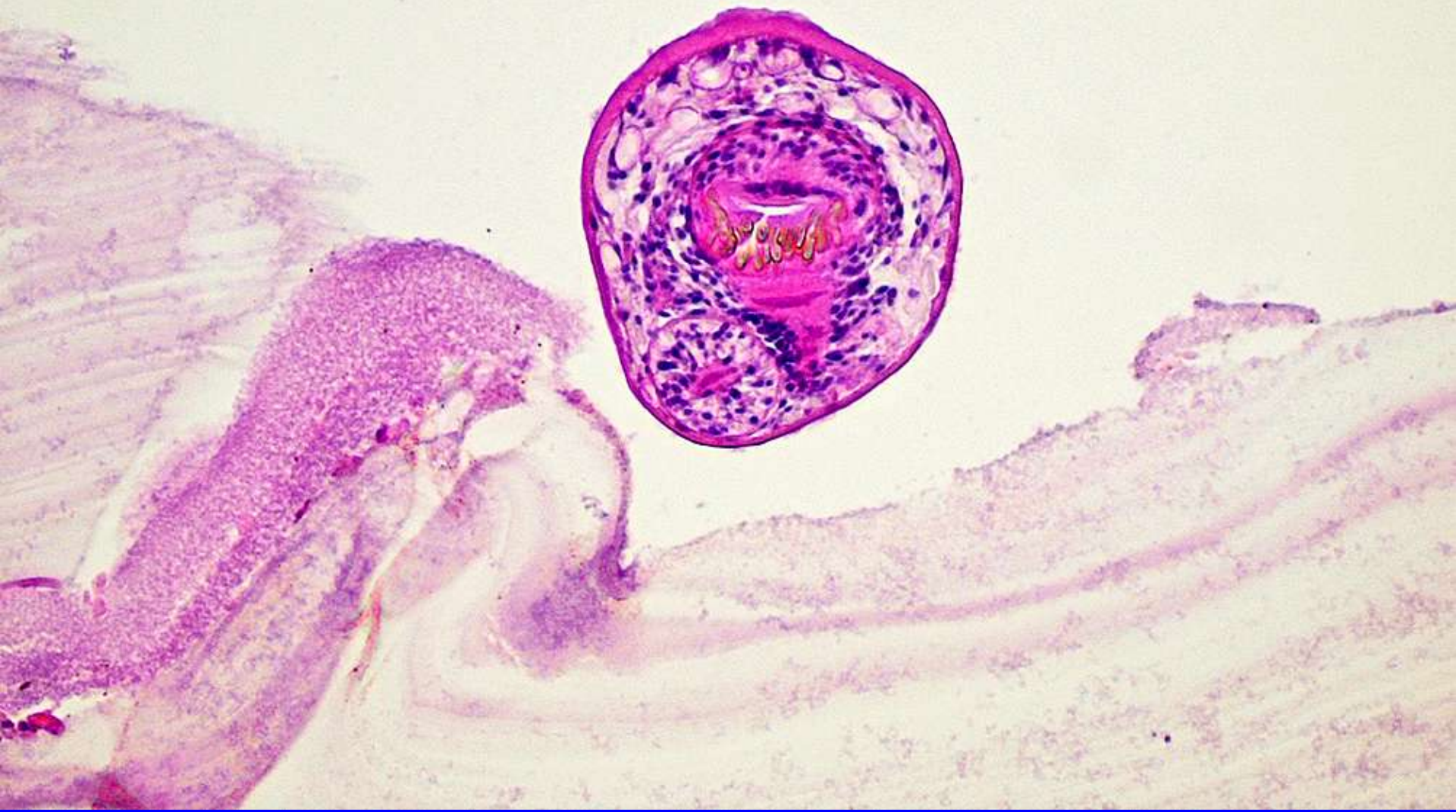






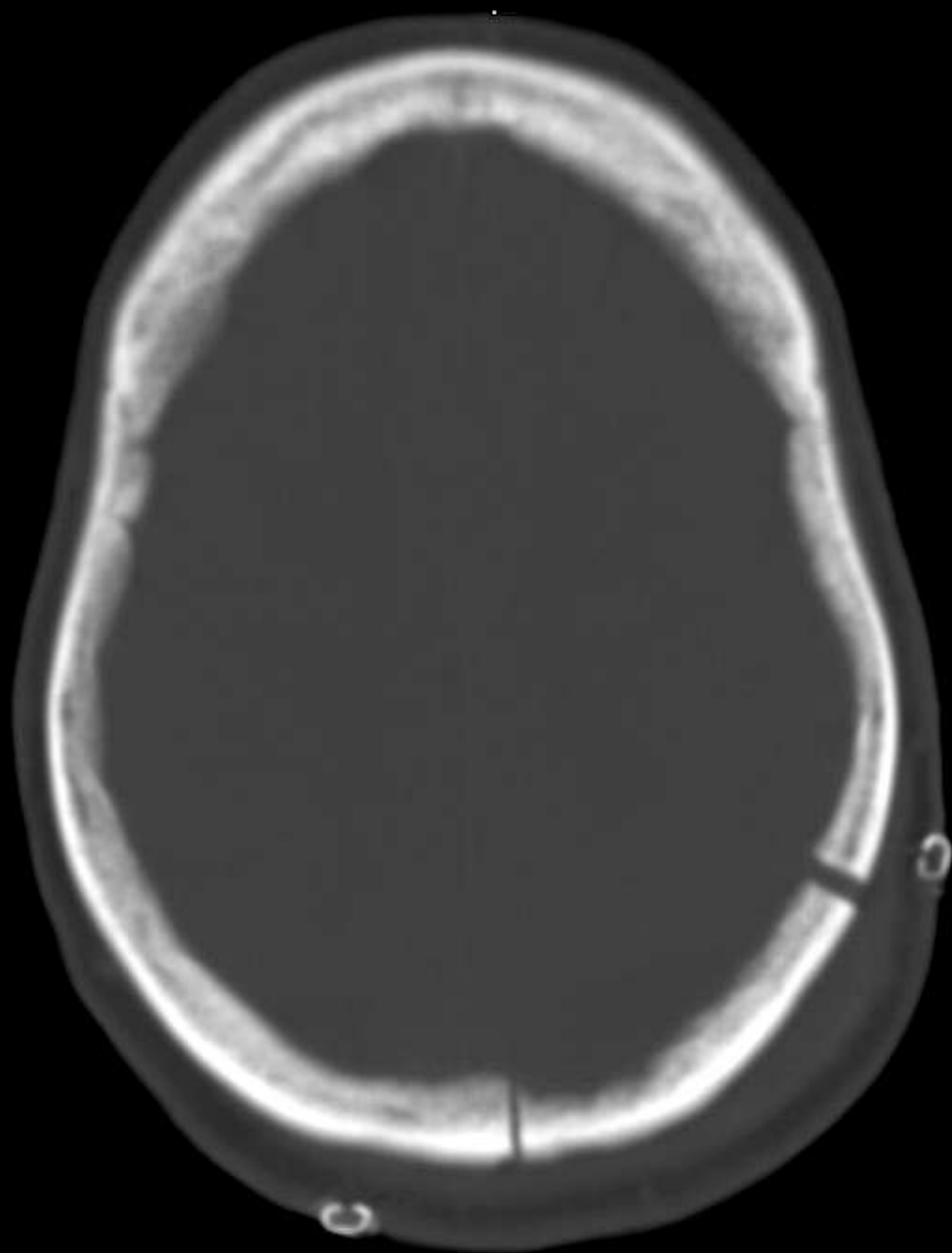






The inner part of the bone plate was drilled and soaked in betadine.

The dura was washed with citromide and the bone plate was replaced.



Post operatively an ultrasound showed no lesion in the liver.

She was given a 2 week course of praziquantel

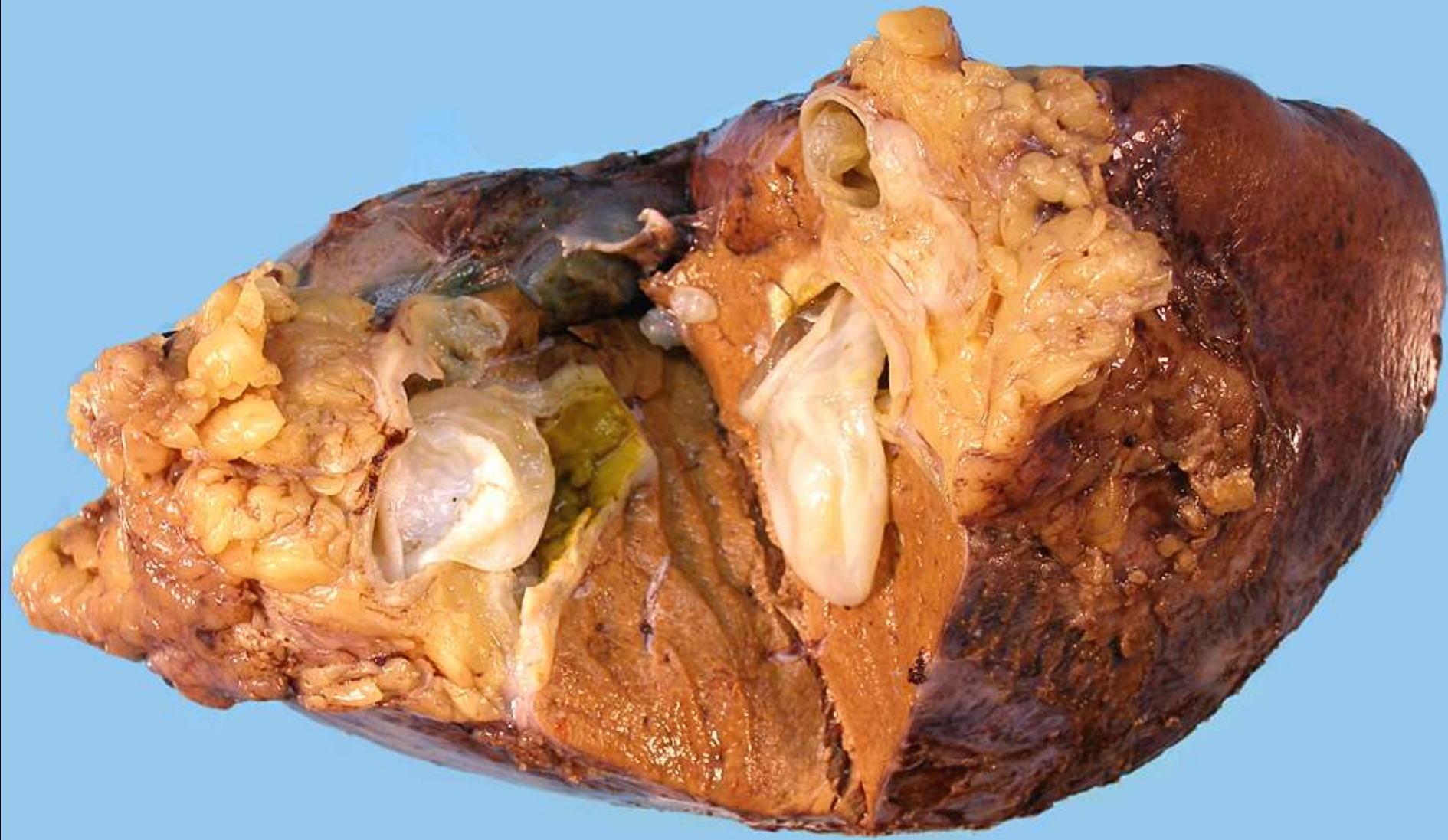
and put on an 8 month course of albendazole 400mg twice daily.

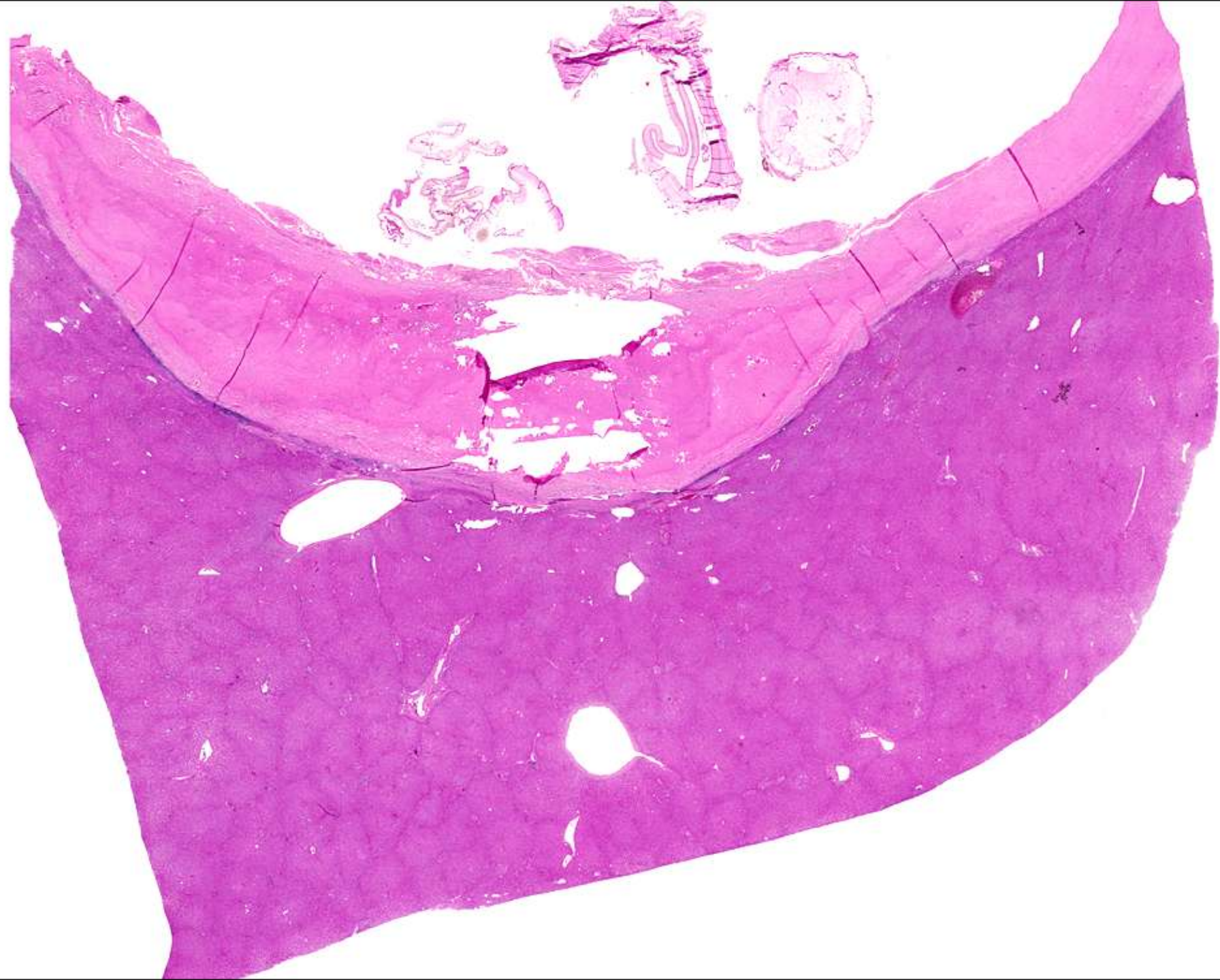
Another patient with a hydatid cyst in the liver was treated at PAH in February 2009 by partial hepatectomy.

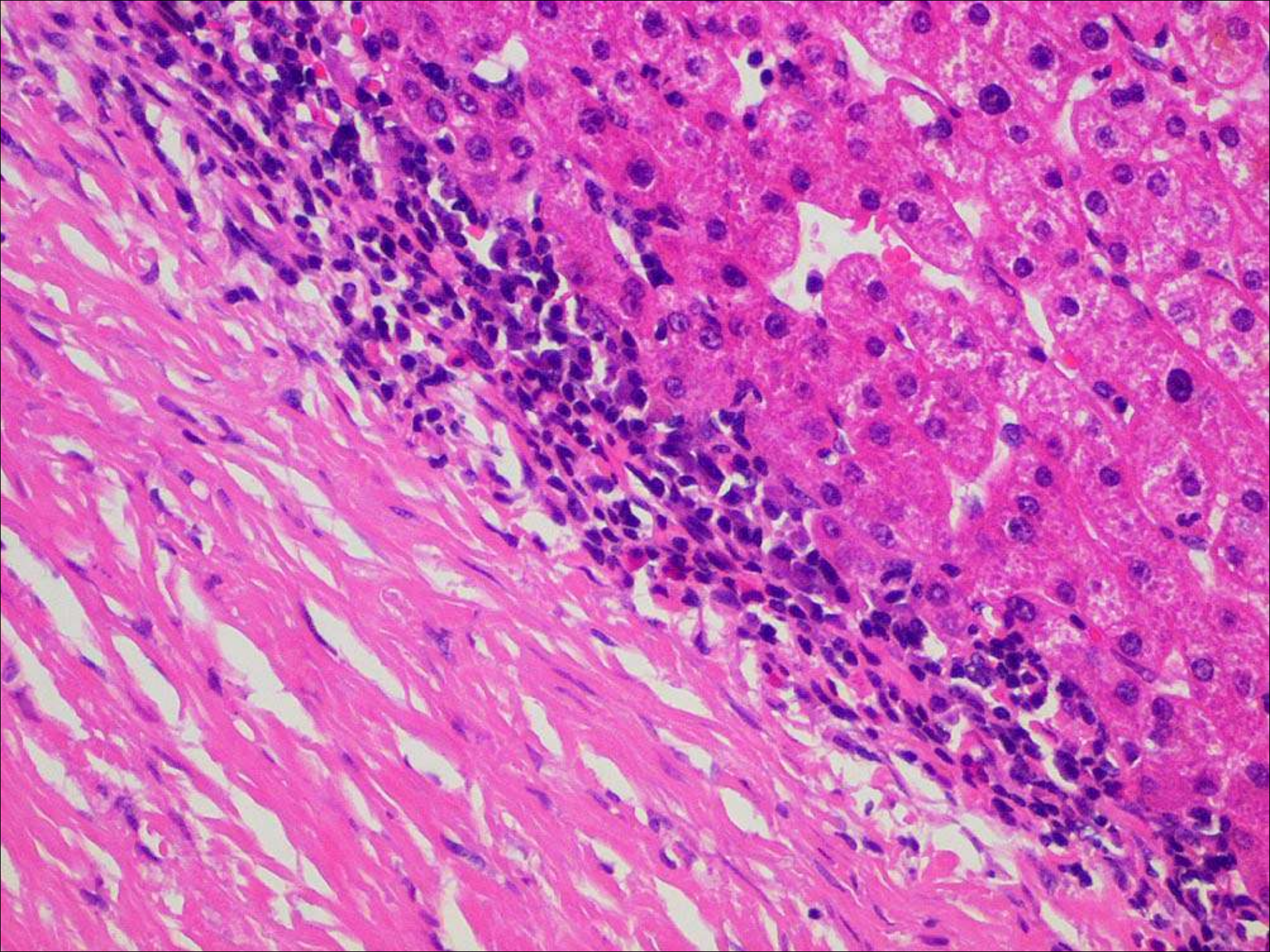
She had preoperative treatment with praziquantel to sterilise the cyst.

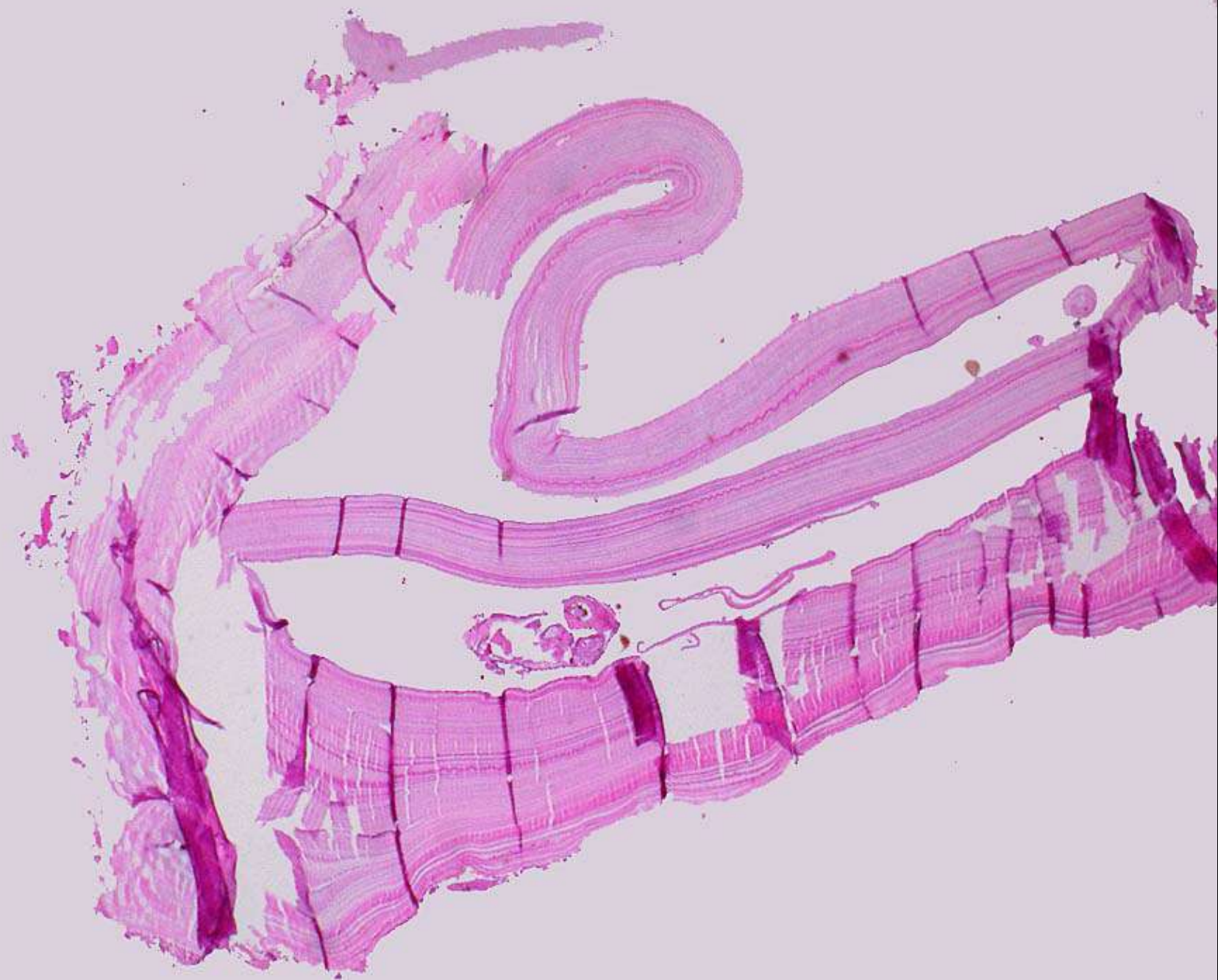
She was seen in May 2009 and had a normal Pap smear.

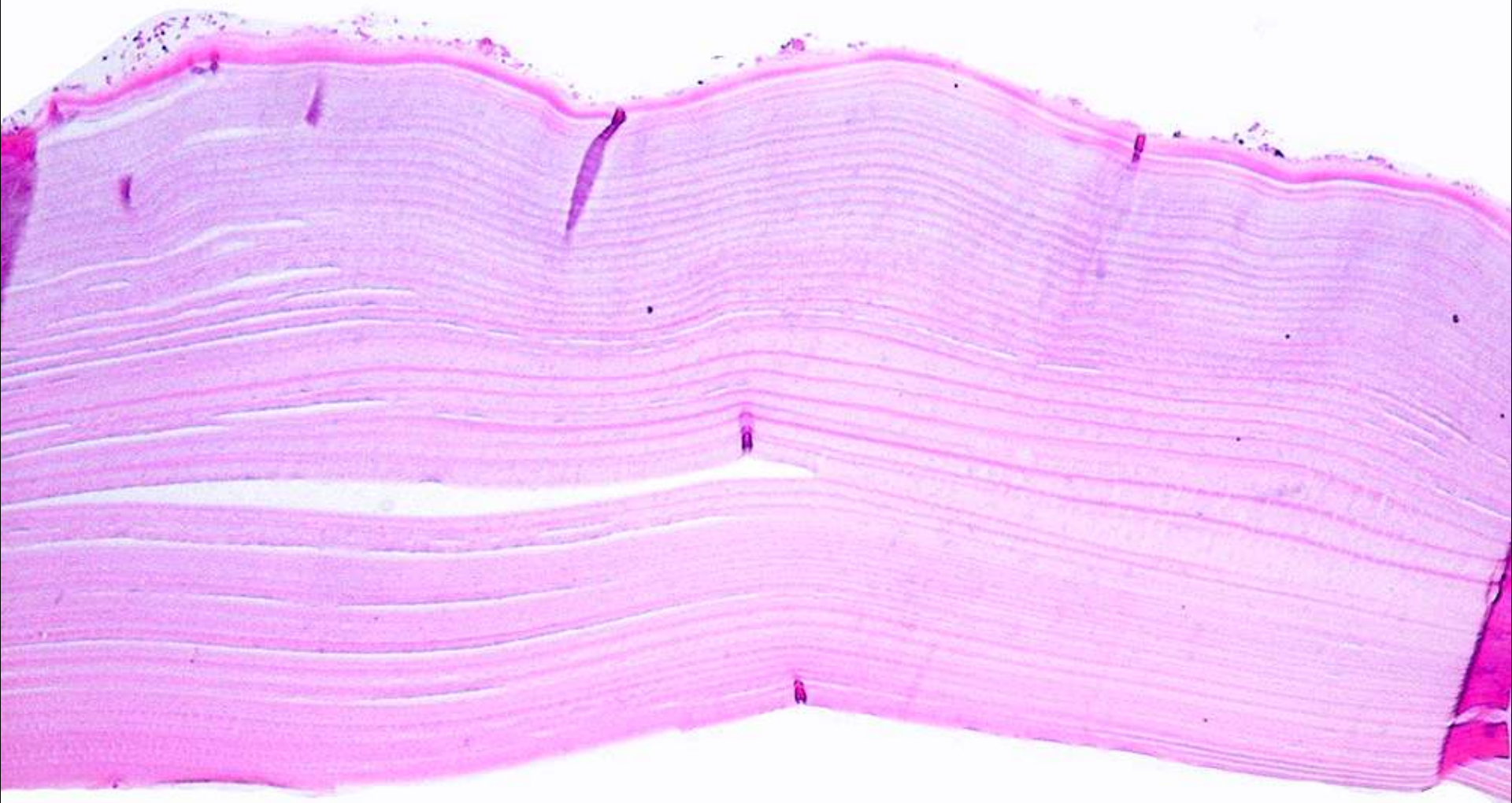
There was no mention of the Hydatid disease.

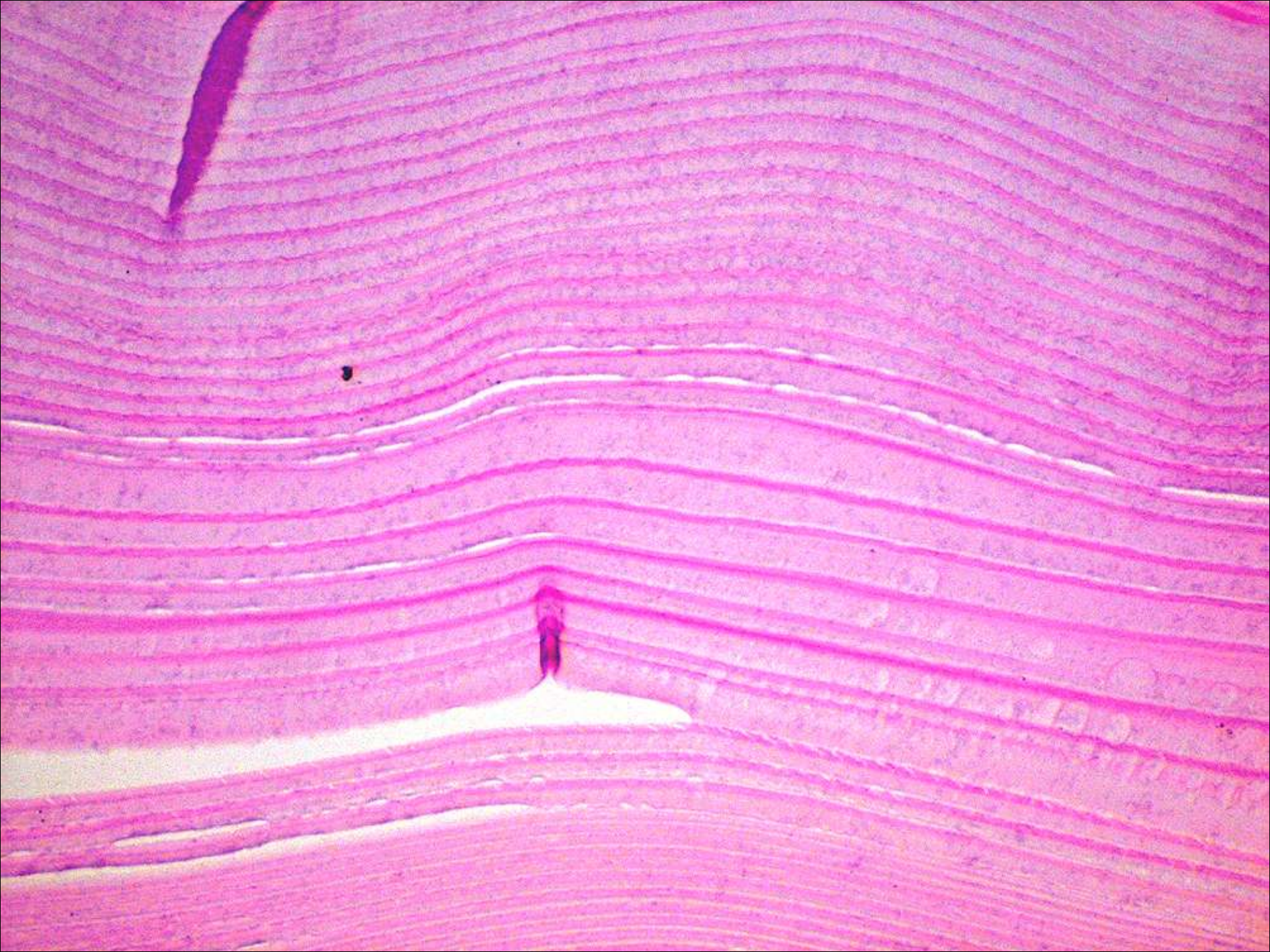


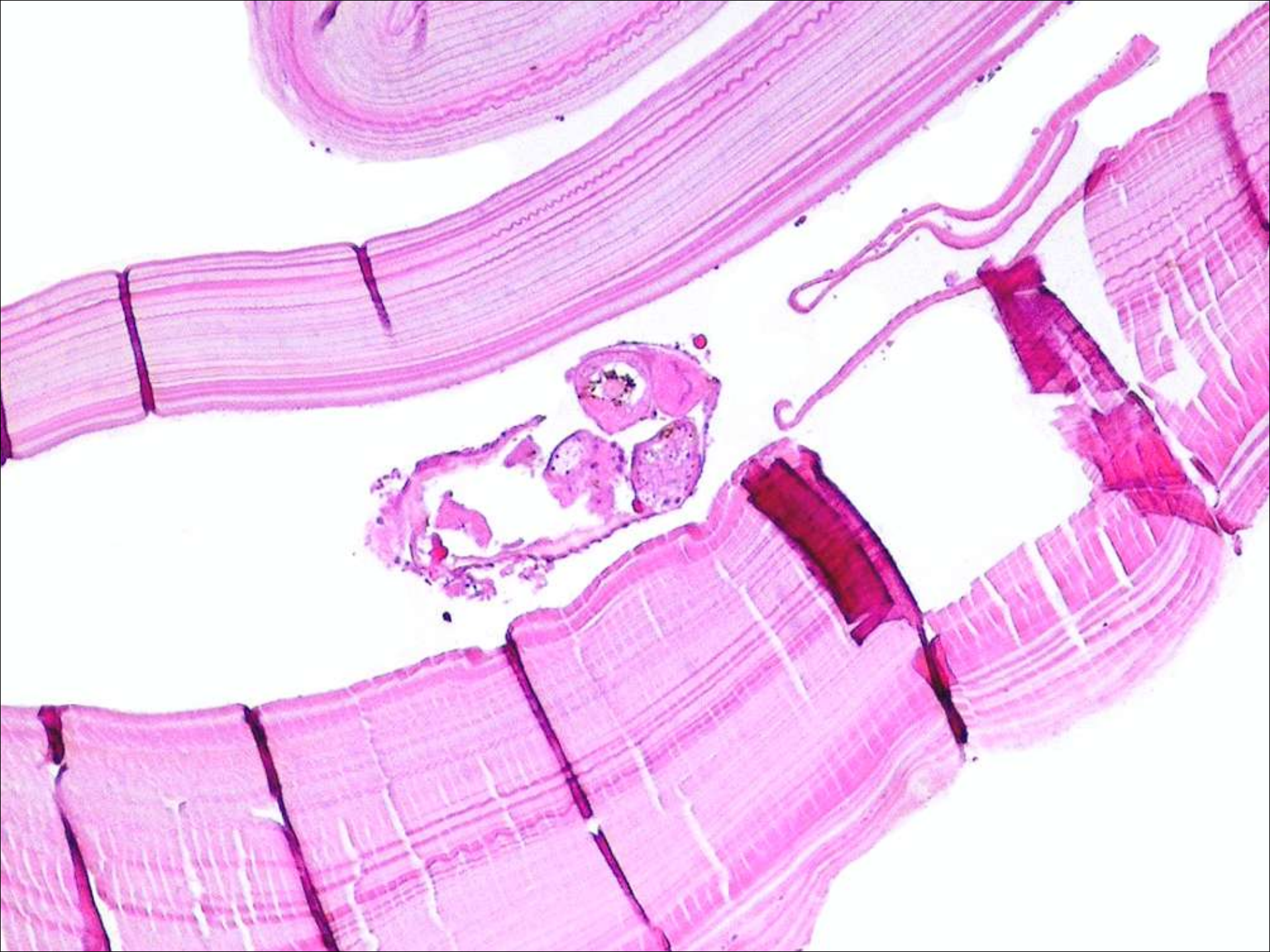

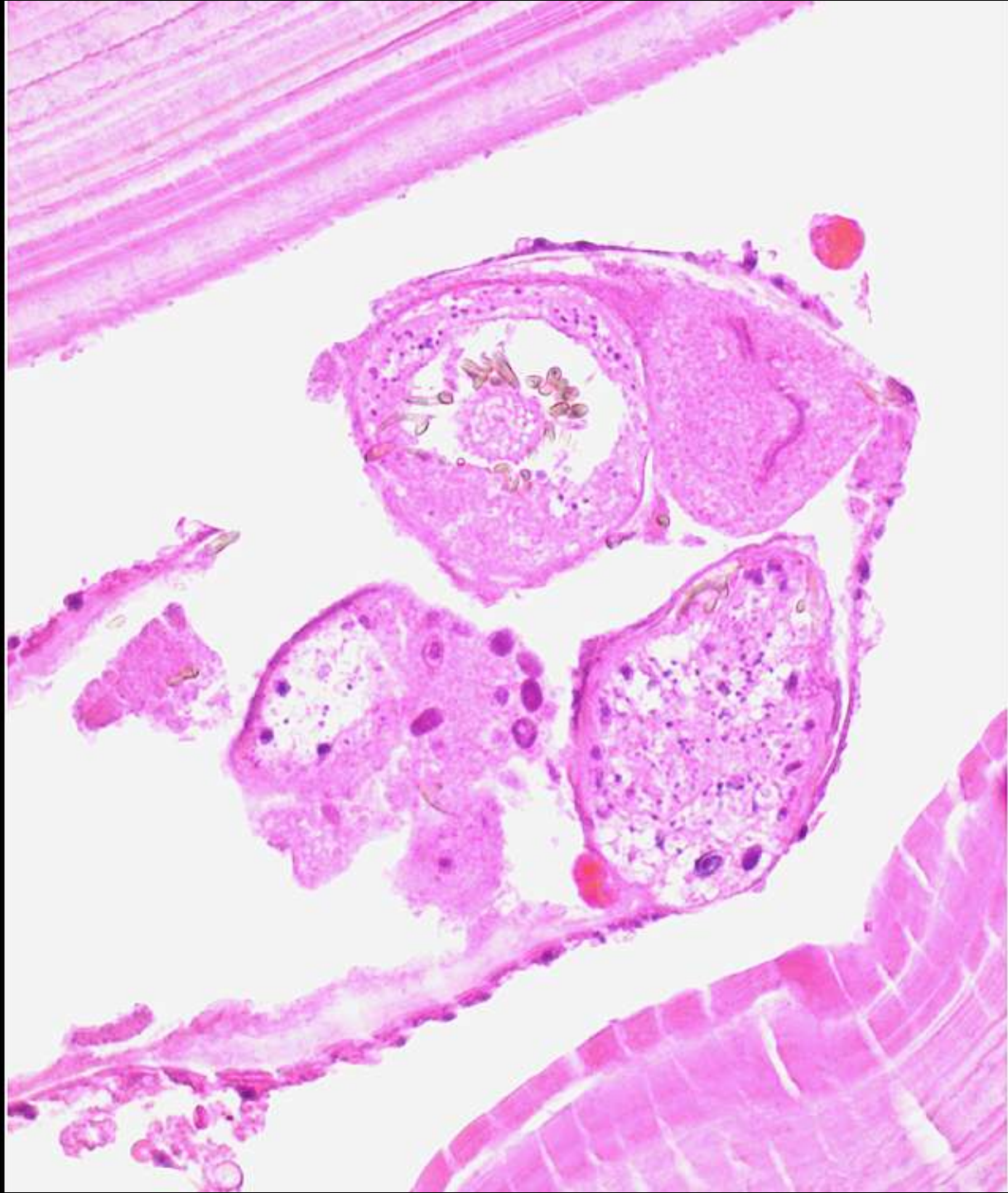














Echinococcus granulosus

Sheep dogs with adult worms in their gut.



Eggs passed in feces contaminate the environment.



Eggs are eaten by sheep and humans.



The larval stage of the parasite (hydatid cyst) develops in sheep and in humans.


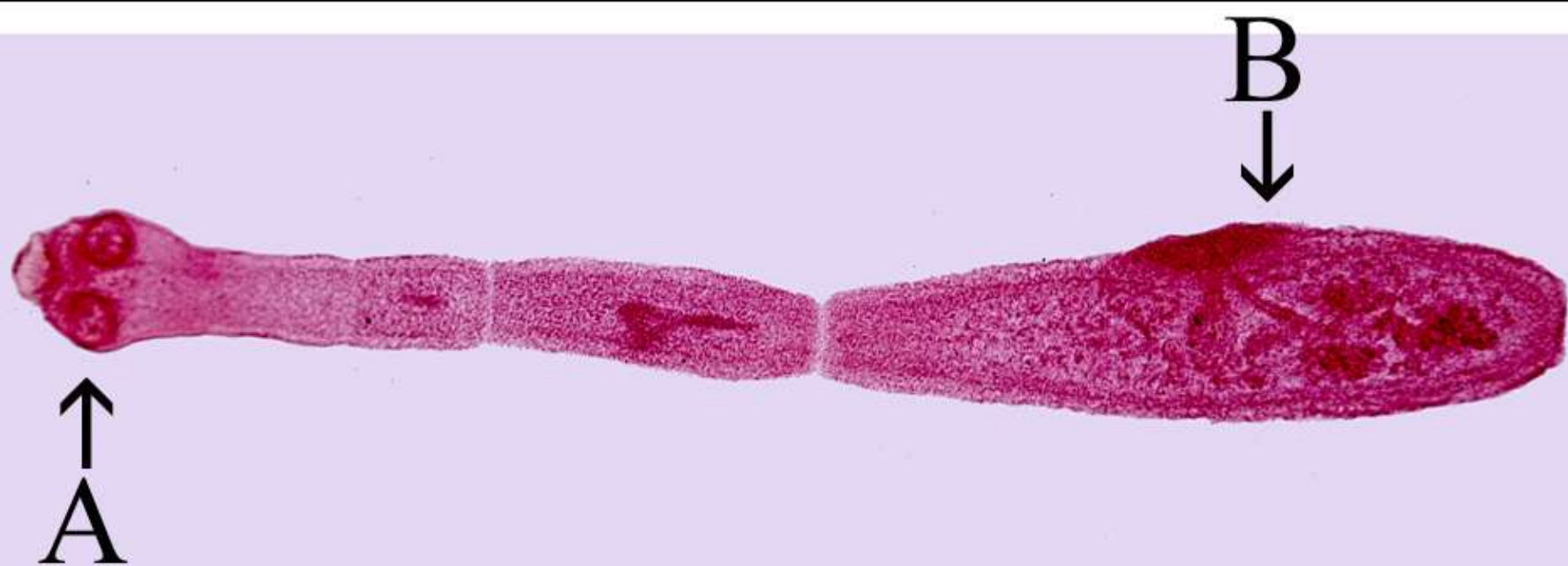



Sheep are butchered by sheep farmers for domestic meat consumption and the offal (liver, lungs, kidneys) are fed to sheep dogs.

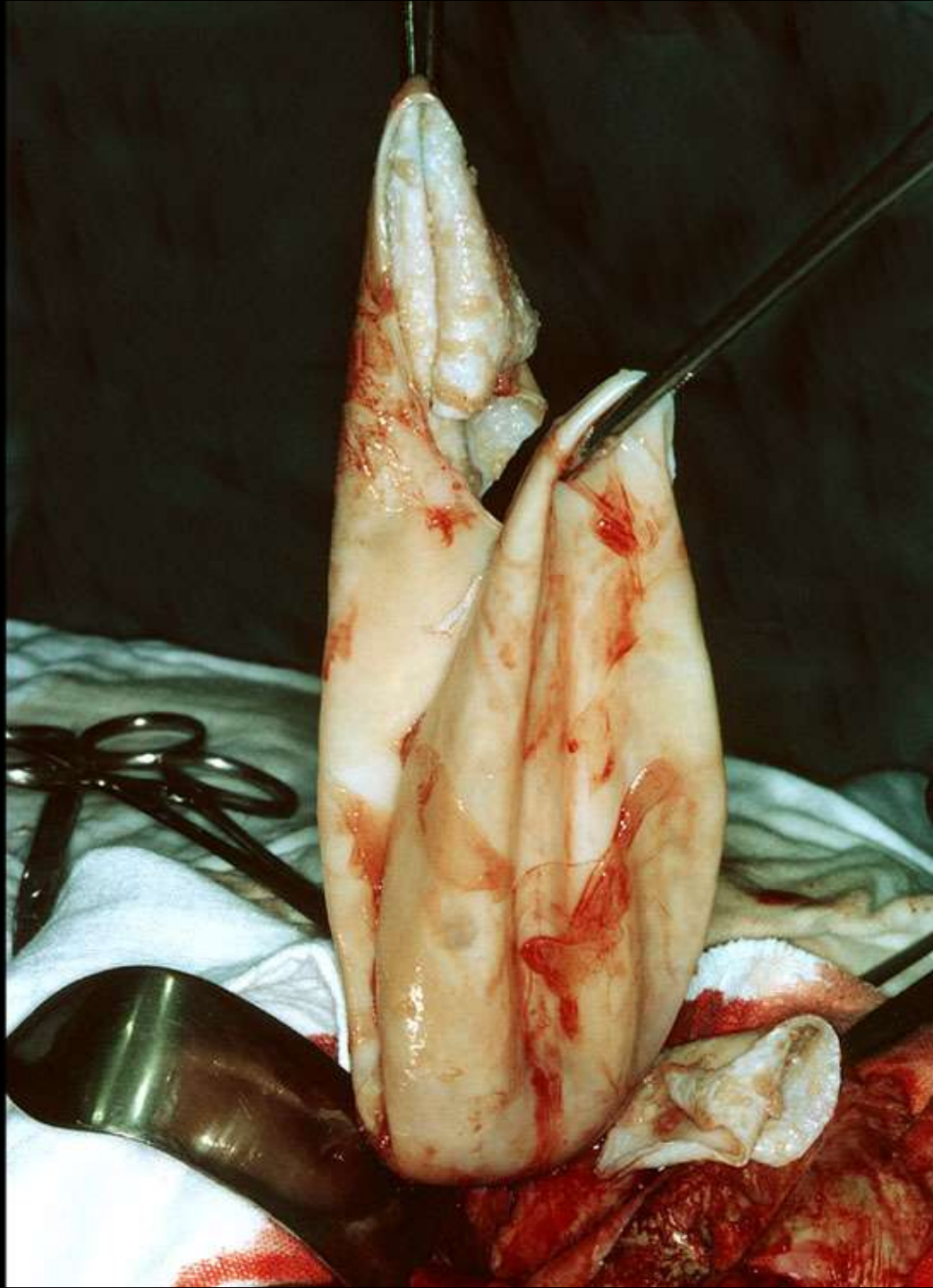


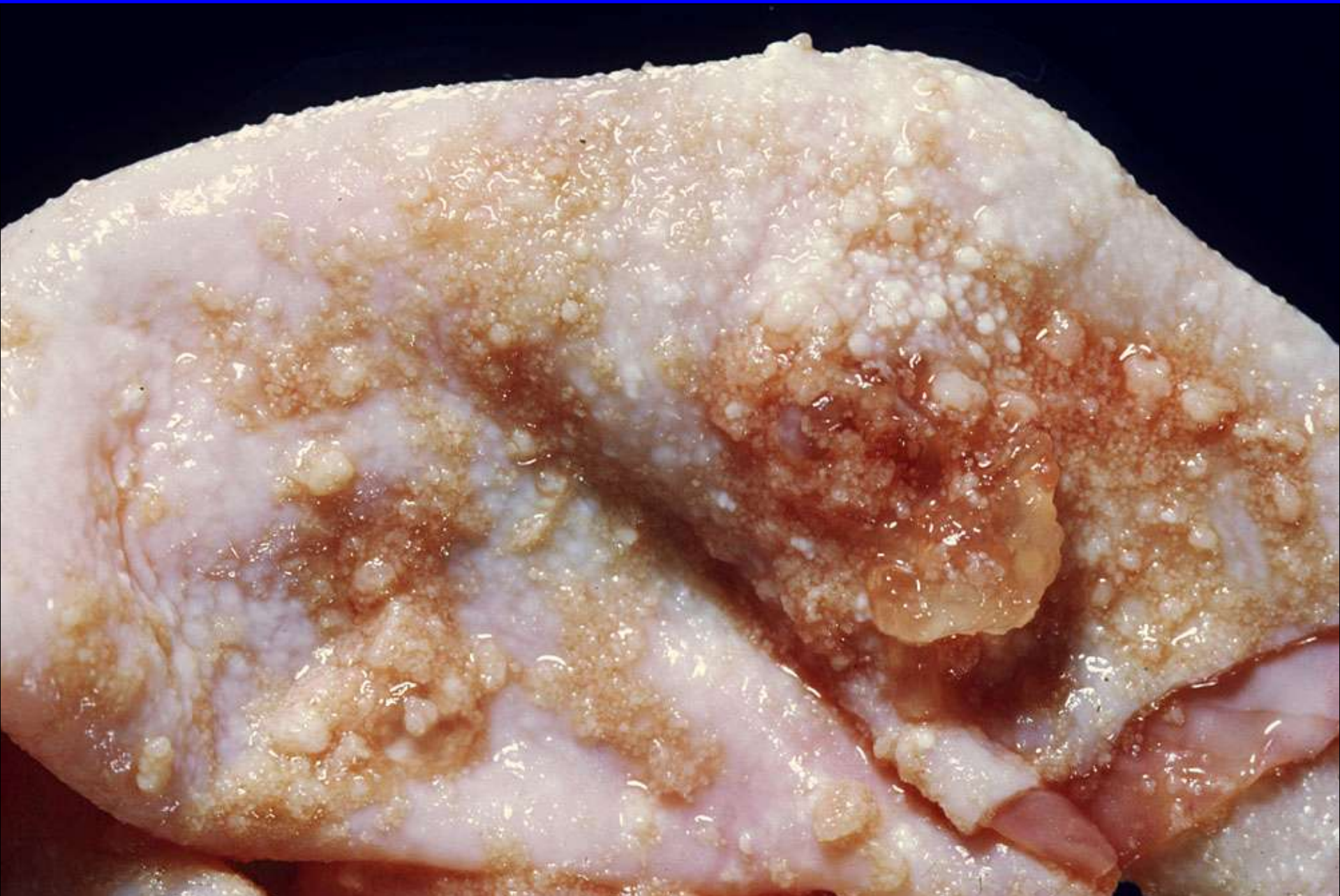Sheep dogs develop adult worms.

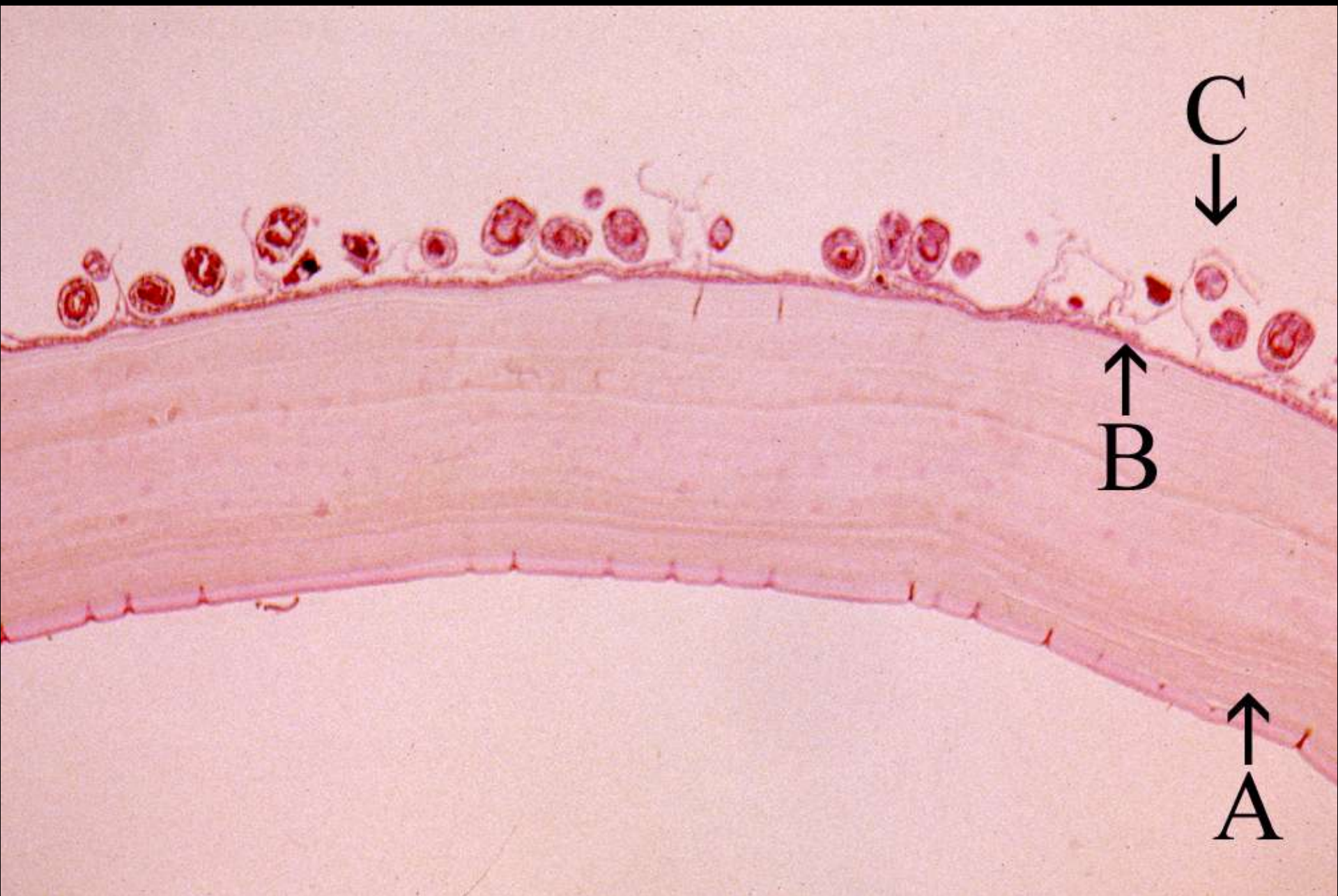Note: The life cycle of *Echinococcus multilocularis* is much as above, but the definitive host is the fox.

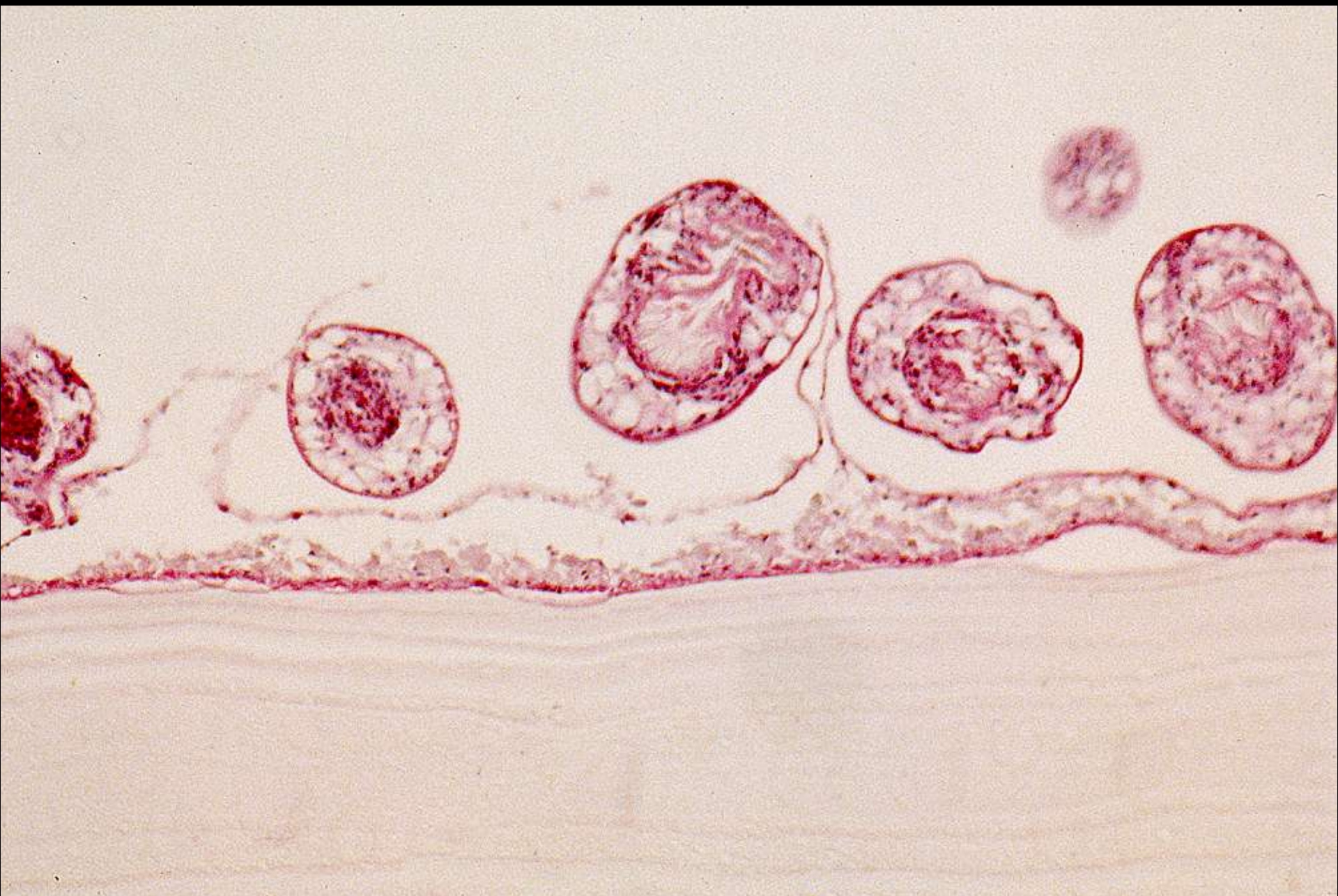

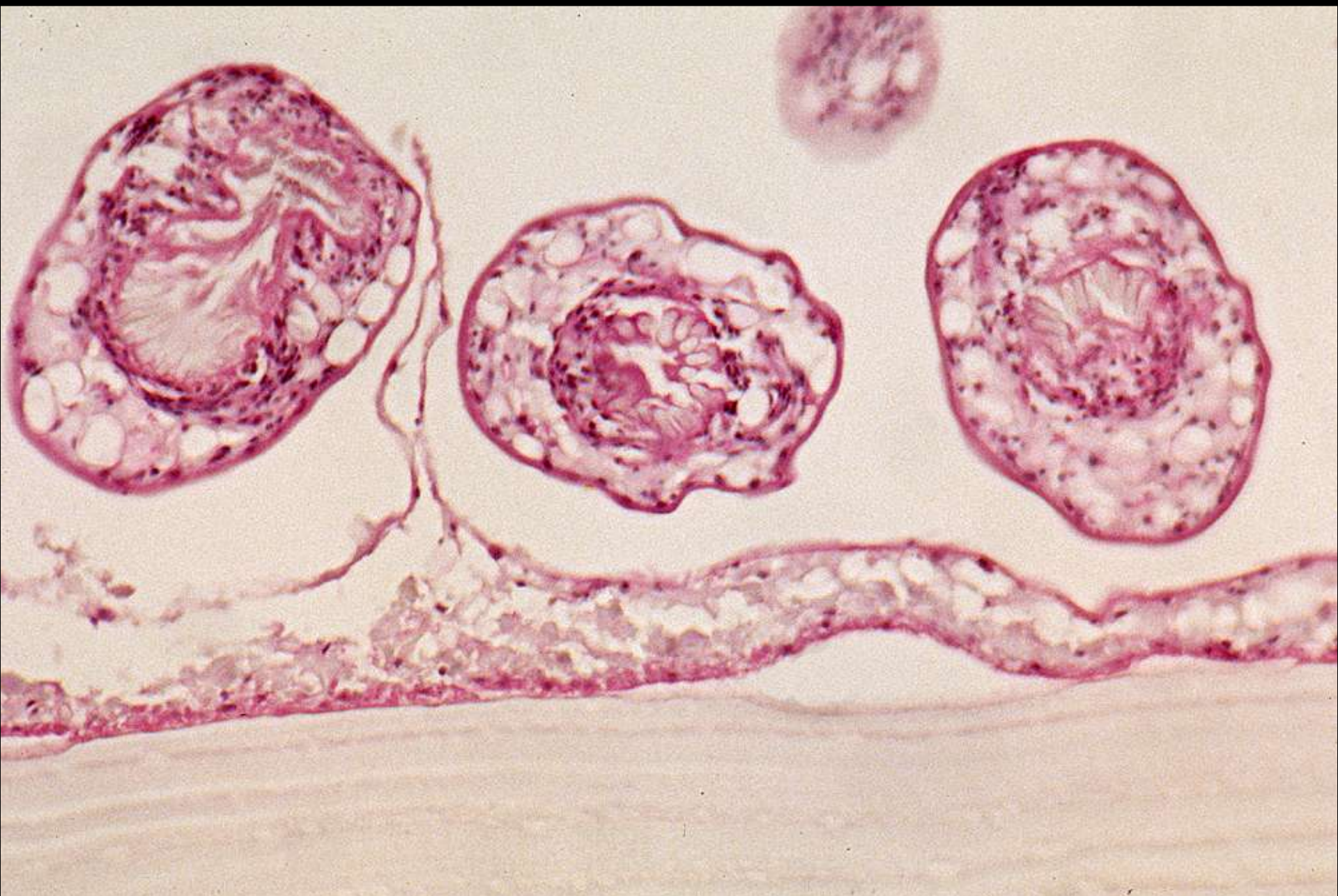


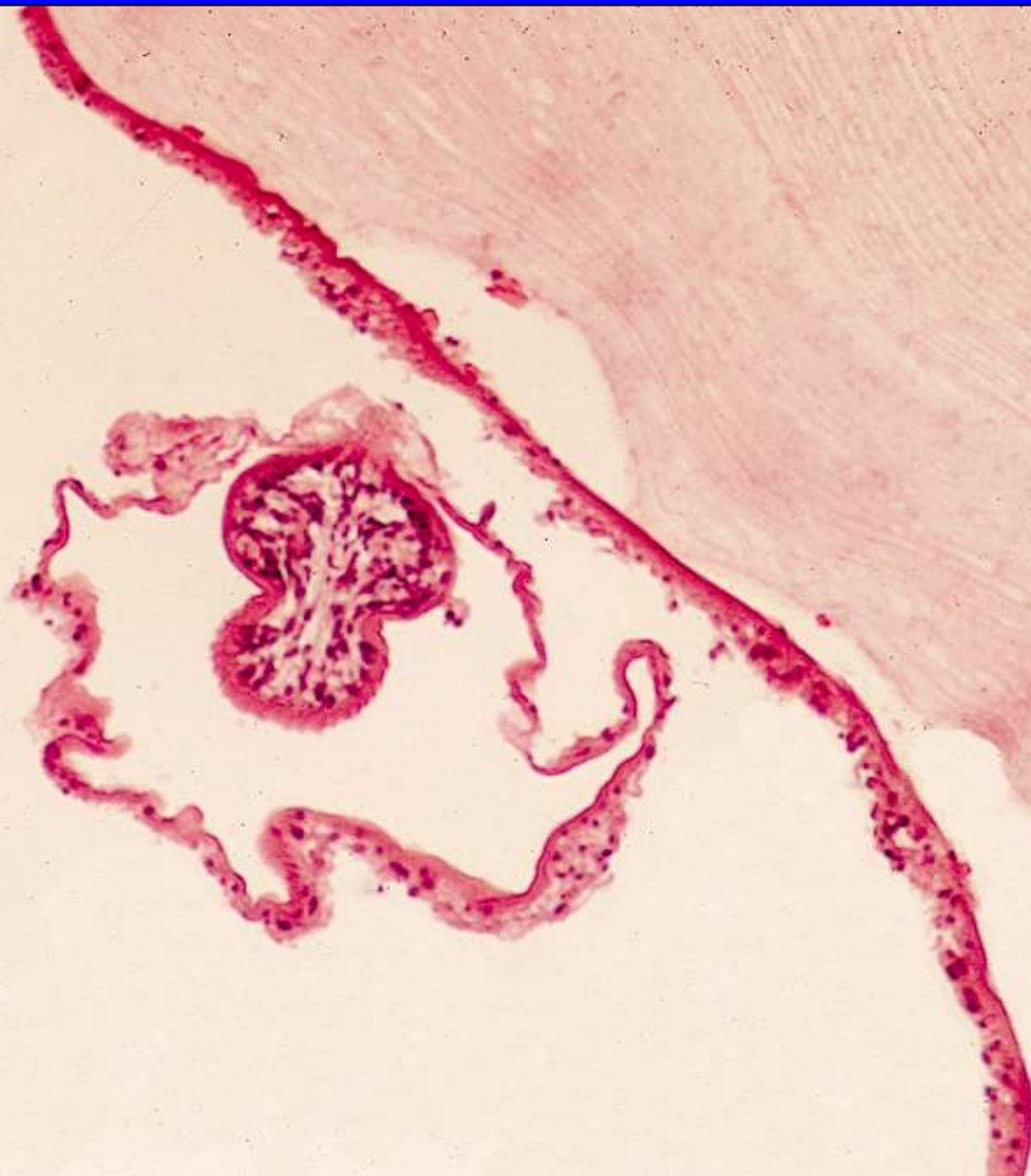


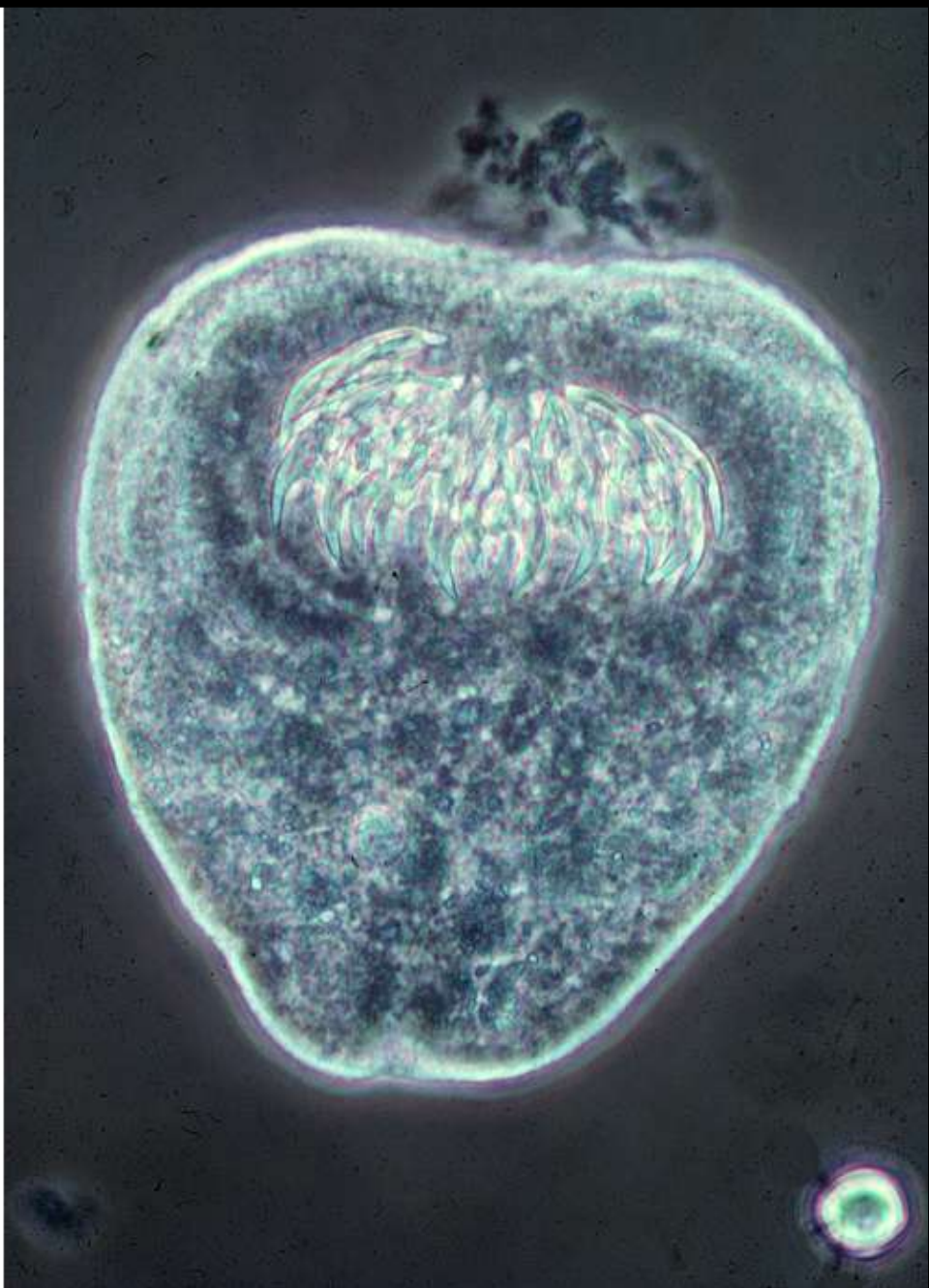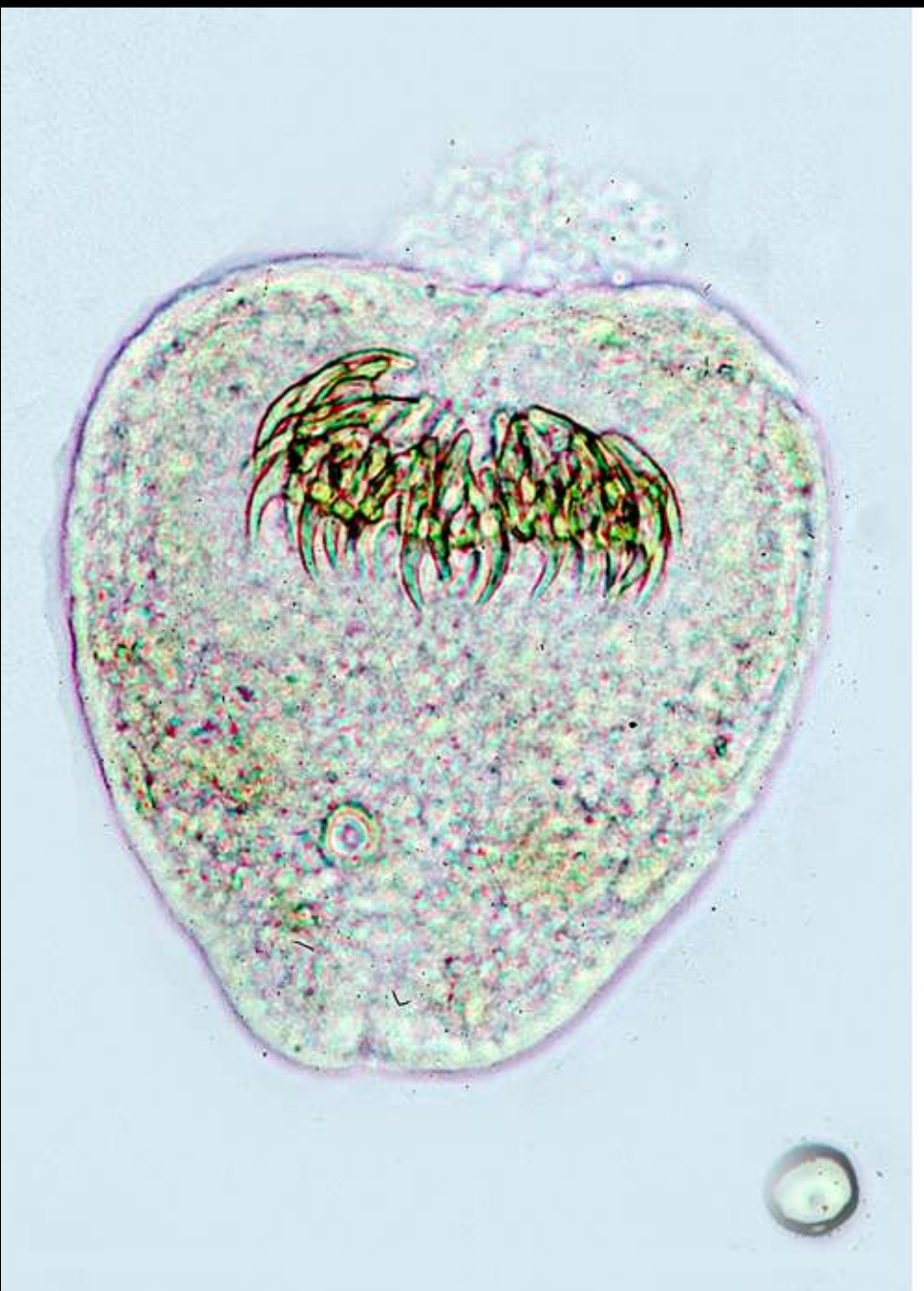




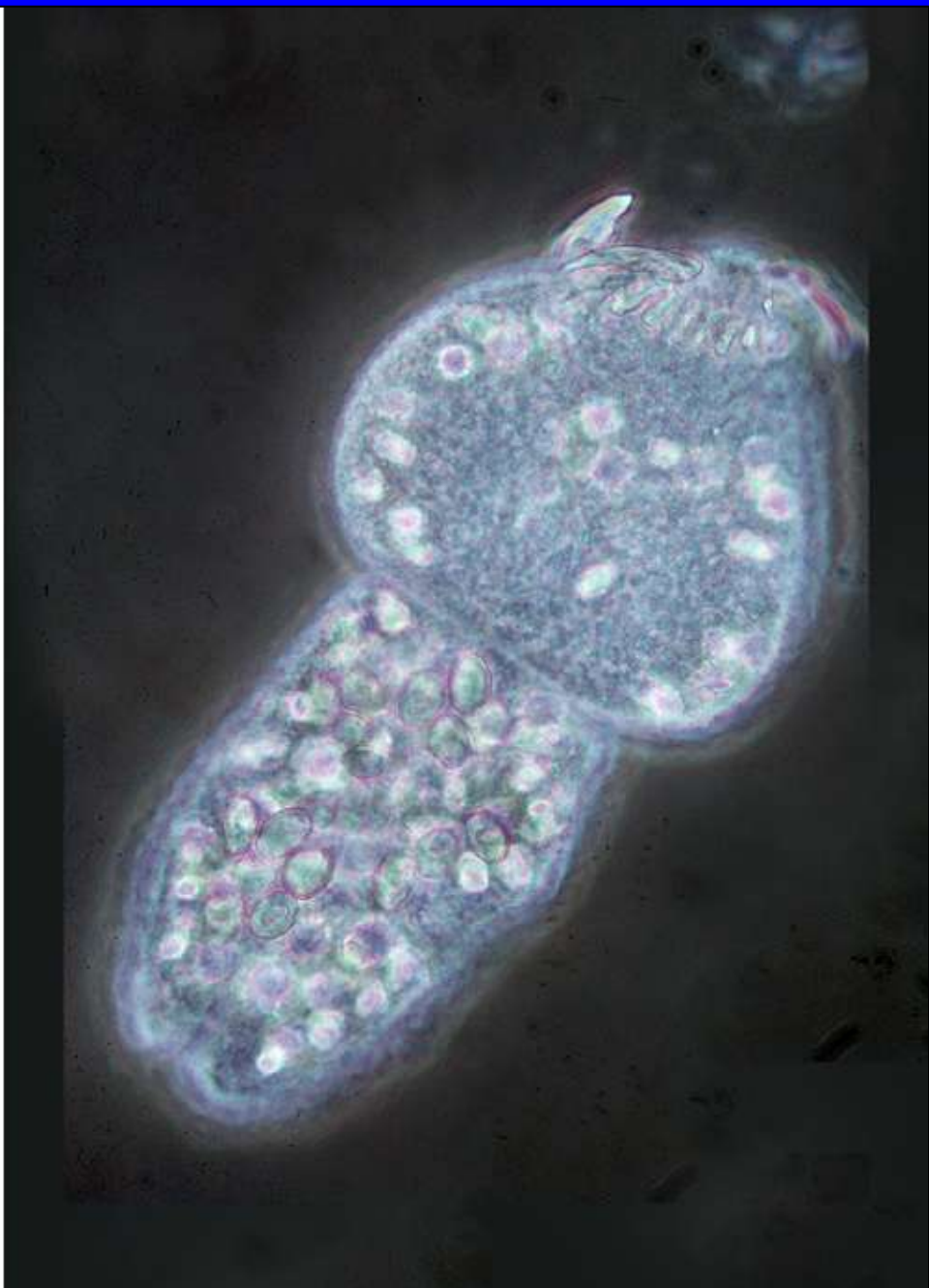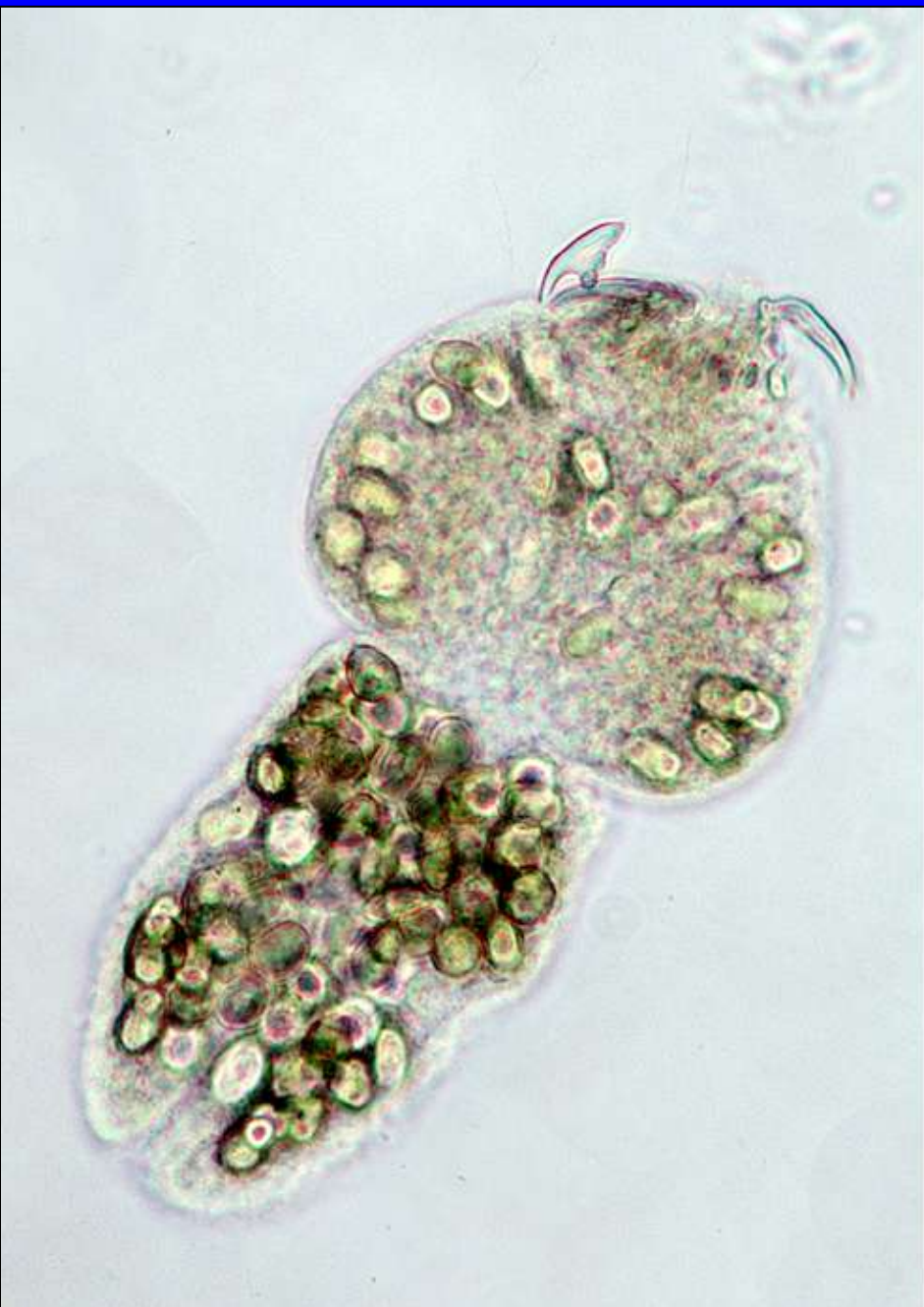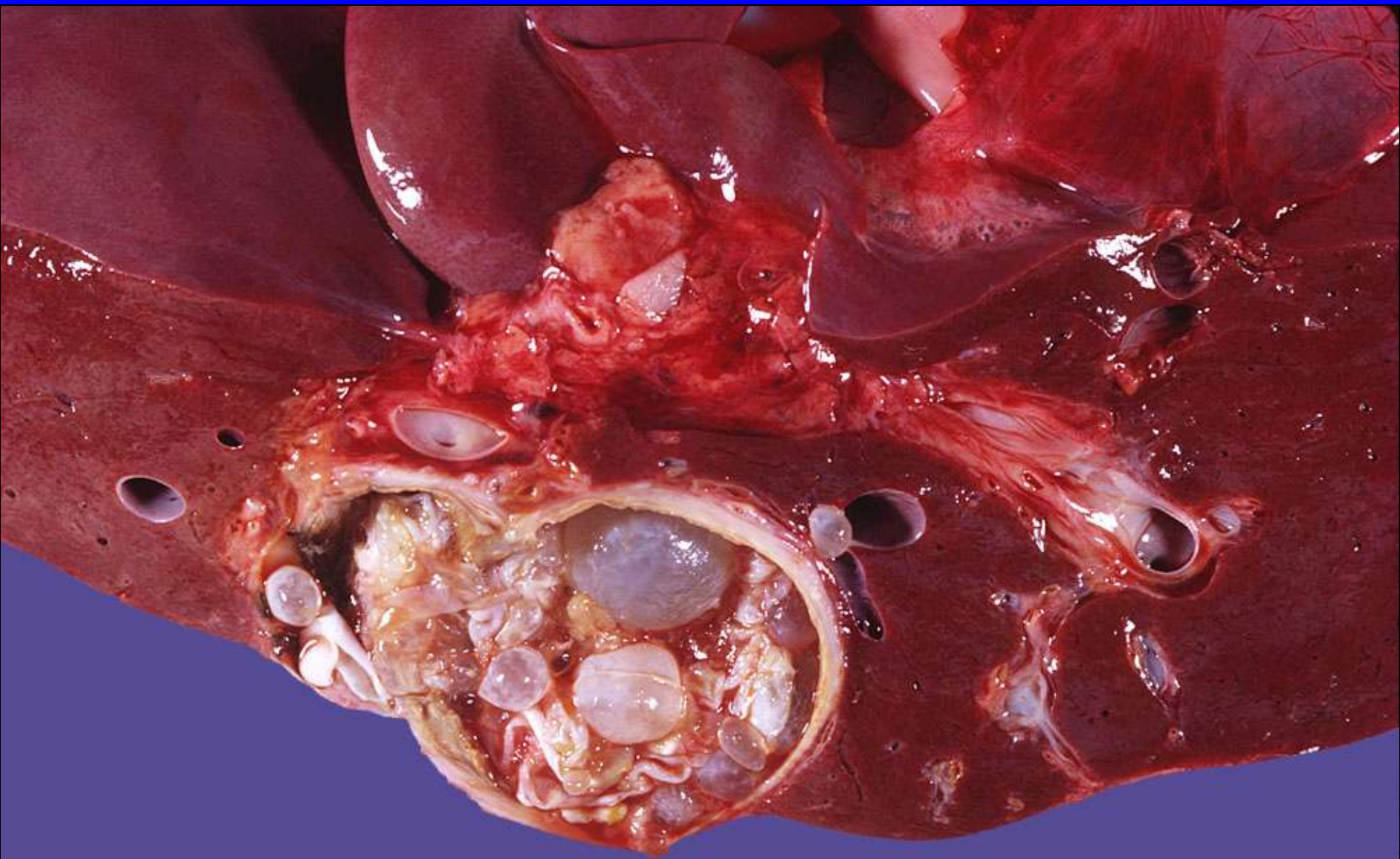


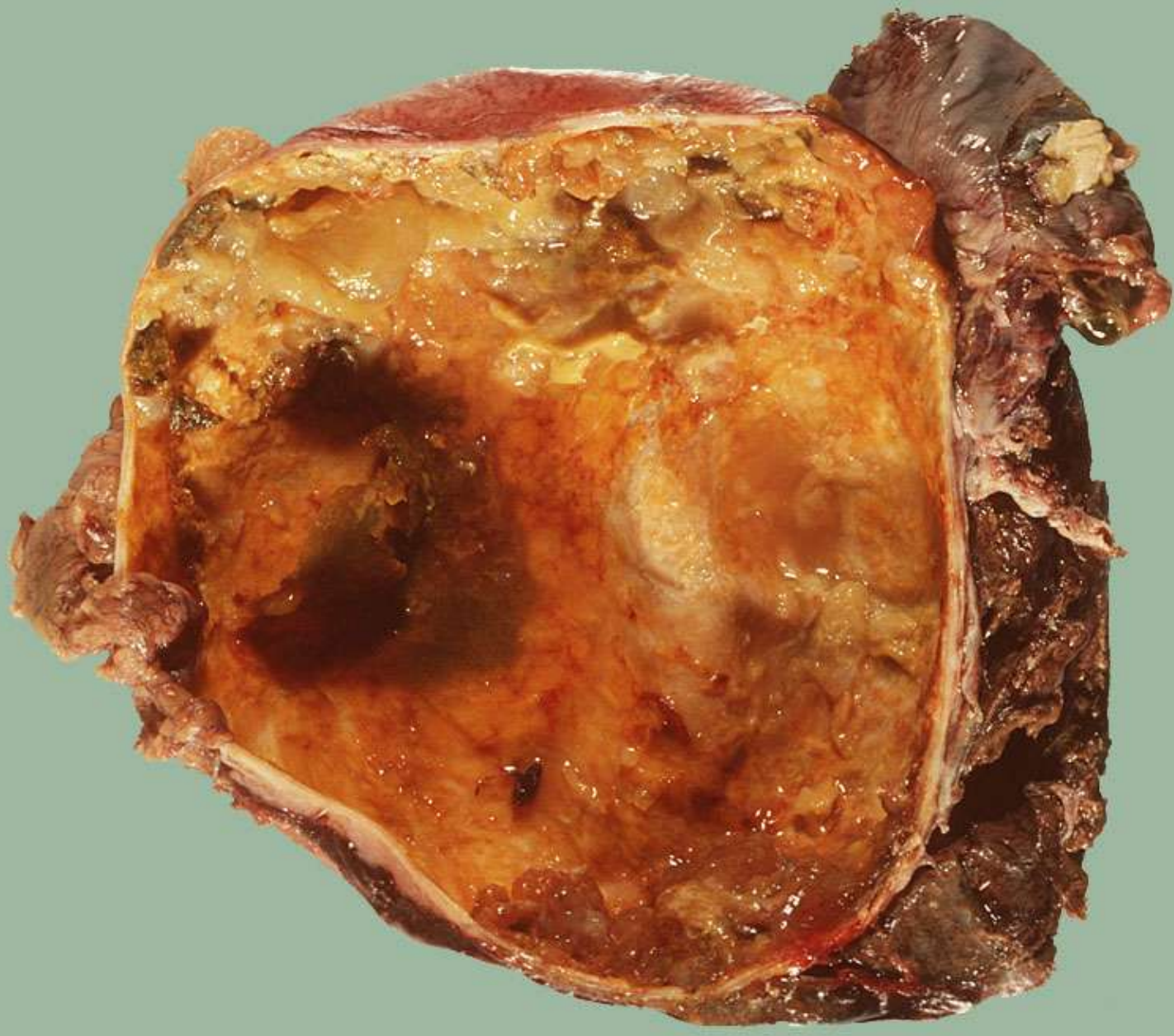


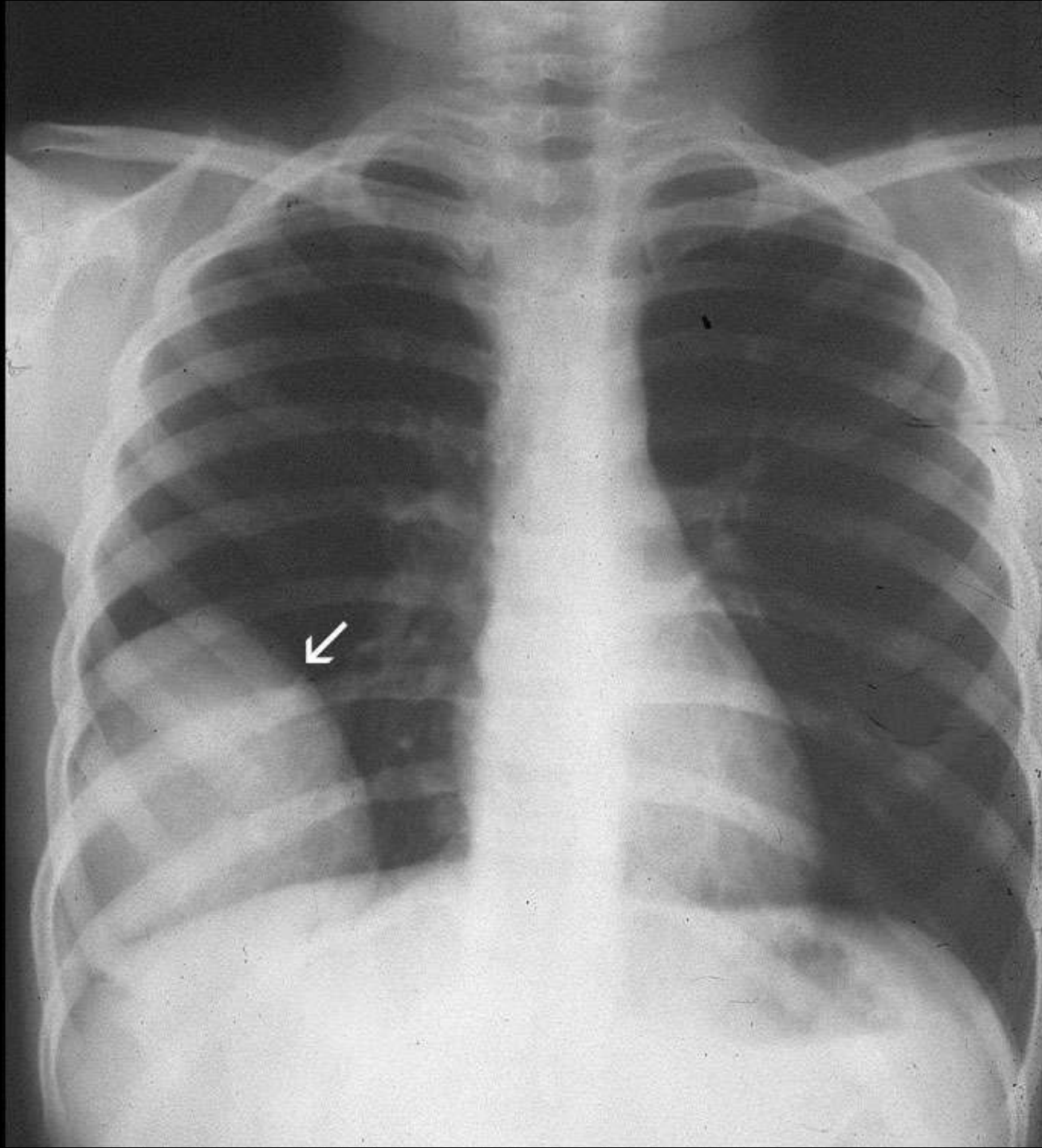




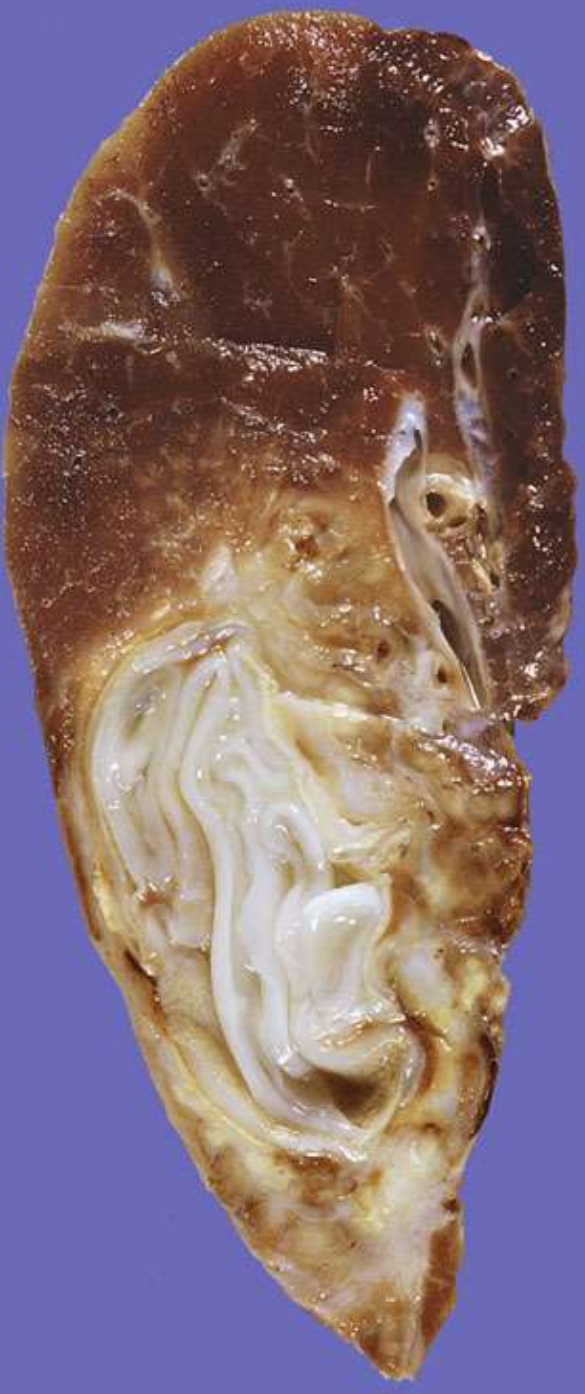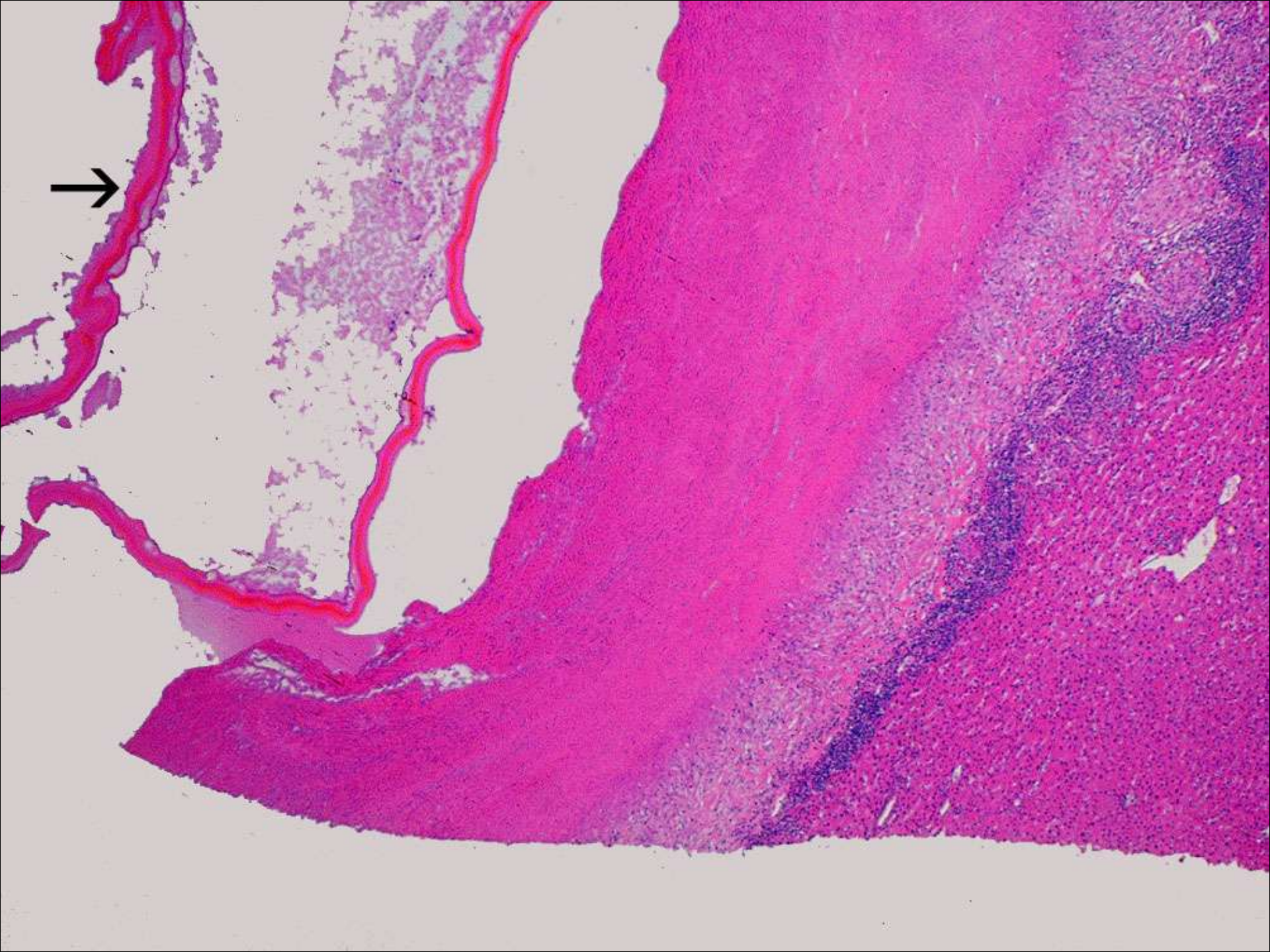







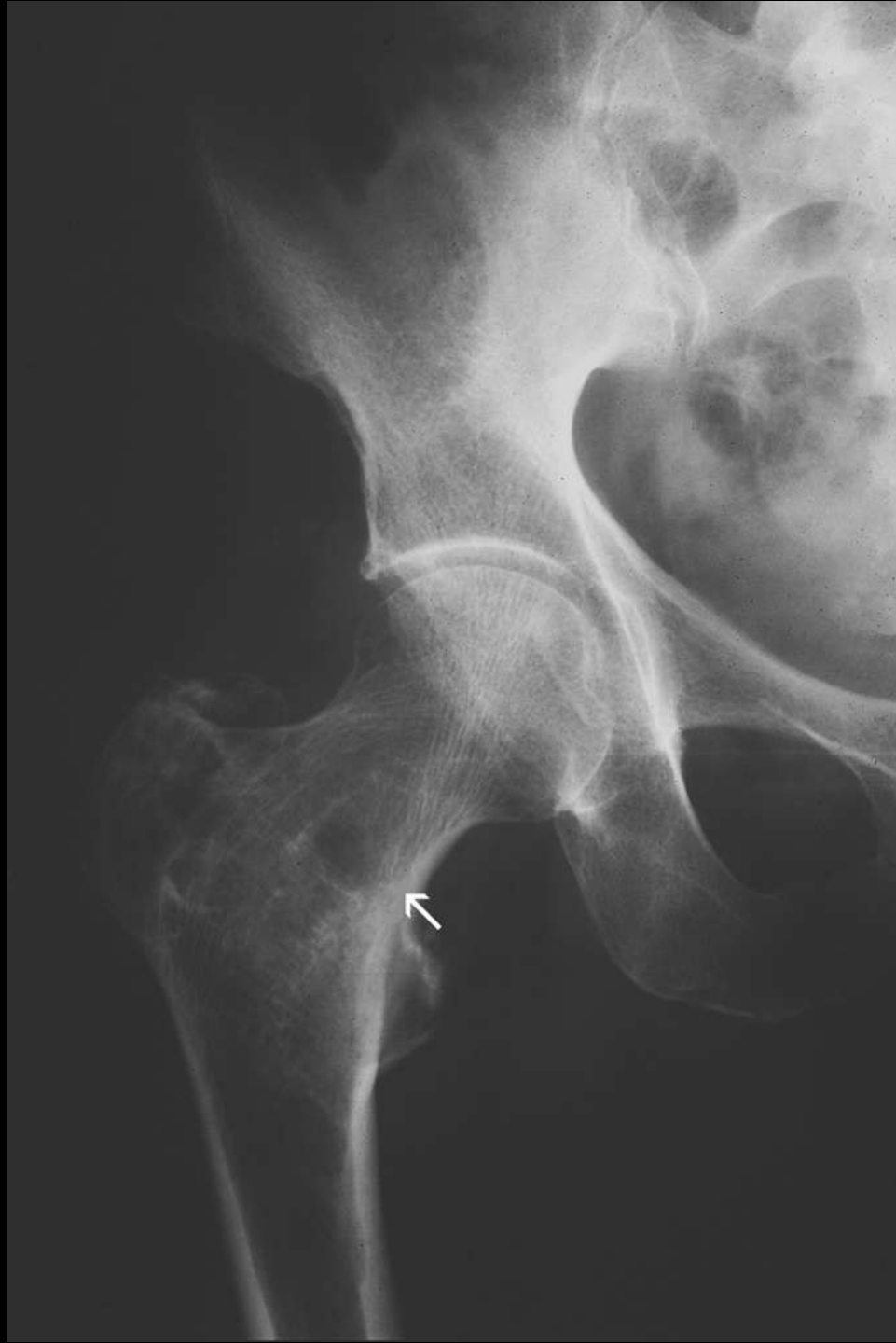


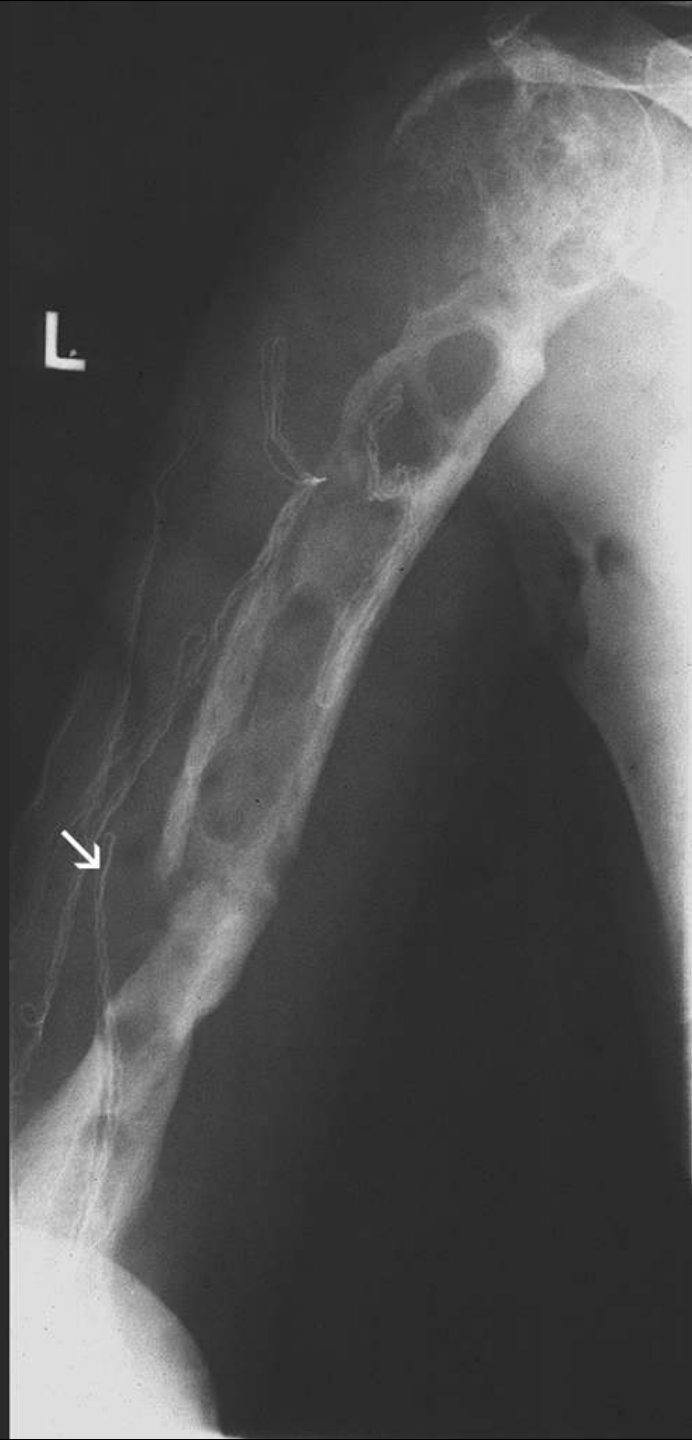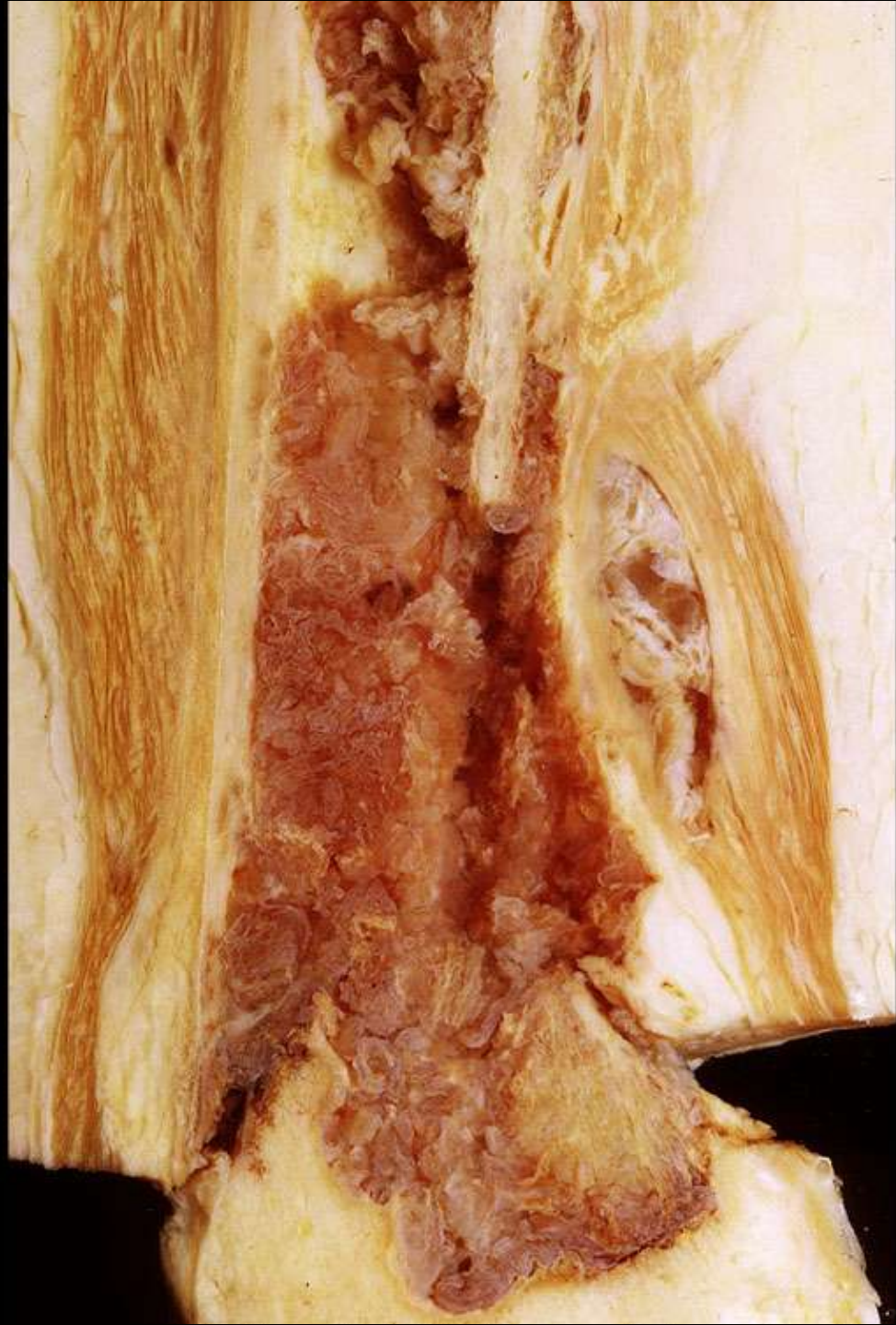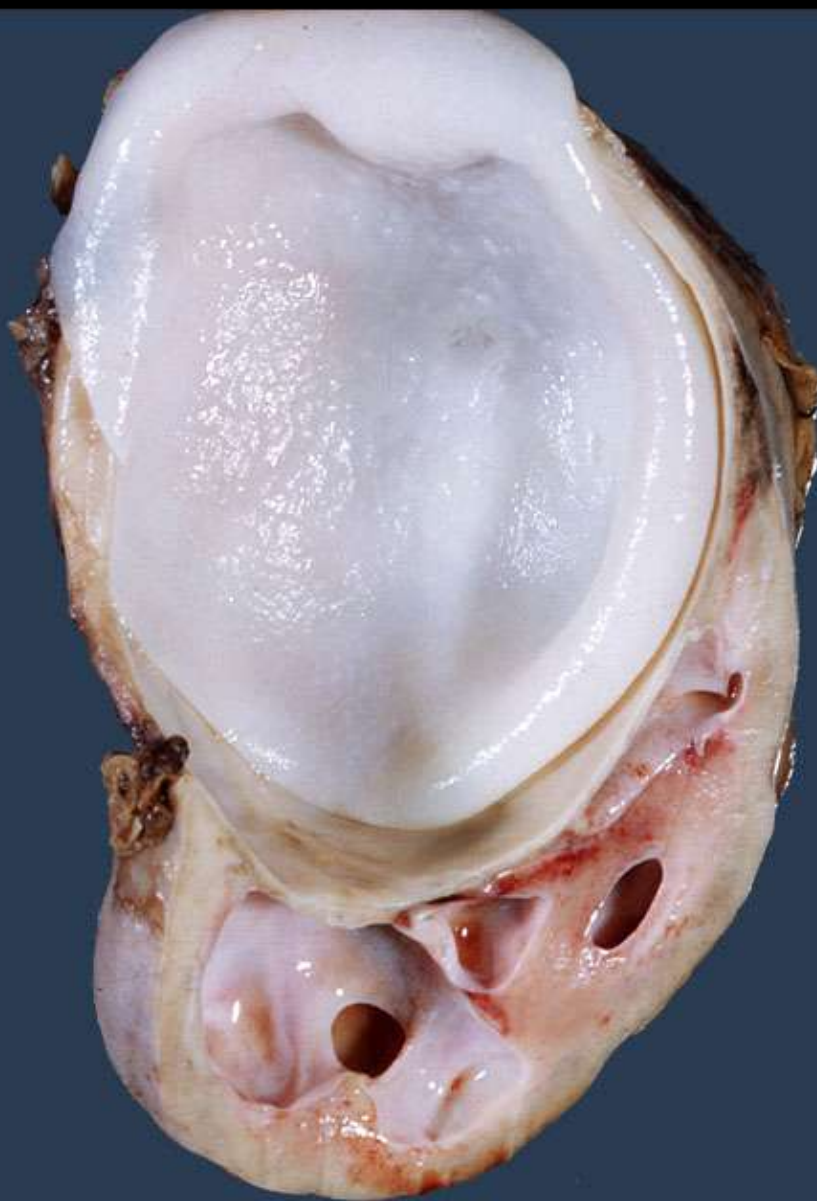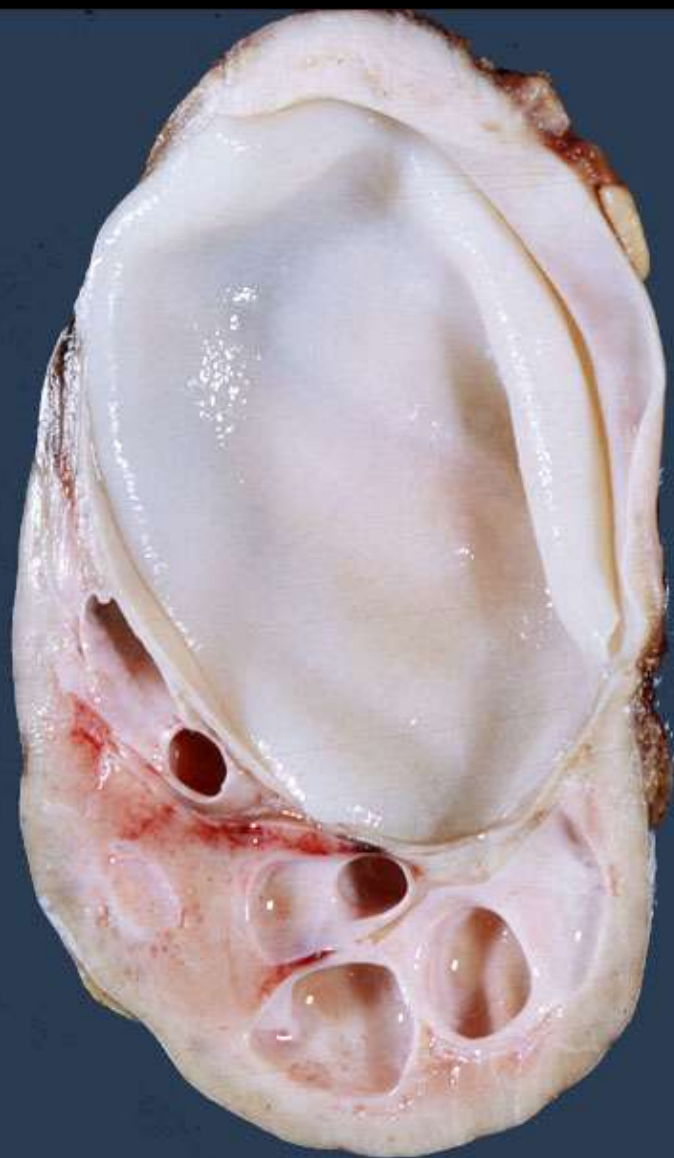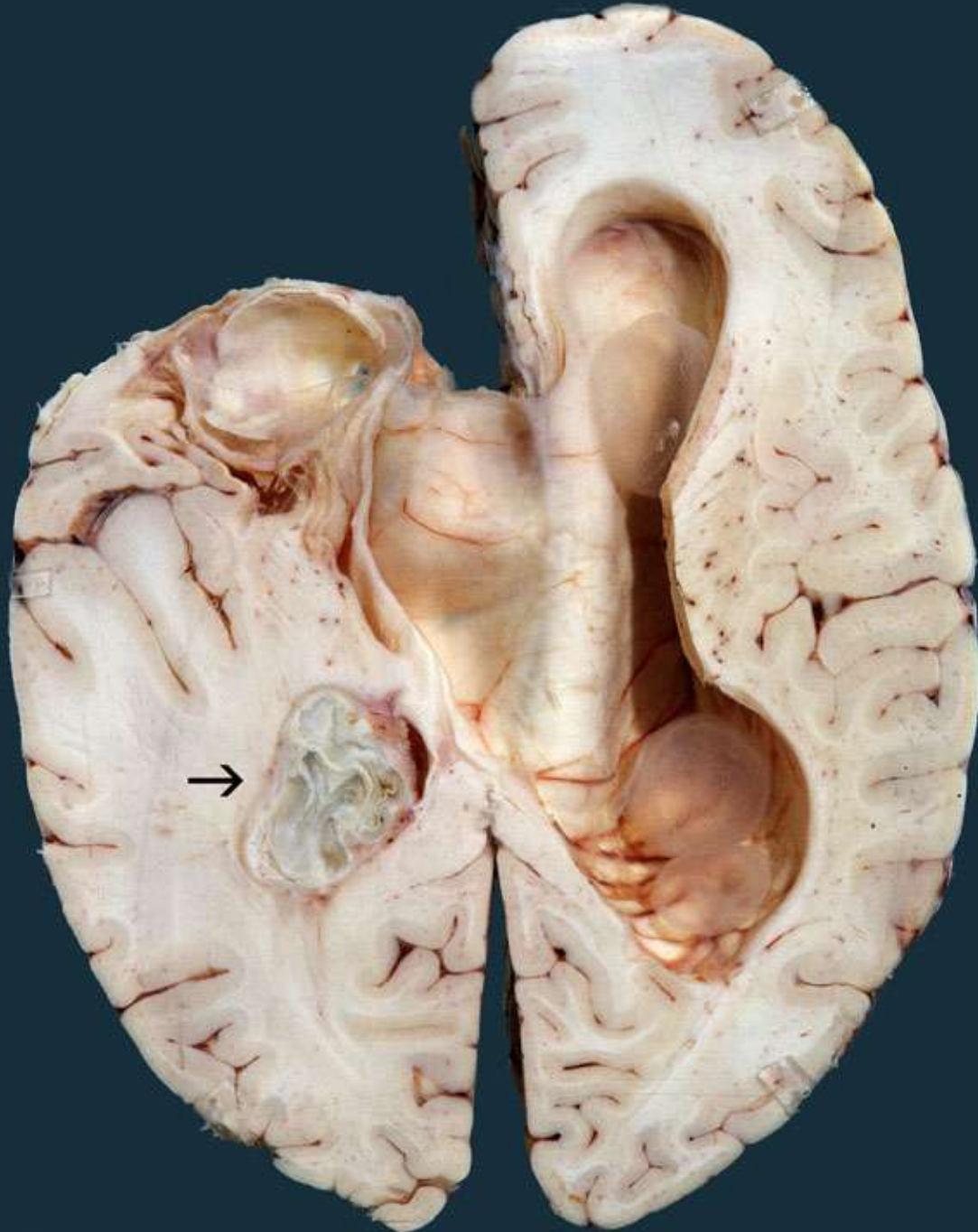












M 29 presented with a swelling of his right thigh in August 2009.

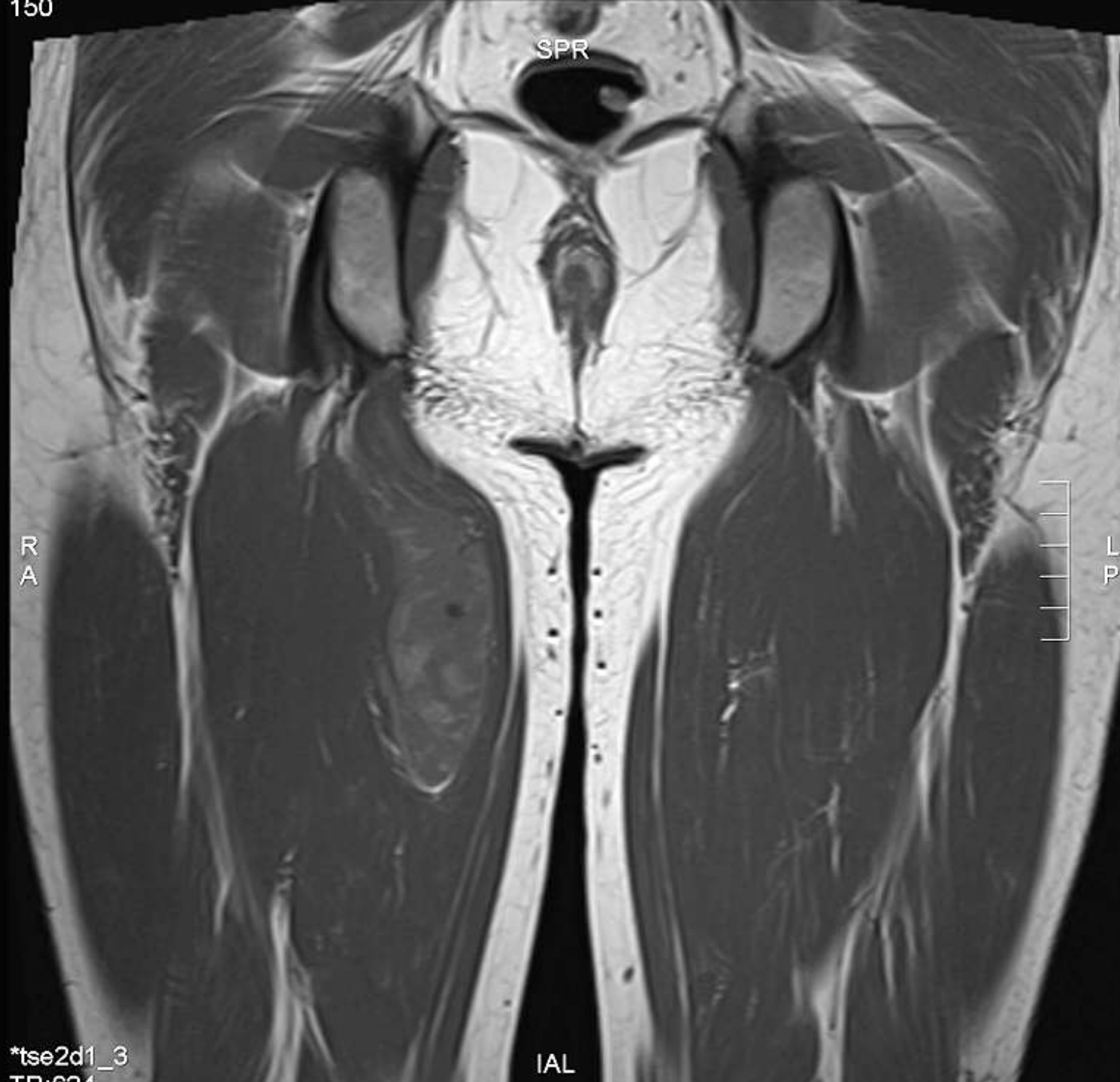CT showed a lesion in the upper portion of his quadriceps femoris muscle.

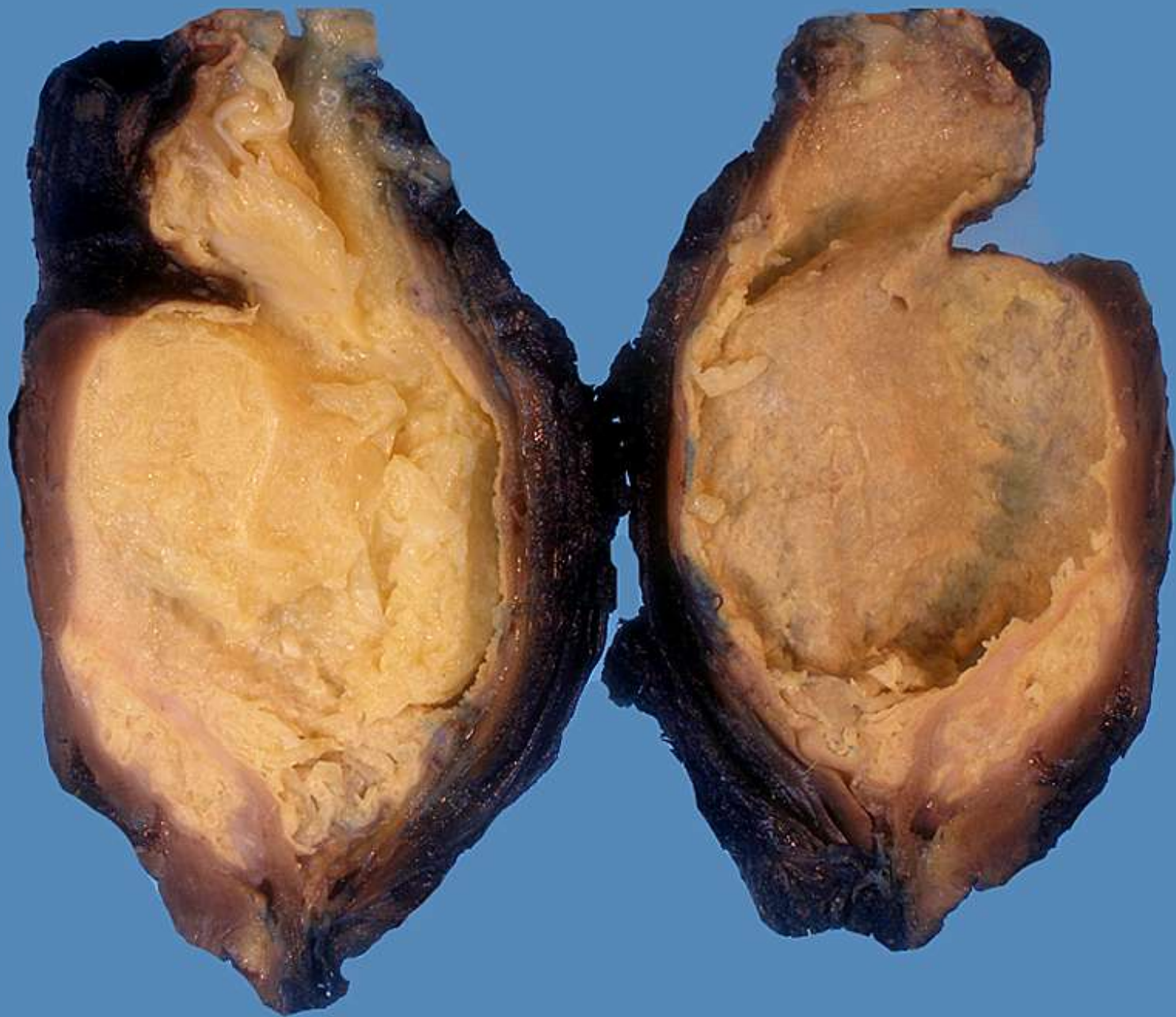The clinical diagnosis was hydatid cyst and he was given a course of albendazole before it was excised.

No serology was performed.

He was a ceramic tiler and had been in Australia for 8 years.

He was brought up on a sheep farm in a small village in Croatia.





C.M.E.

Pathology

Robin Cooke

