

Micosis que simulan tumores



DR. *CLÓVIS* KLOCK





Principali clinici
specializzati in:



Medina Diagnostica

(E)



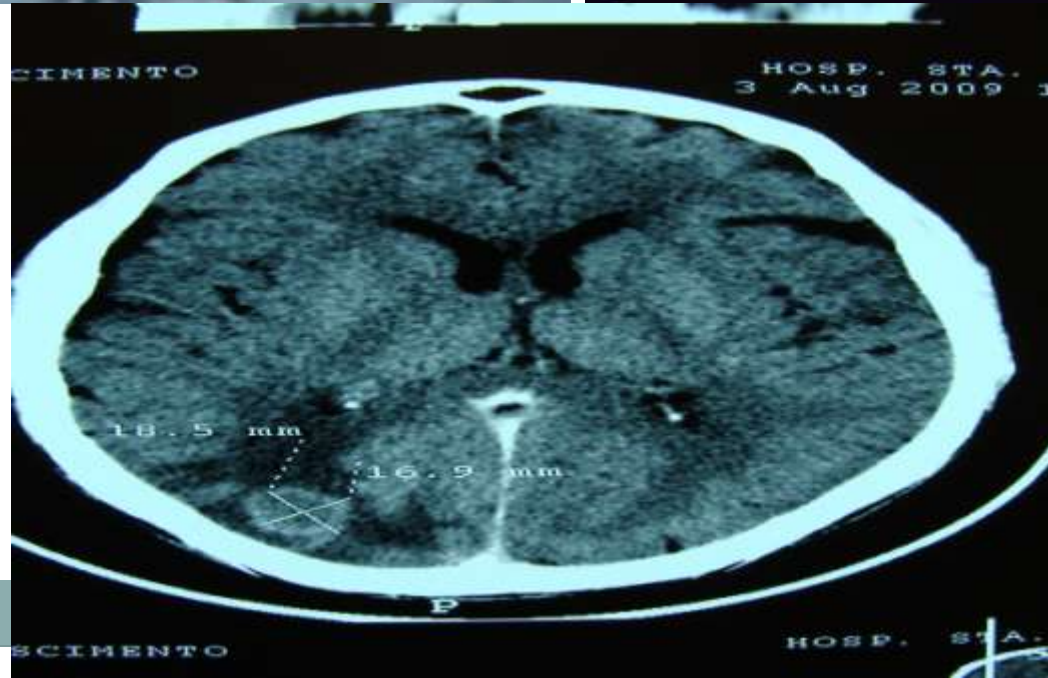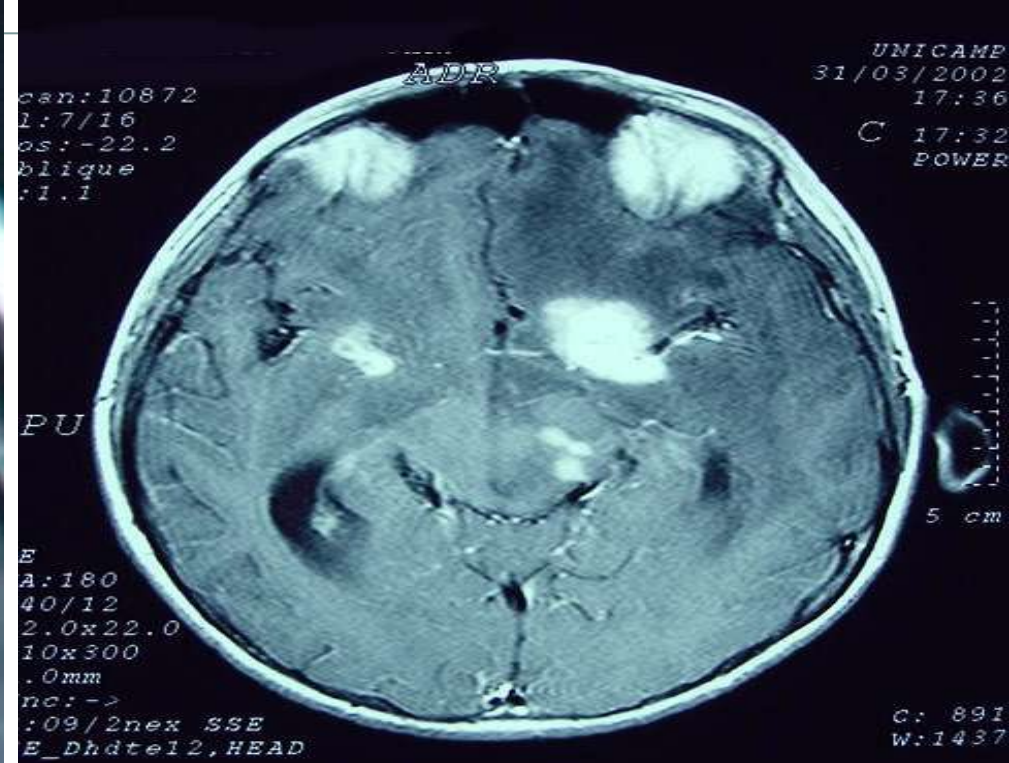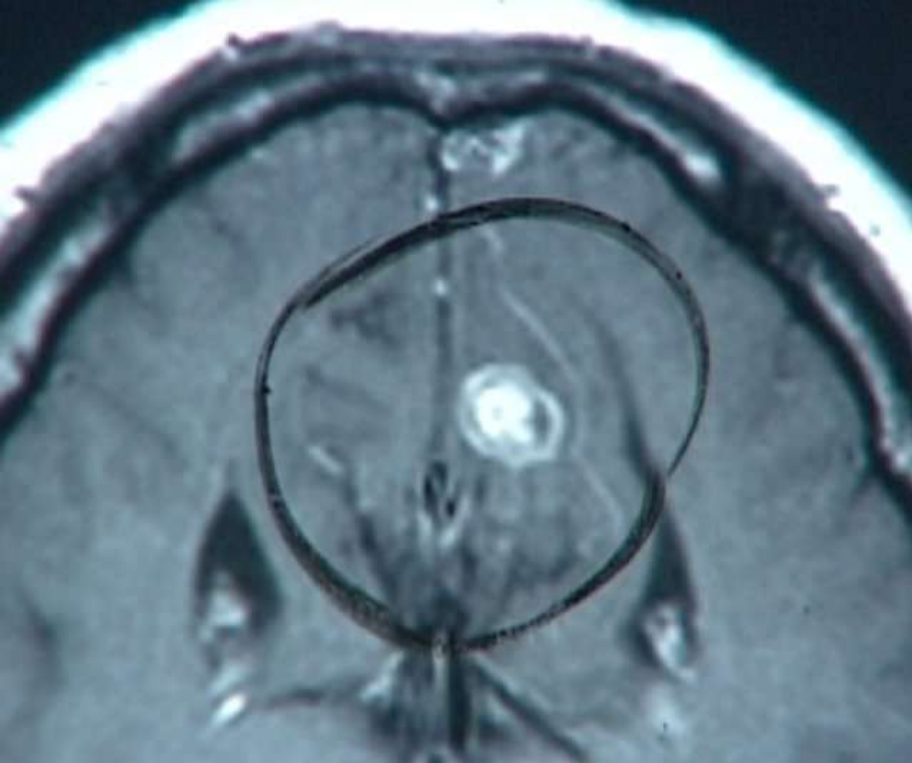




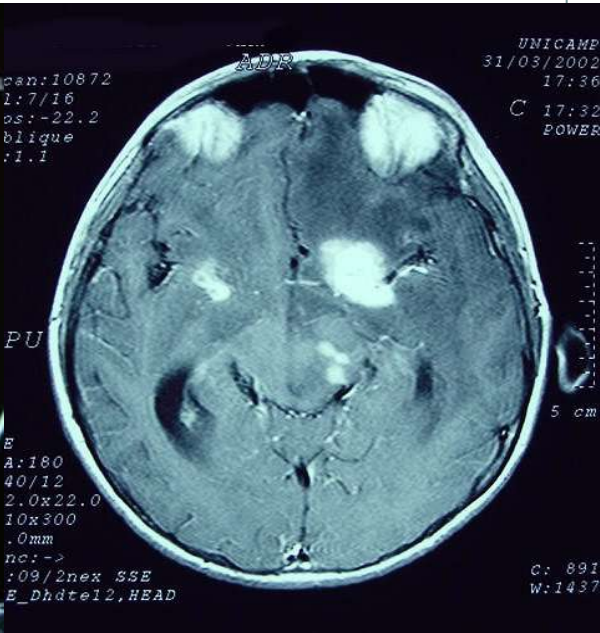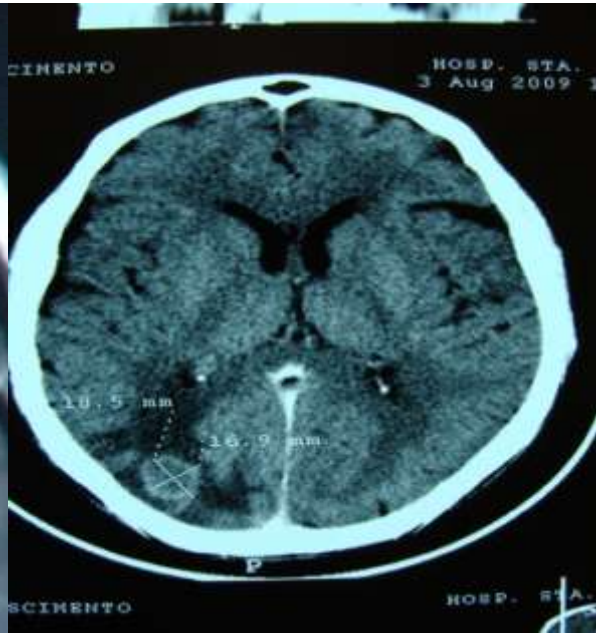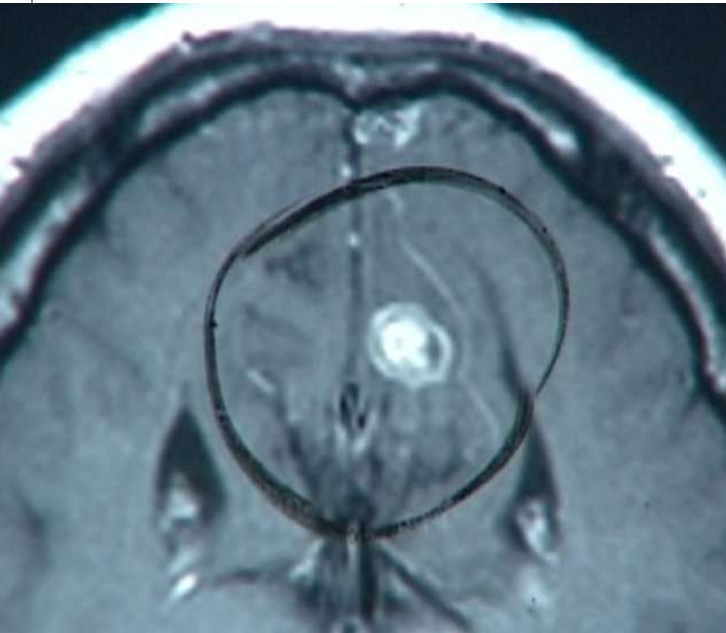





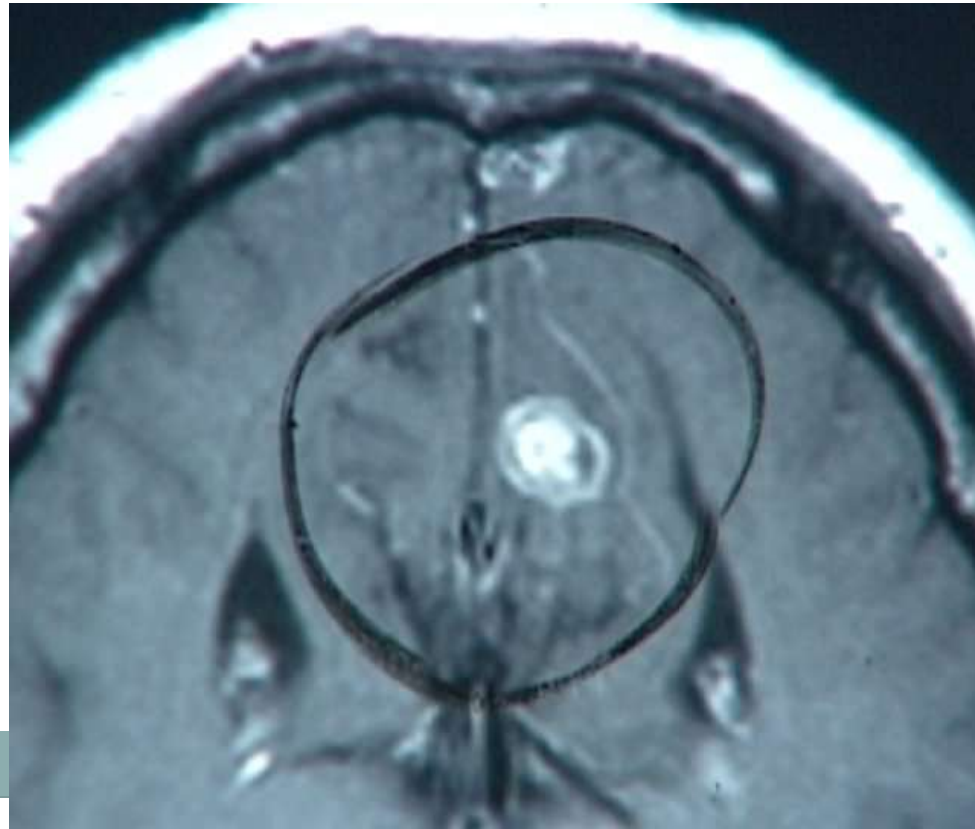
MICROSCÓPIO DA IDADE DA PEDRA







GLIOMA



Sistema Nervoso Central e Rinocerebral



- Cryptococcosis
- *Paracoccidioidomycosis*
- Histoplasmosis
- Aspergillosis
- Zigomycosis
- Infecções mistas

can:10872
l:7/16
os:-22.2
bligue
:1.1

ADR

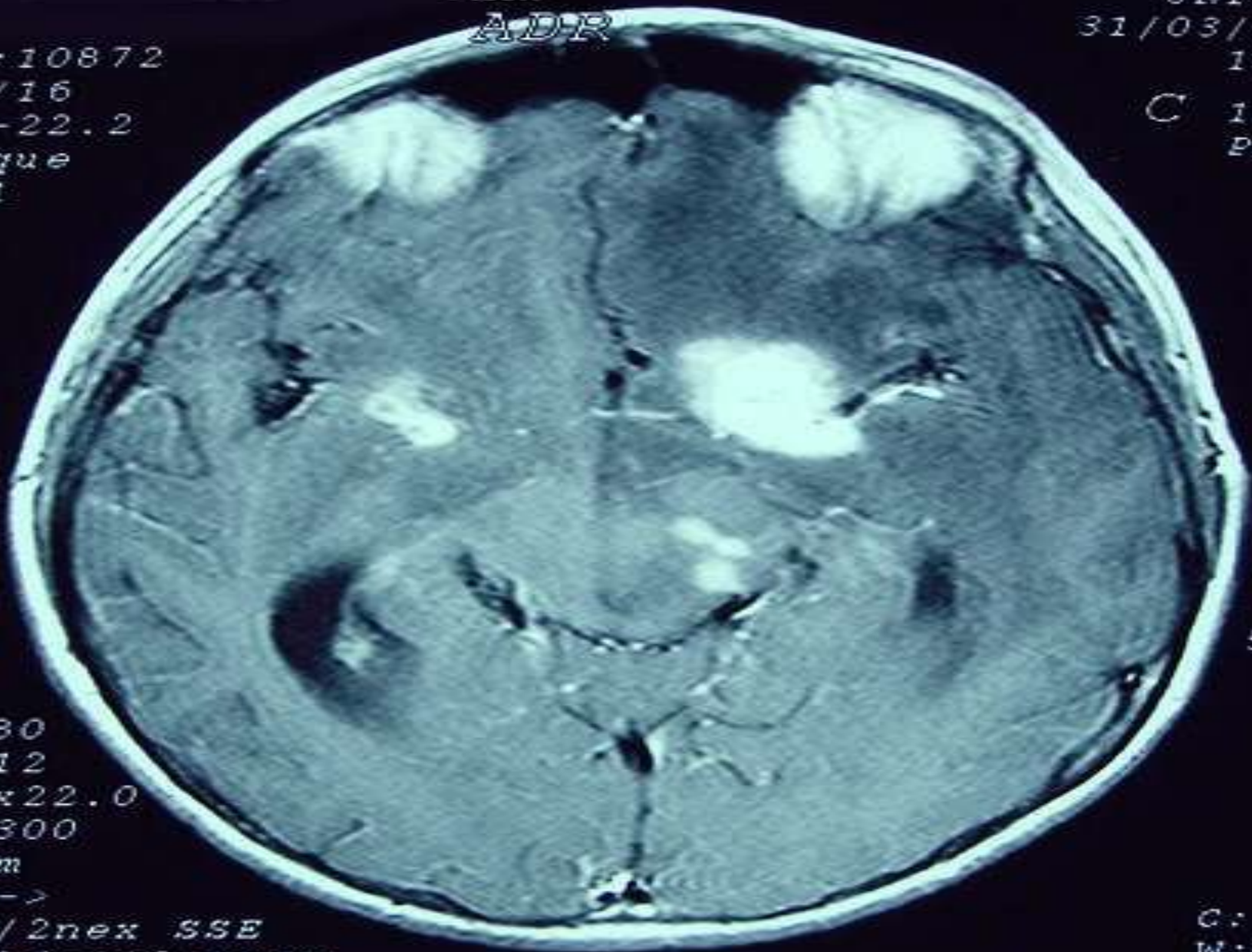
UNICAMP
31/03/2002
17:36
C 17:32
POWER

PU

E
A:180
40/12
2.0x22.0
10x300
.0mm
nc:->
:09/2nex SSE
E_Dhdte12,HEAD



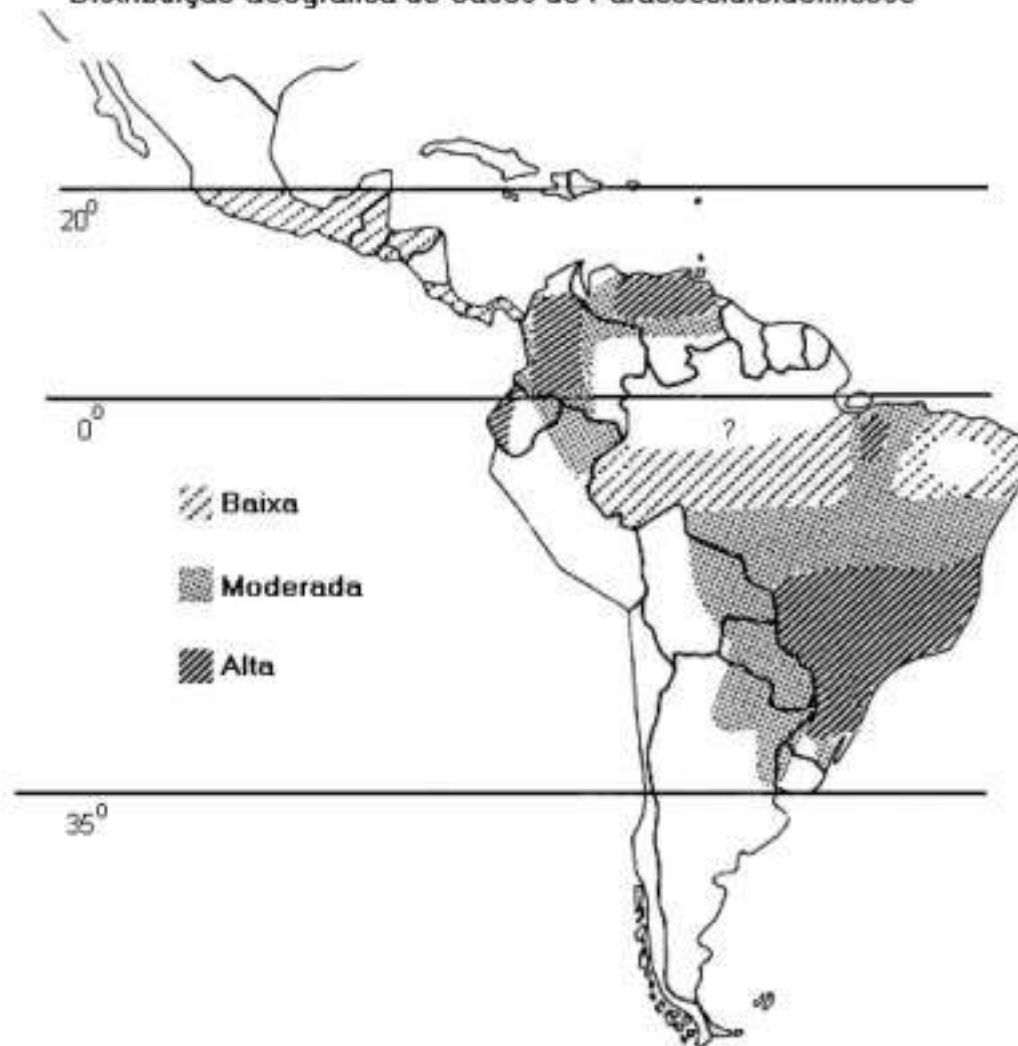
C: 891
W:1437



PARACOCCIDIODOMICOSIS



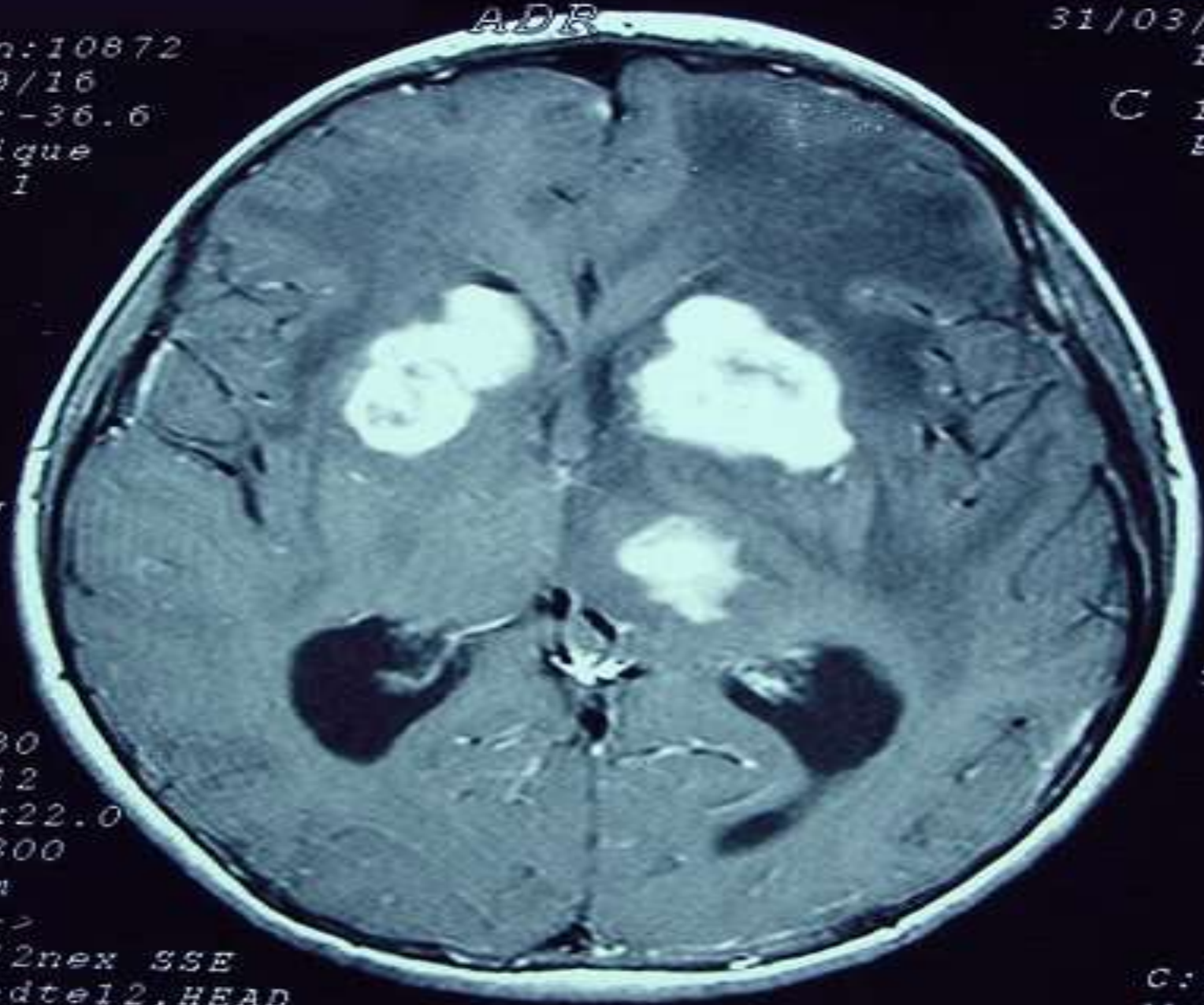Distribuição Geográfica de Casos de Paracoccidioidomicose



ADR

UNICAMP
31/03/2002
17:36
C 17:32
POWER

Scan: 10872
S1: 9/16
Pos: -36.6
Oblique
Z: 1.1



RPU



SE
TA: 180
540/12
22.0x22.0
210x300
6.0mm
Enc: ->
2:09/2nex SSE
SE_Dhdte12, HEAD

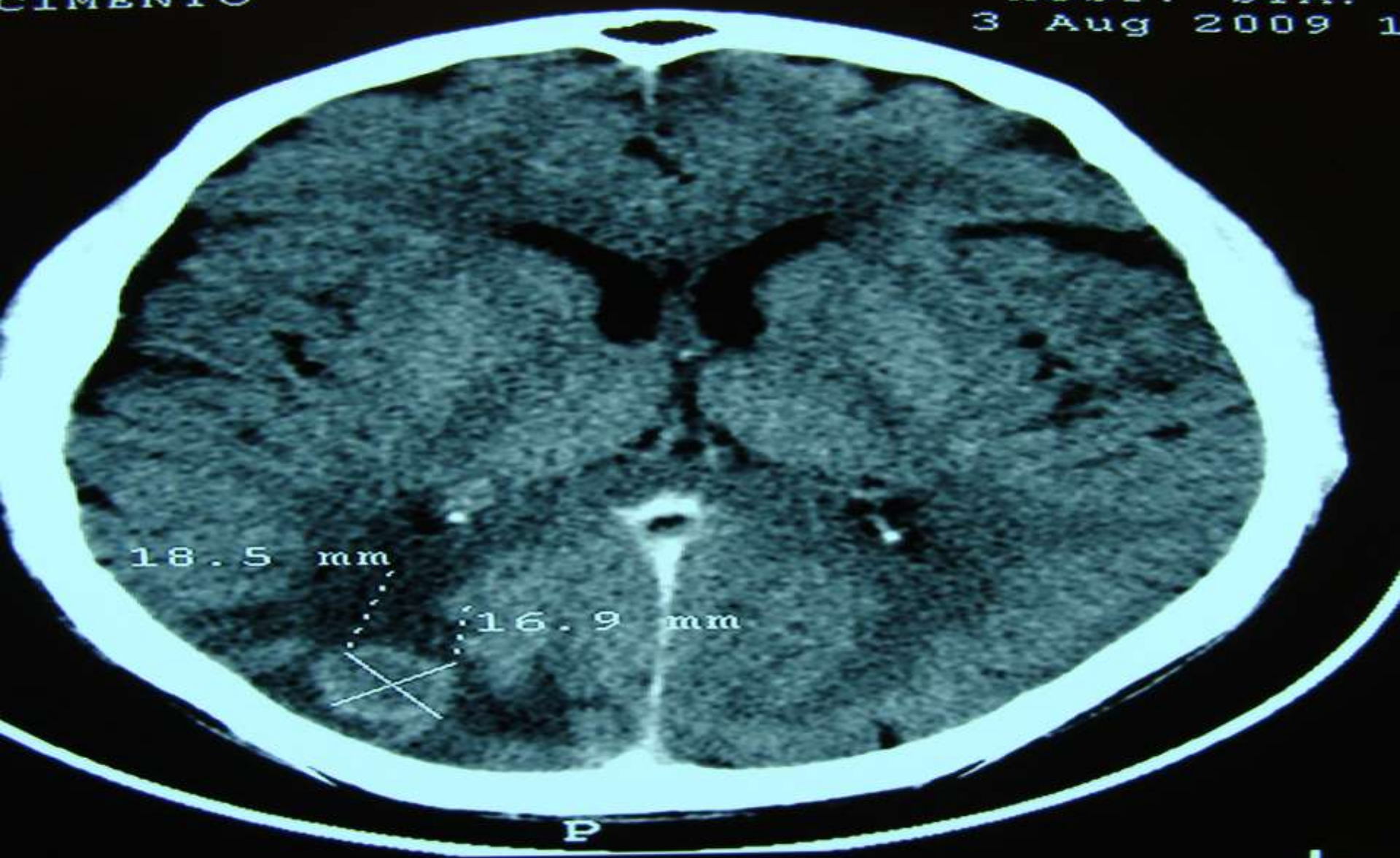
C: 1053
W: 1926



04/06/2009 08:11

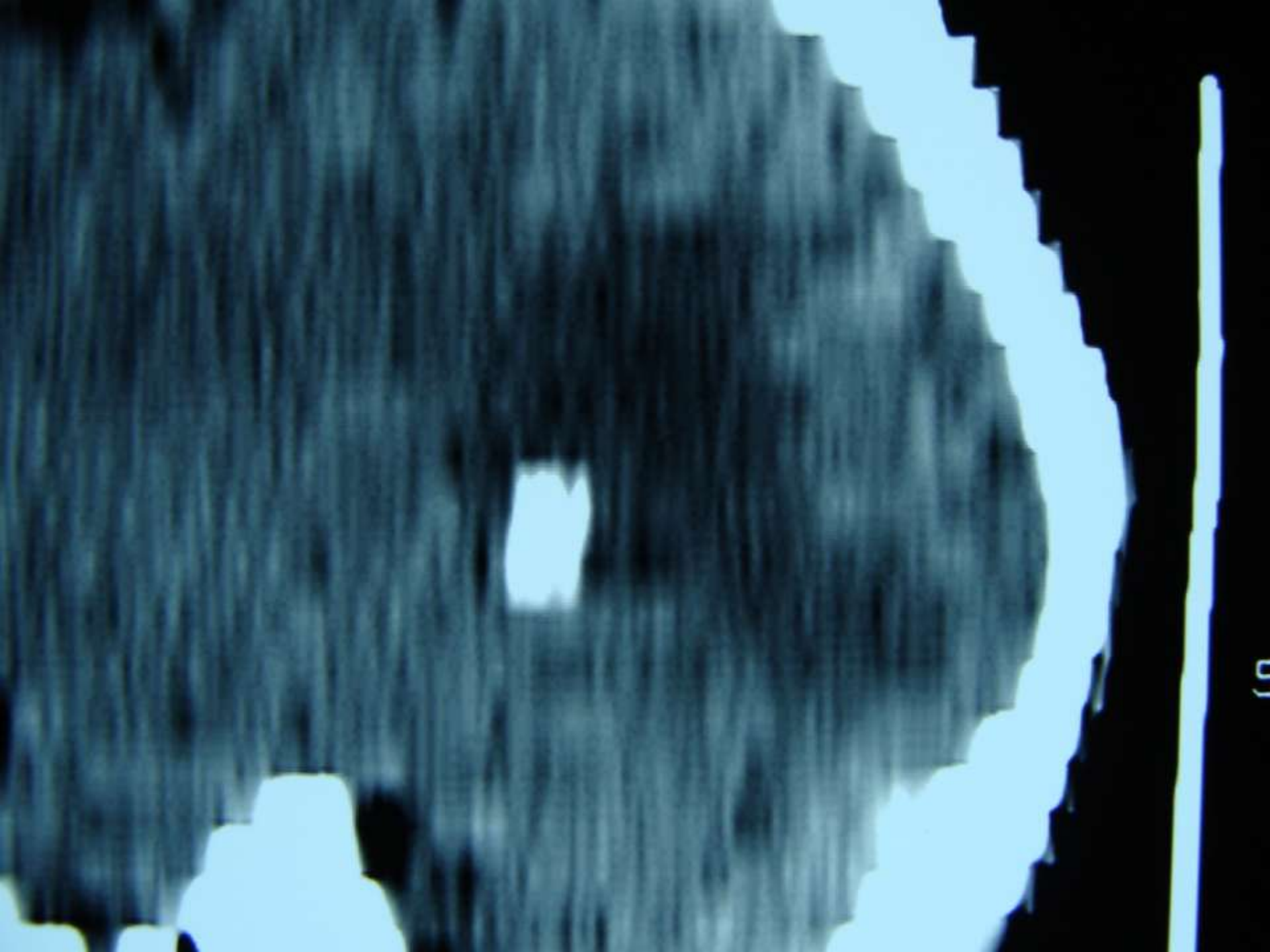
CIMENTO

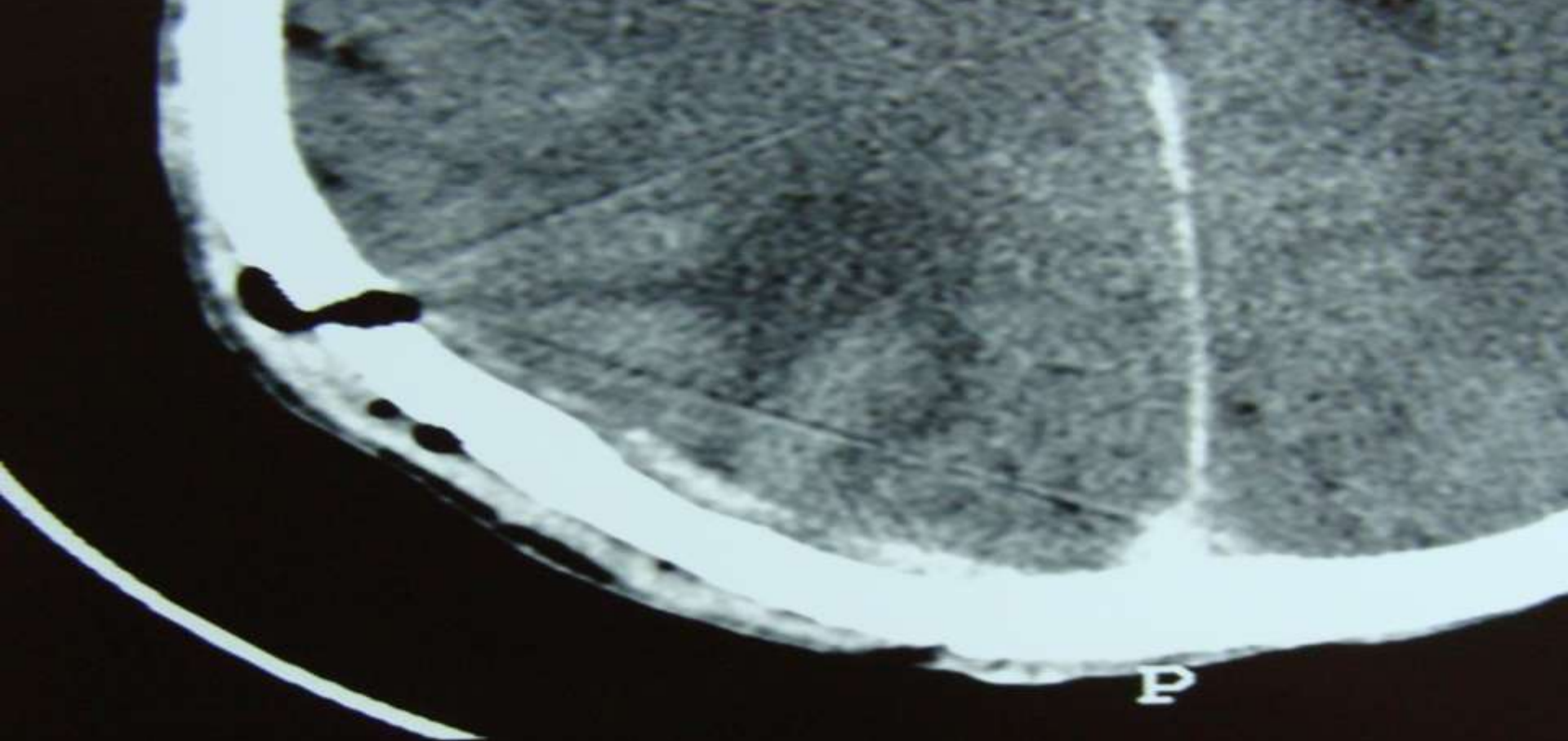
HOSP. STA.
3 Aug 2009 1



SCIMENTO

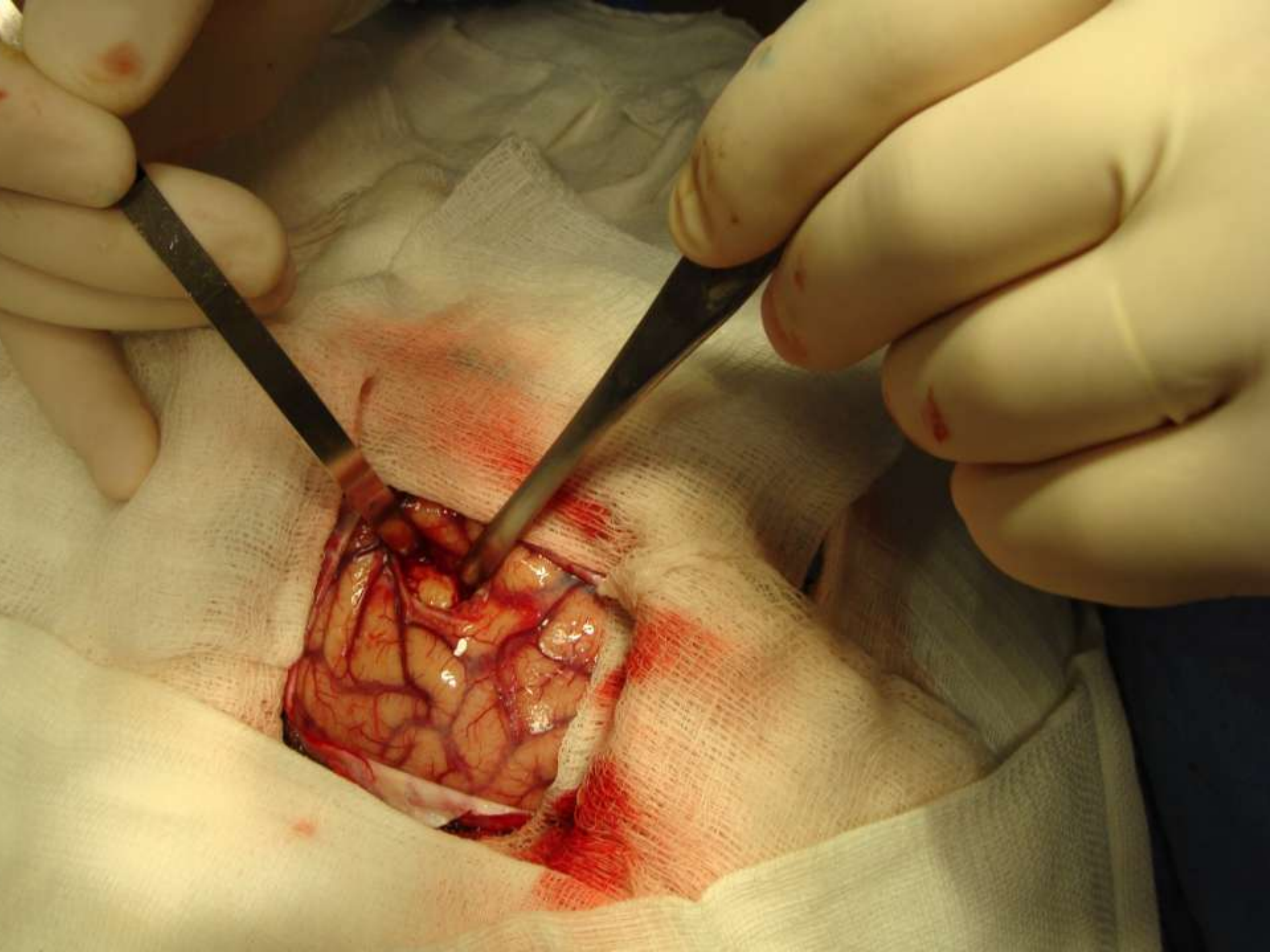
HOSP. STA.
3

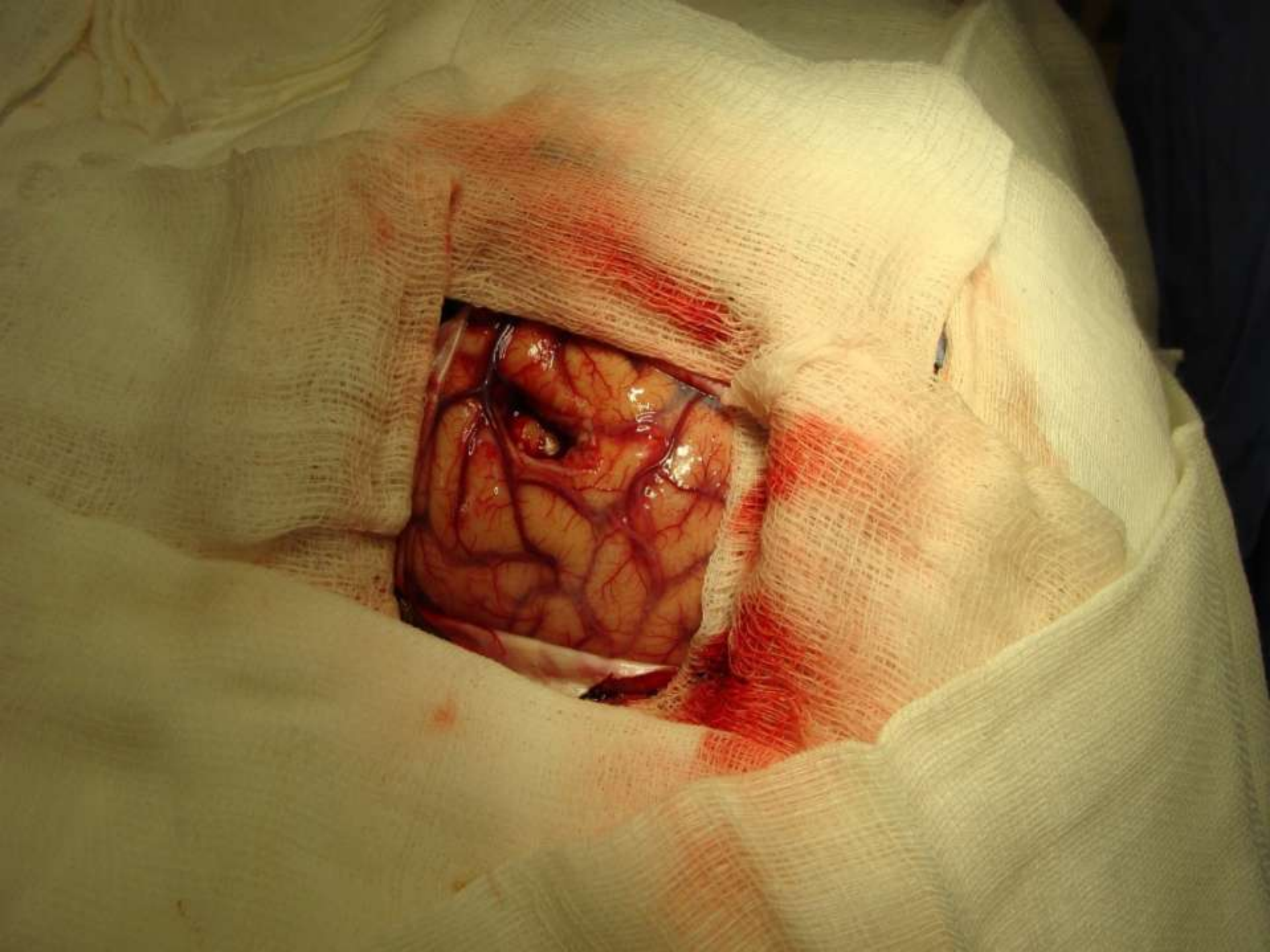


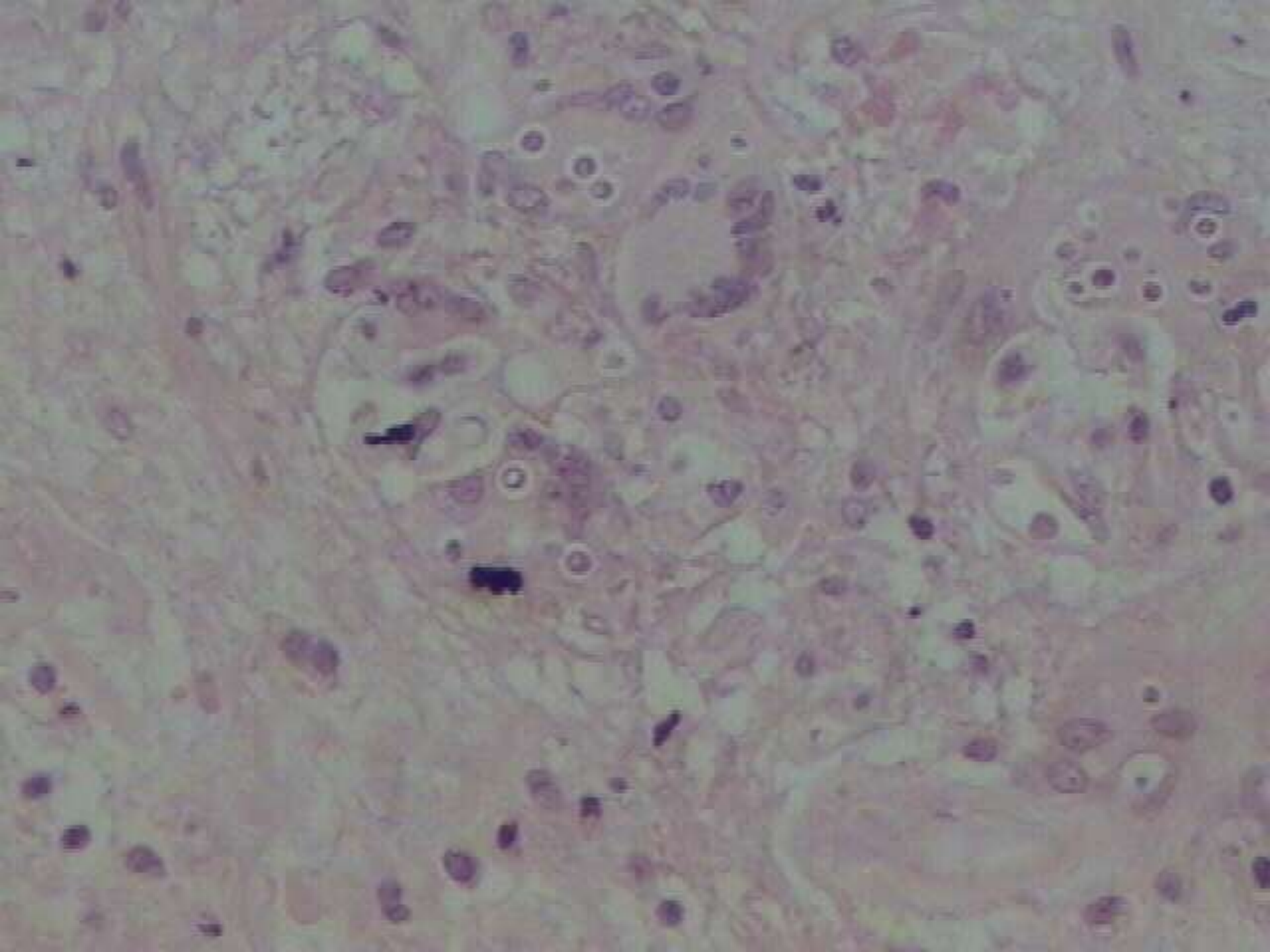


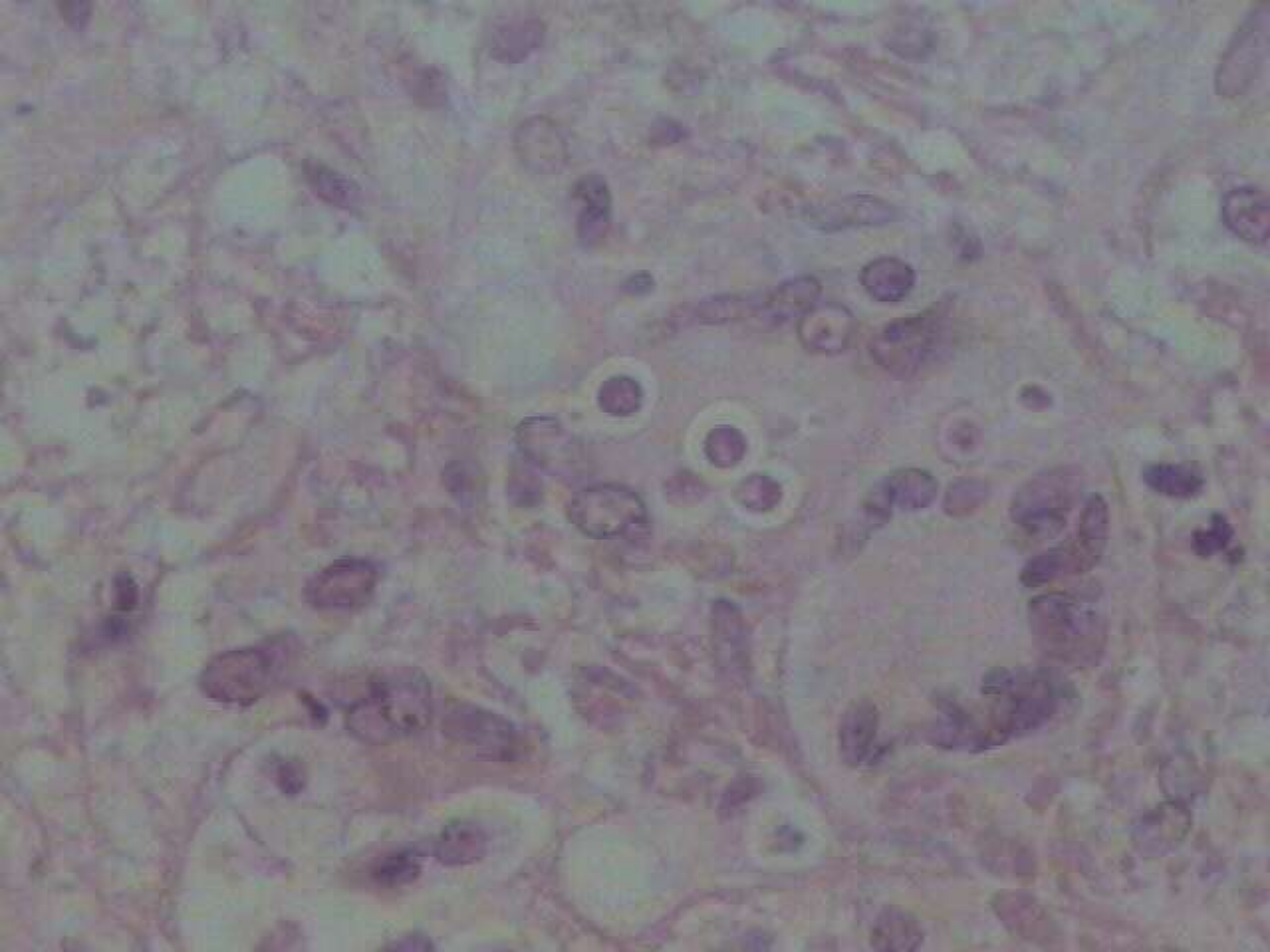
P

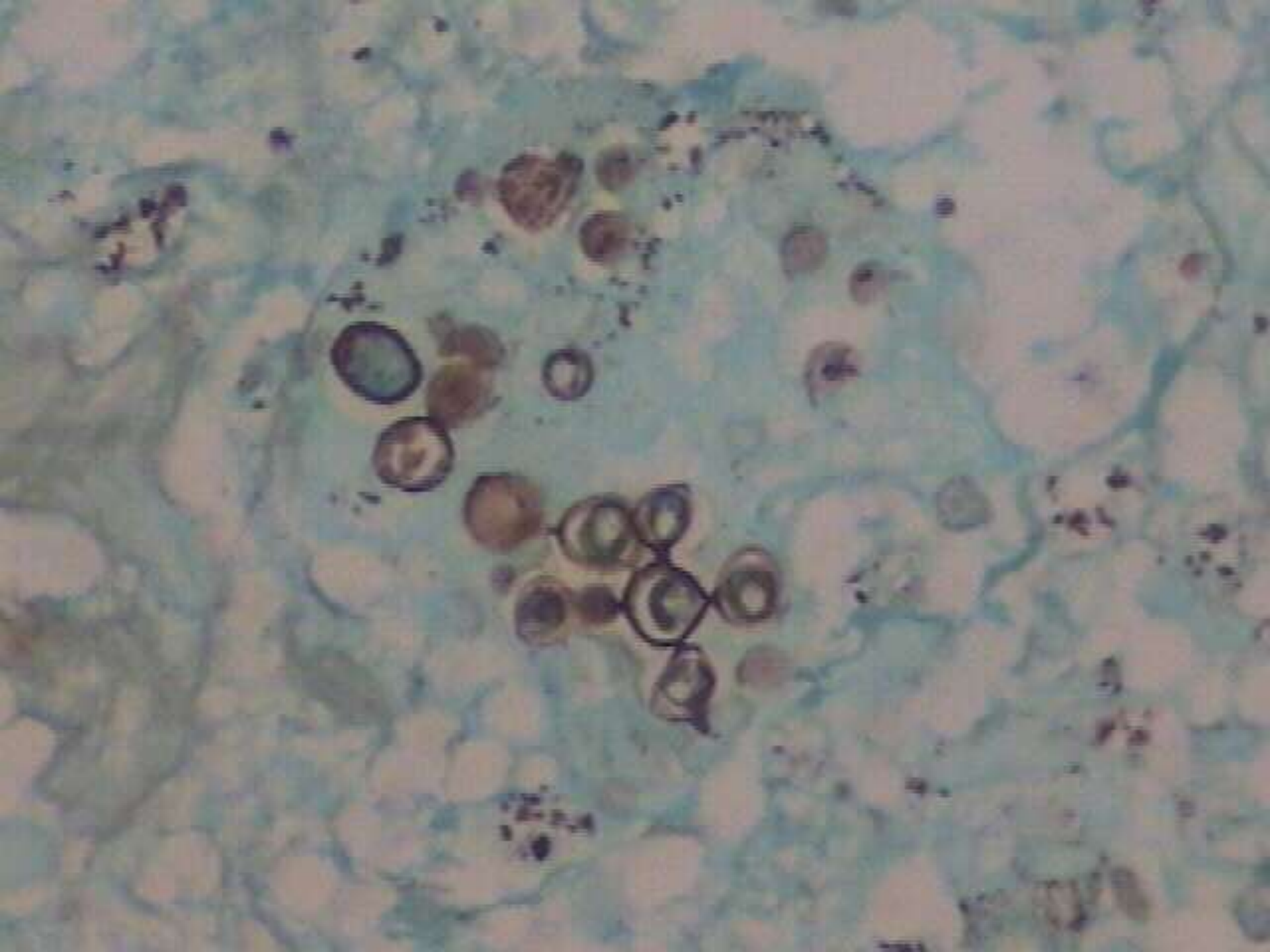ANTONIO P. DO NASCIMENTO S.
ST09249 M/66y 10 Aug
4534-23 C/CONTRASTE

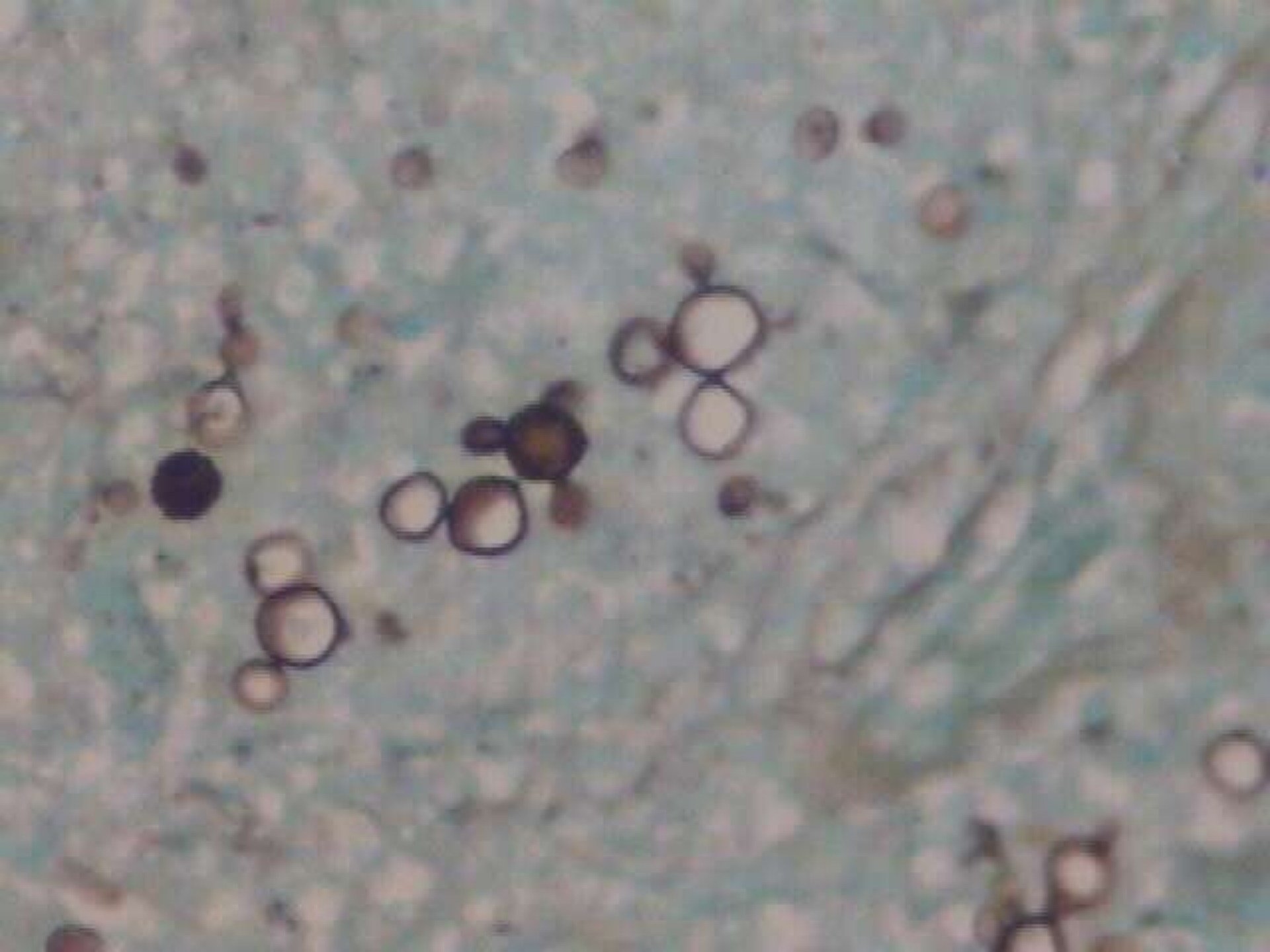












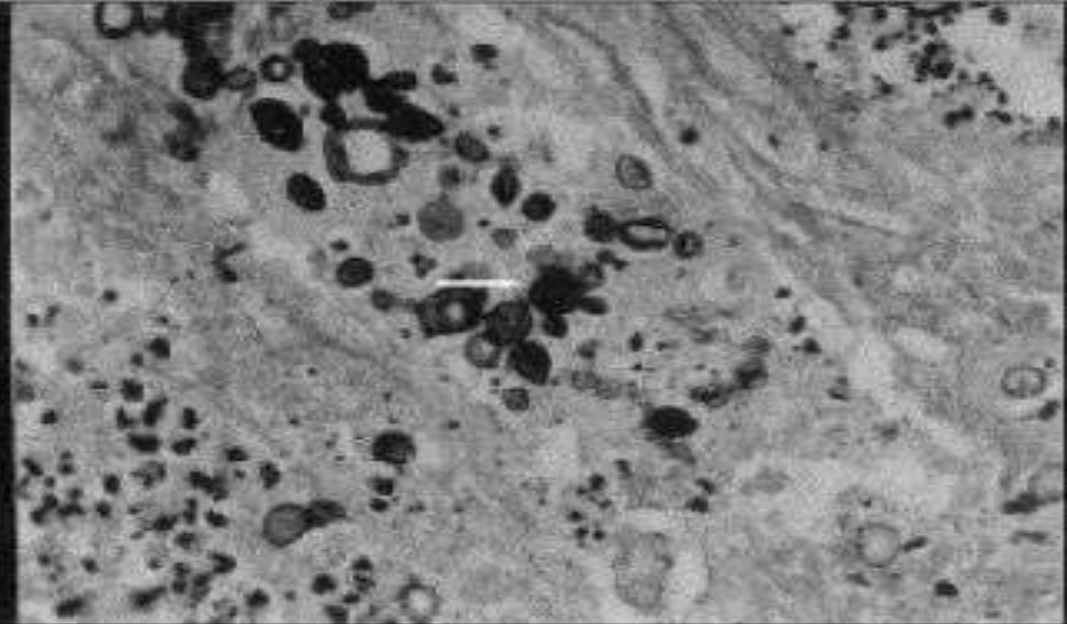
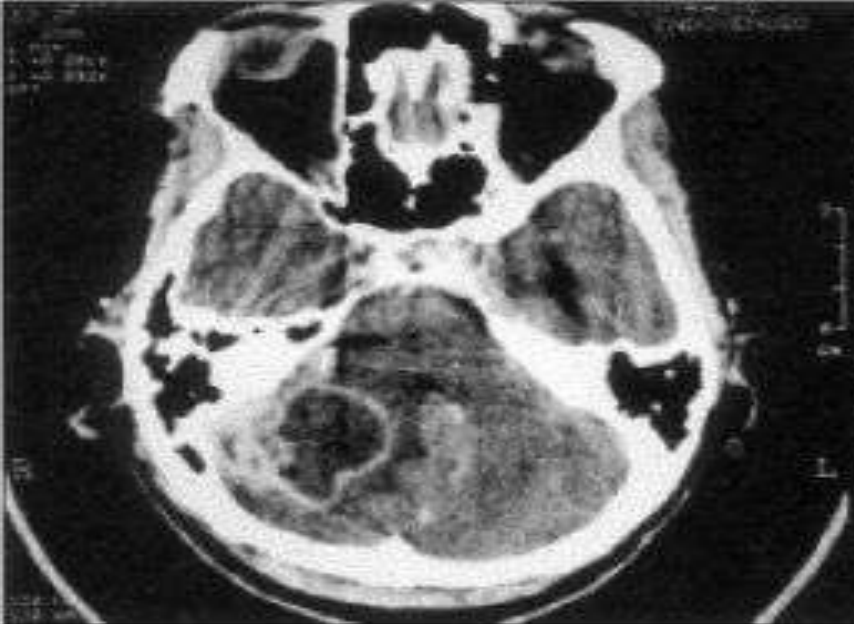

Fig 2A. Tomografia computadorizada de crânio revelando lesão hipodensa com captação anelar de contraste no hemisfério cerebelar direito compatível com abscesso cerebelar. B - Fotomicrografia do material obtido após intervenção cirúrgica e estudo anátomo-patológico, coloração H-E. Presença de leveduras em gemulação múltipla compatíveis com *Paracoccidioides brasiliensis* (300 X).

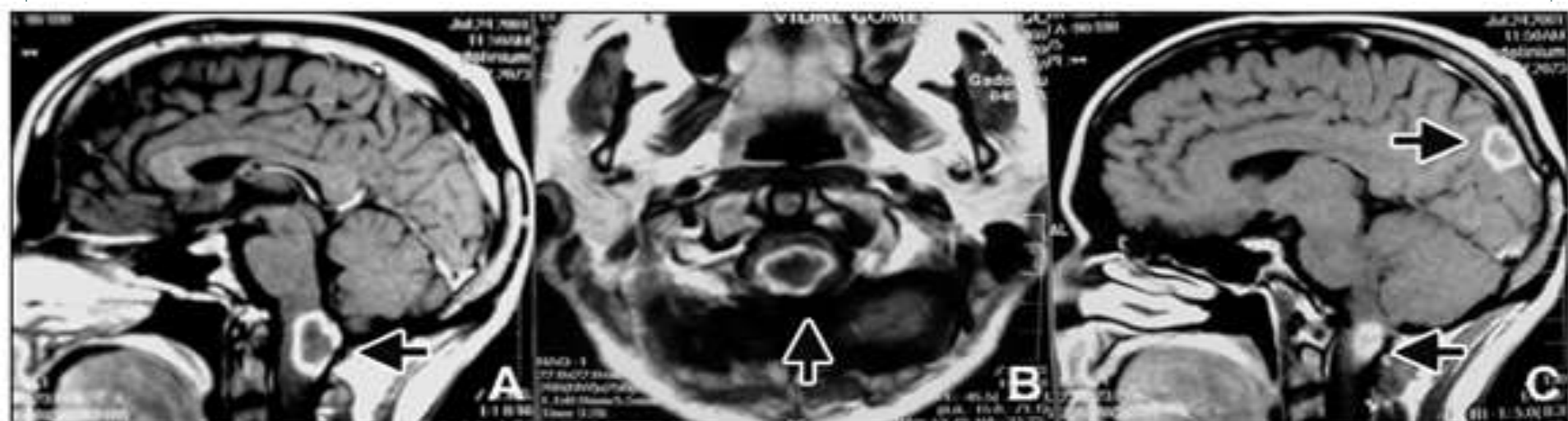
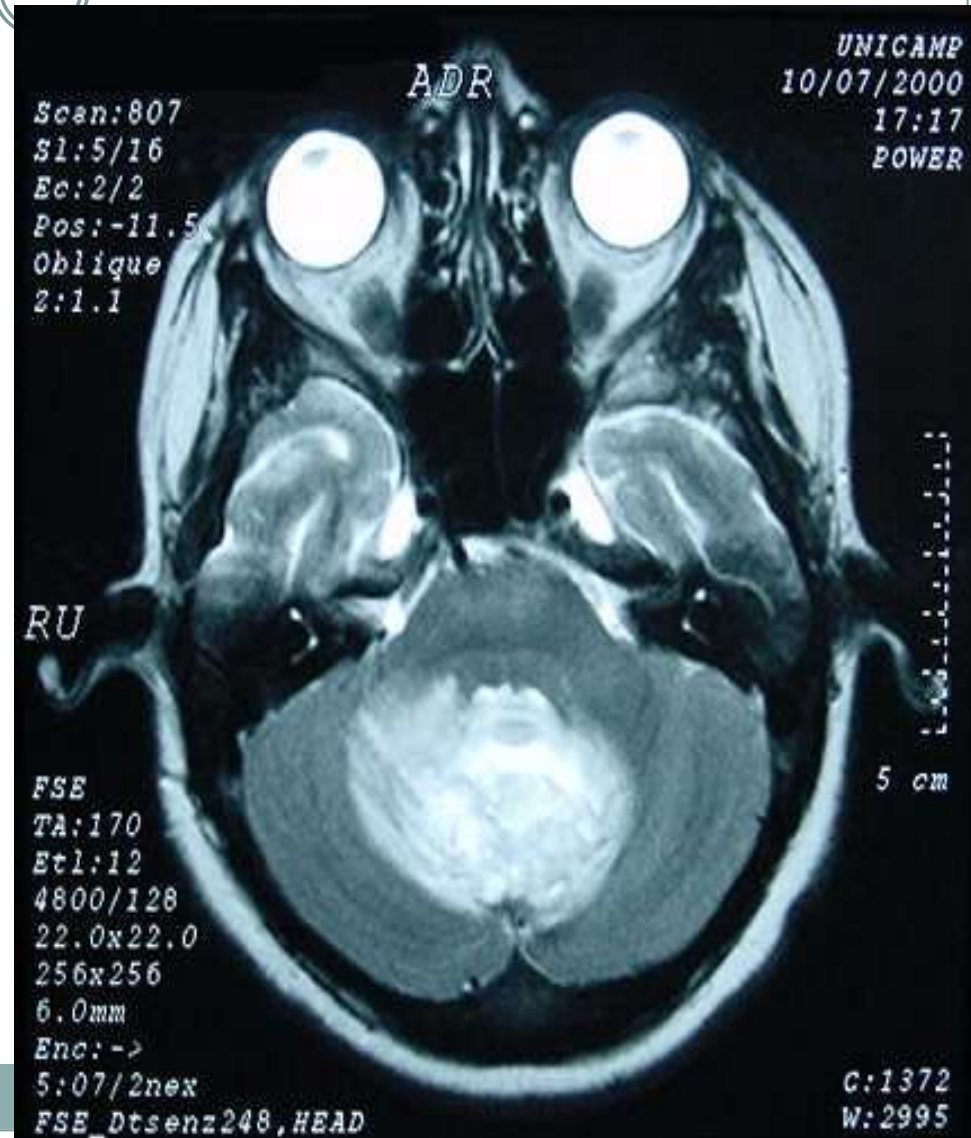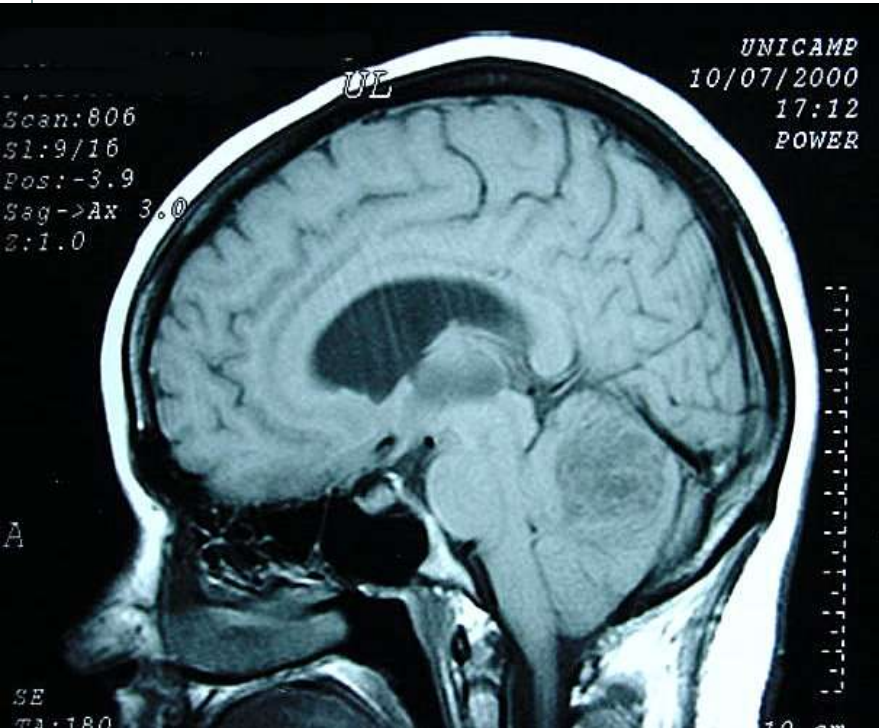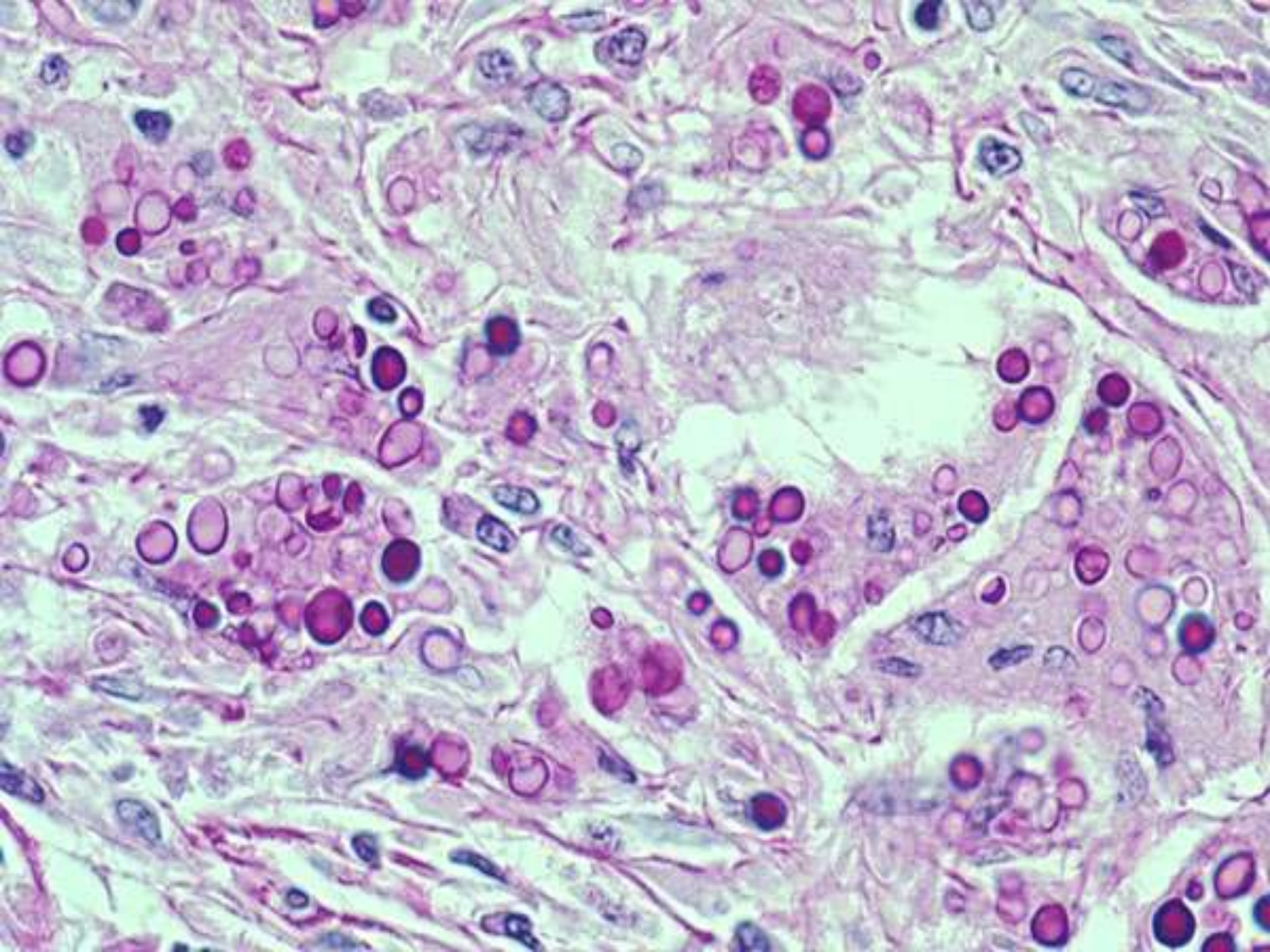


Fig 1. RM do encéfalo com imagens ponderadas em T1 e contrastadas com gadolínio observando-se no corte sagital (A) e axial (B) a lesão do bulbo e no corte para-sagital direito a lesão parietoccipital e no bulbo (C).

CRYPTOCOCCOSIS

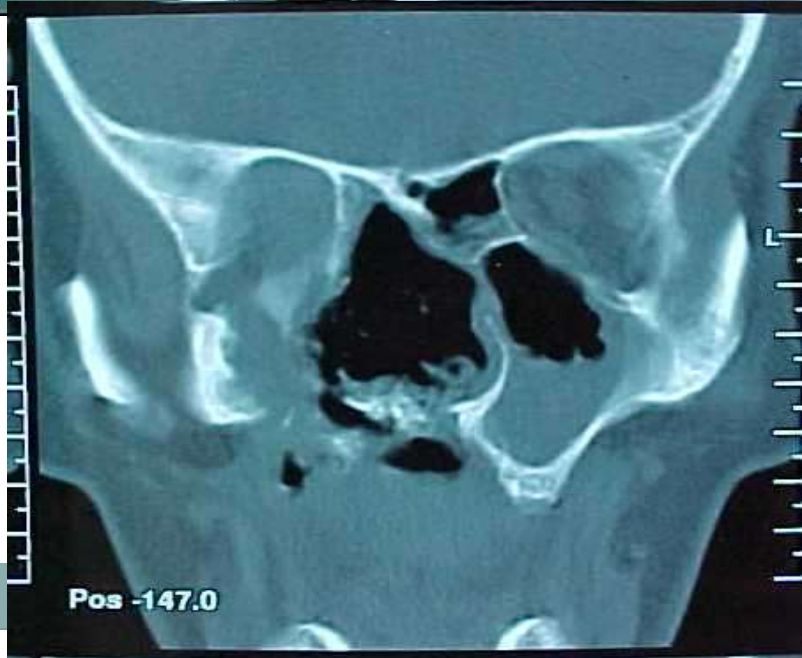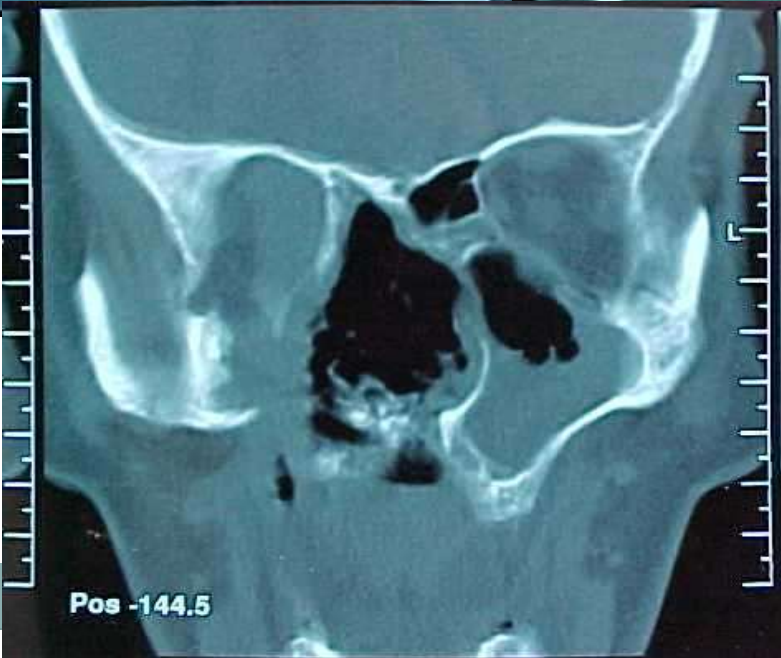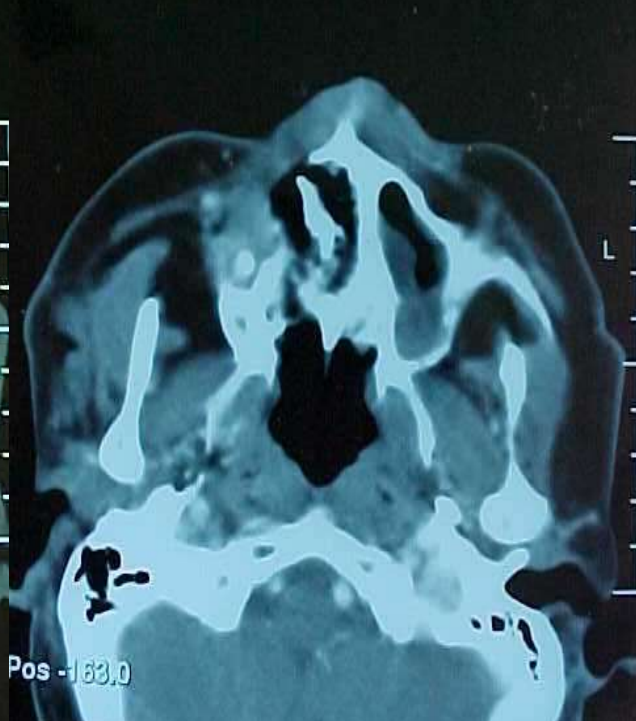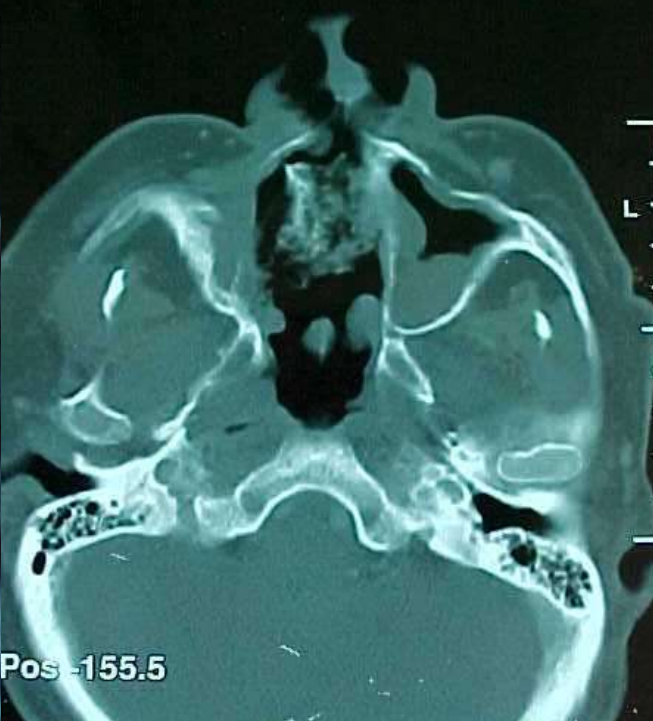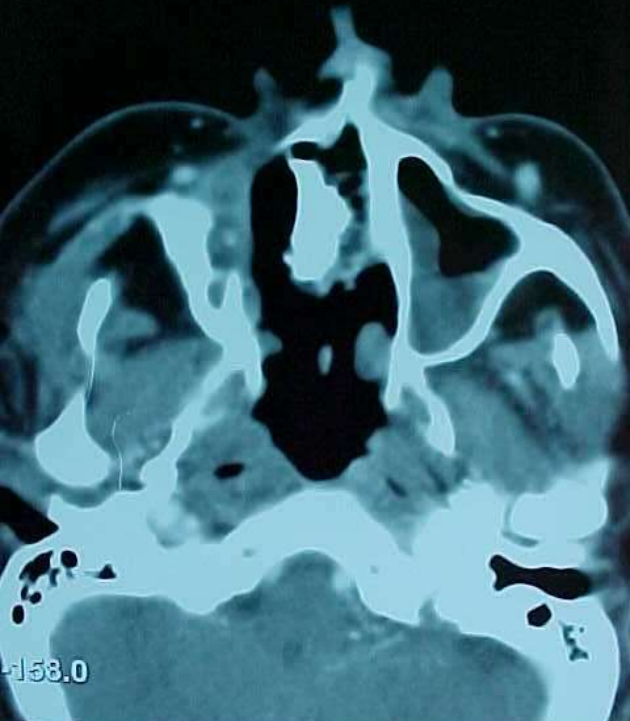






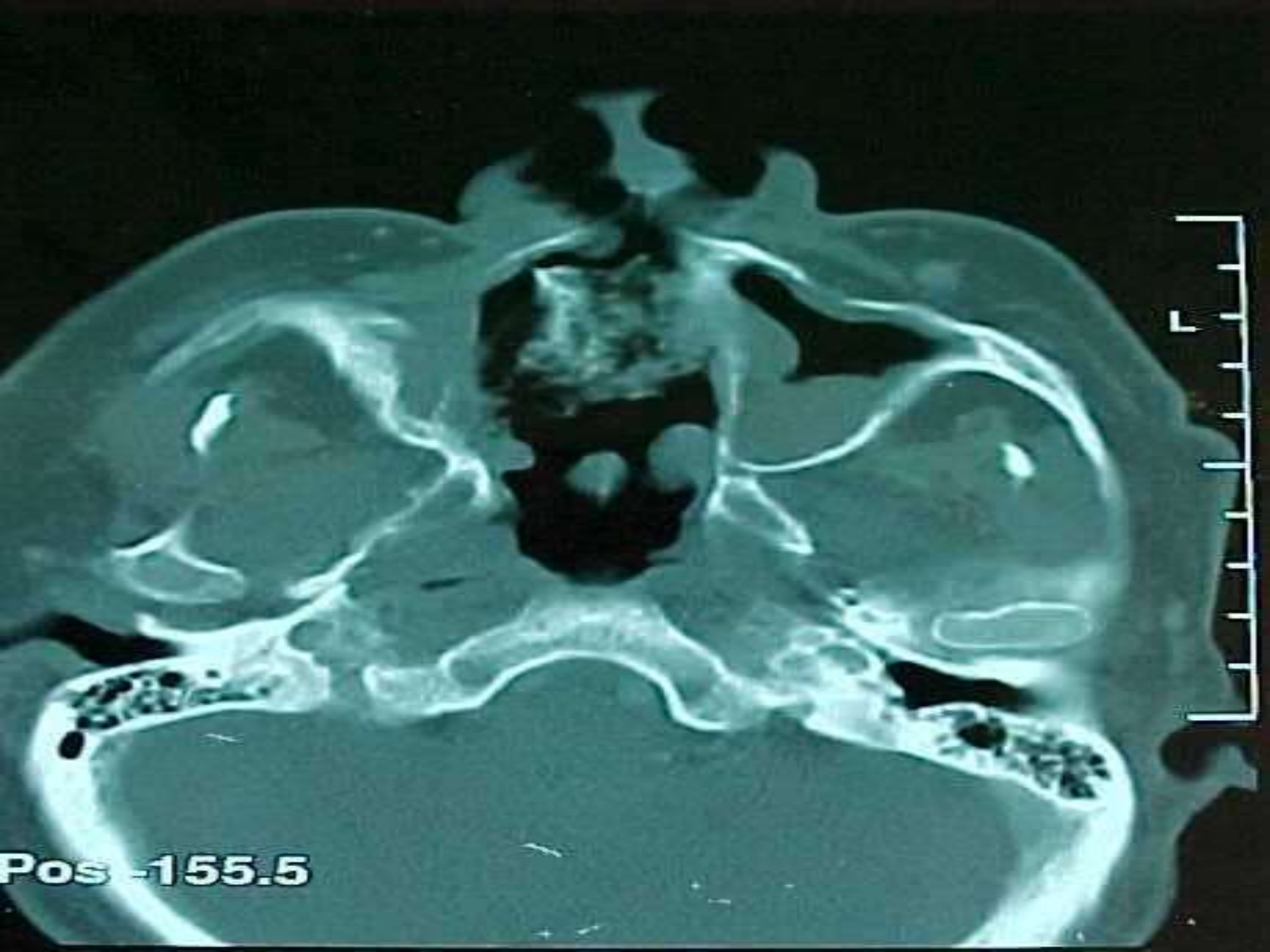

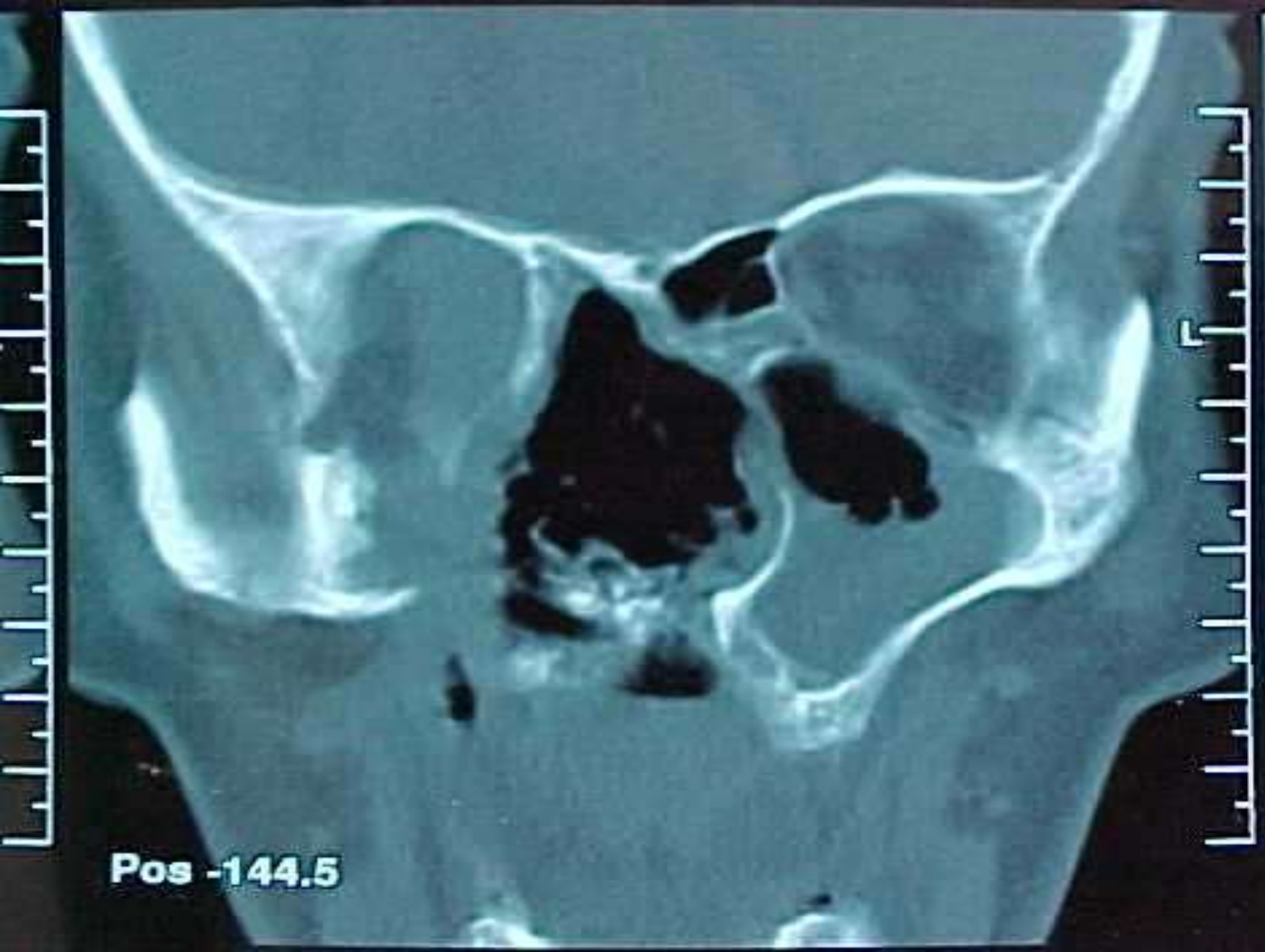INFECCÕES FÚNGICAS MISTAS

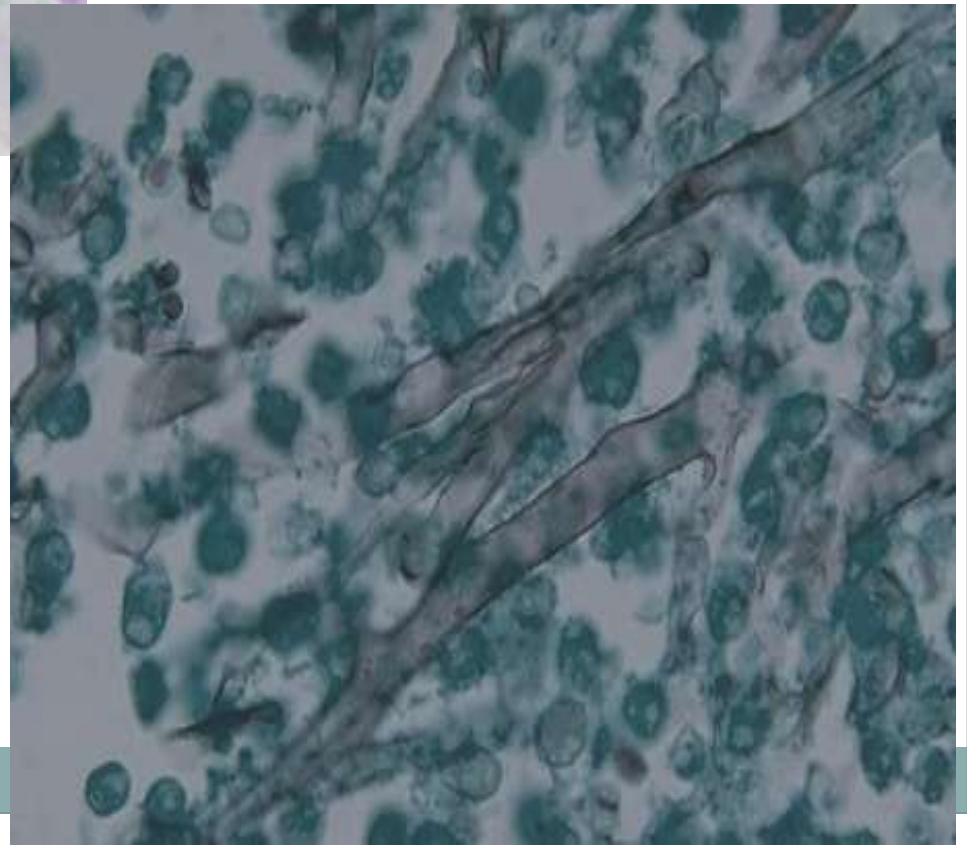
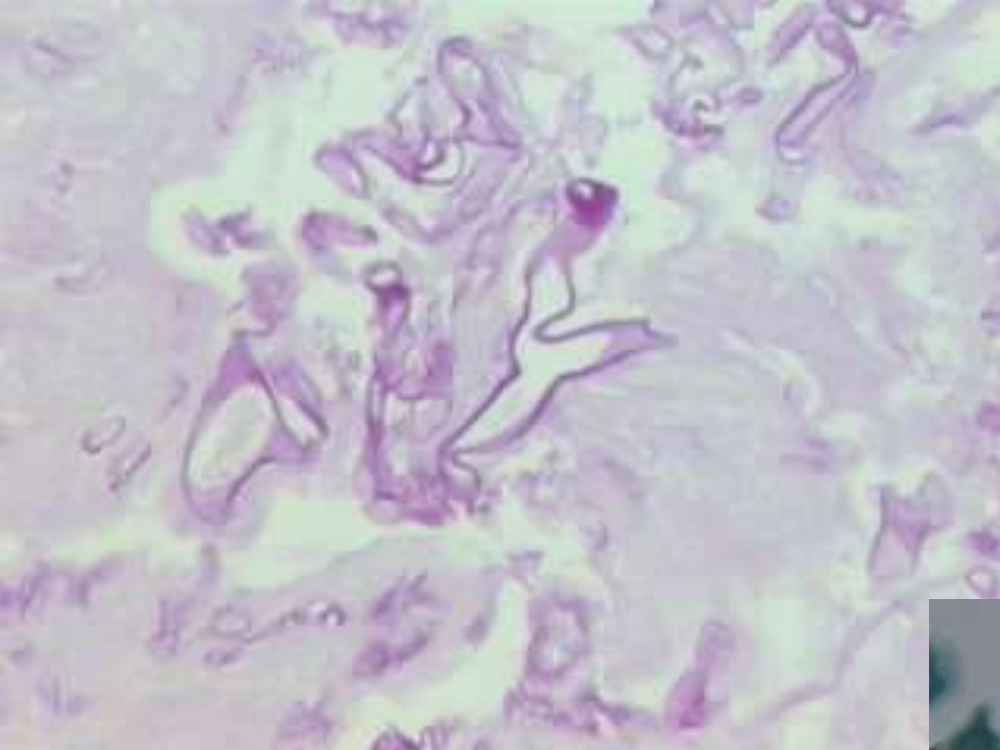




Pos -155.5



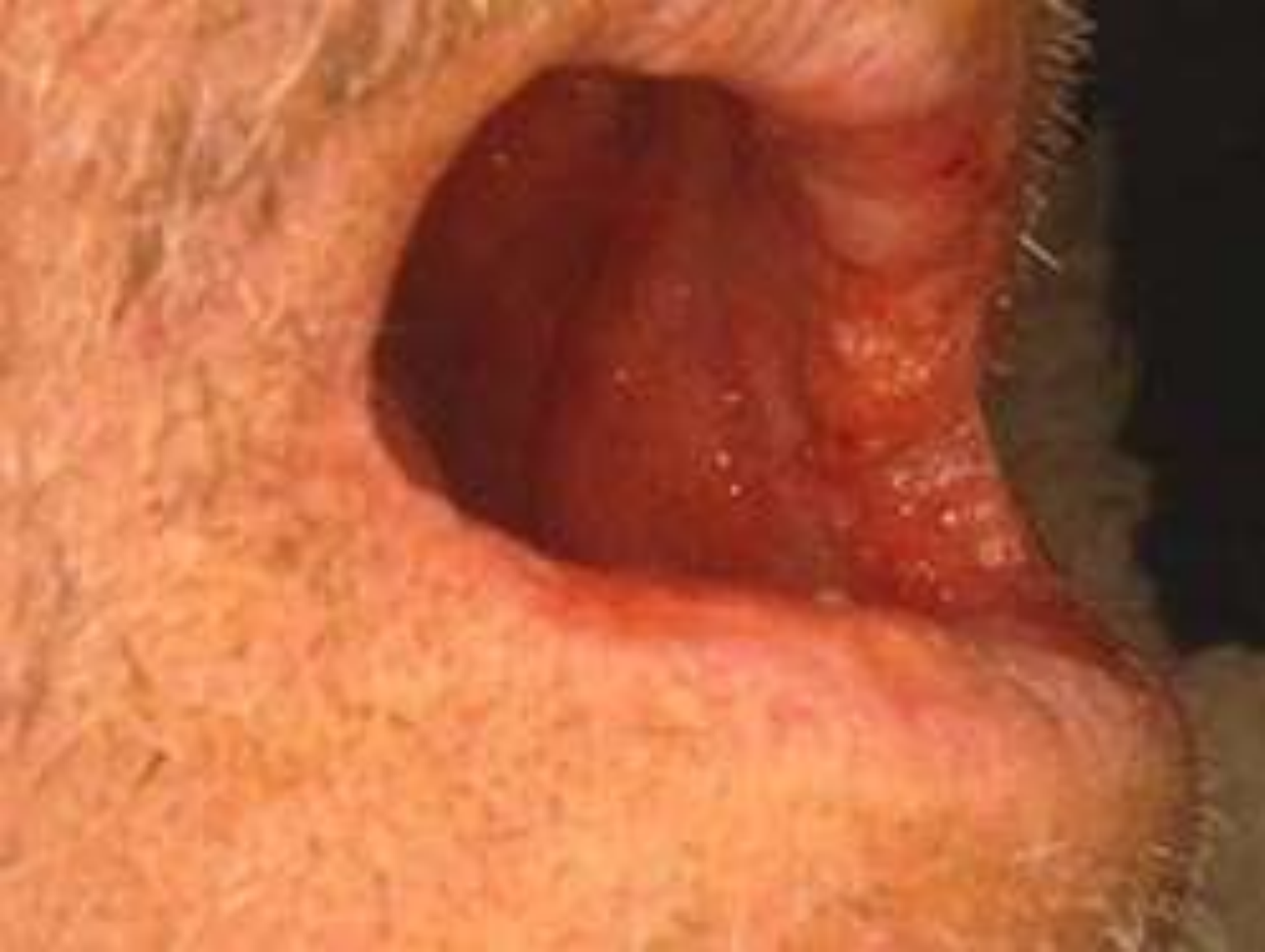Pos -144.5

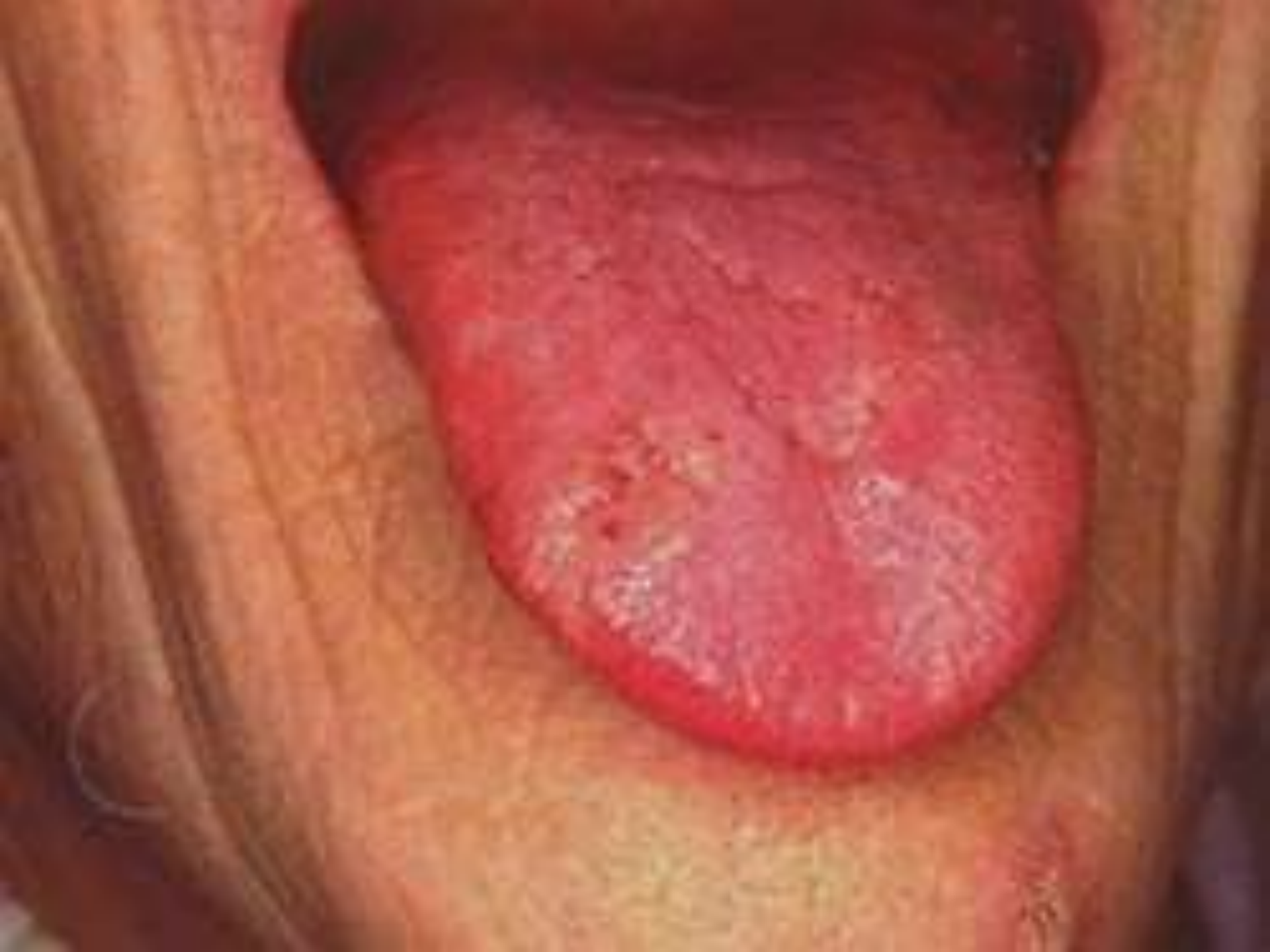

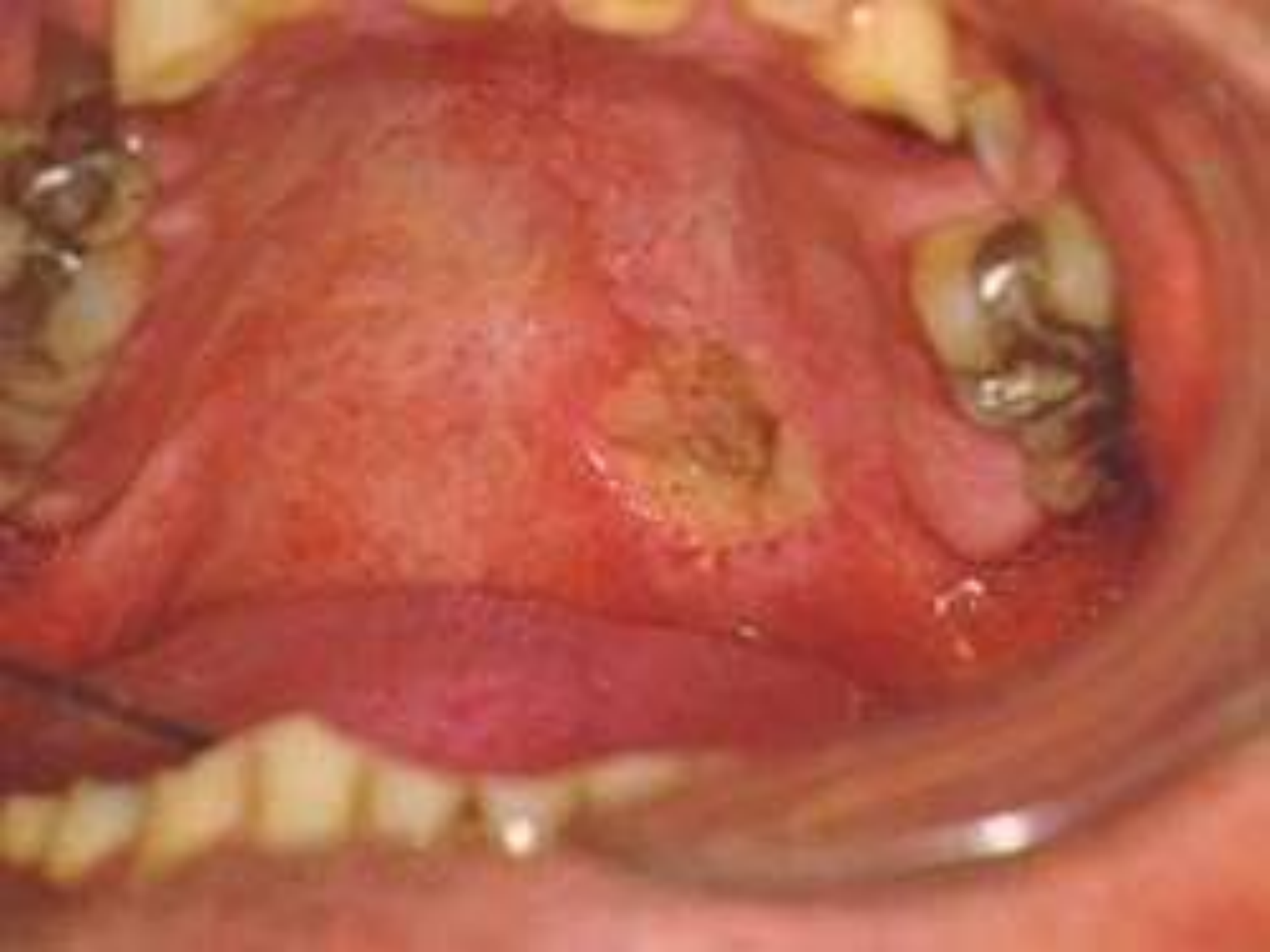Cavidade Oral

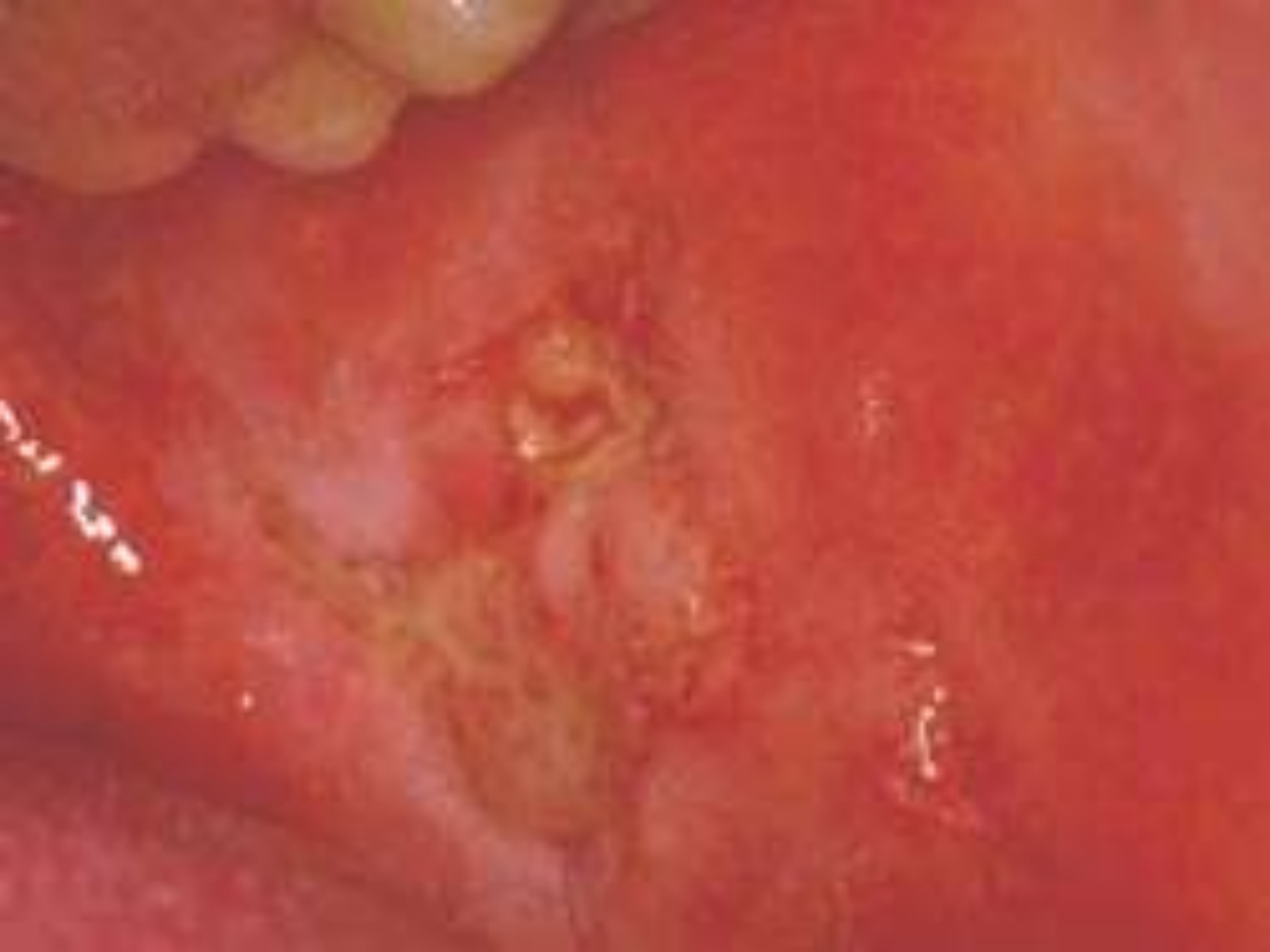

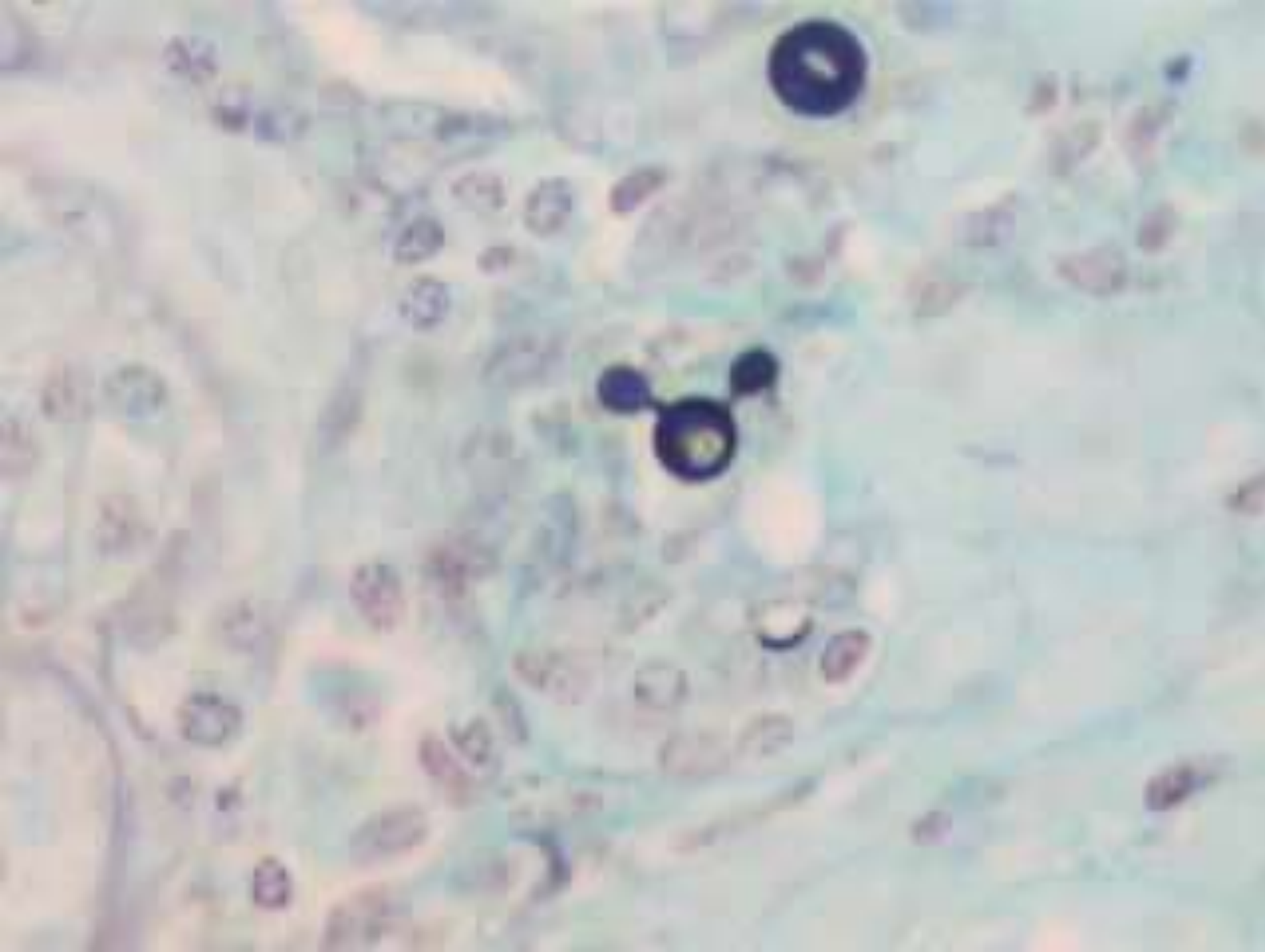
- *Paracoccidioidomycosis*





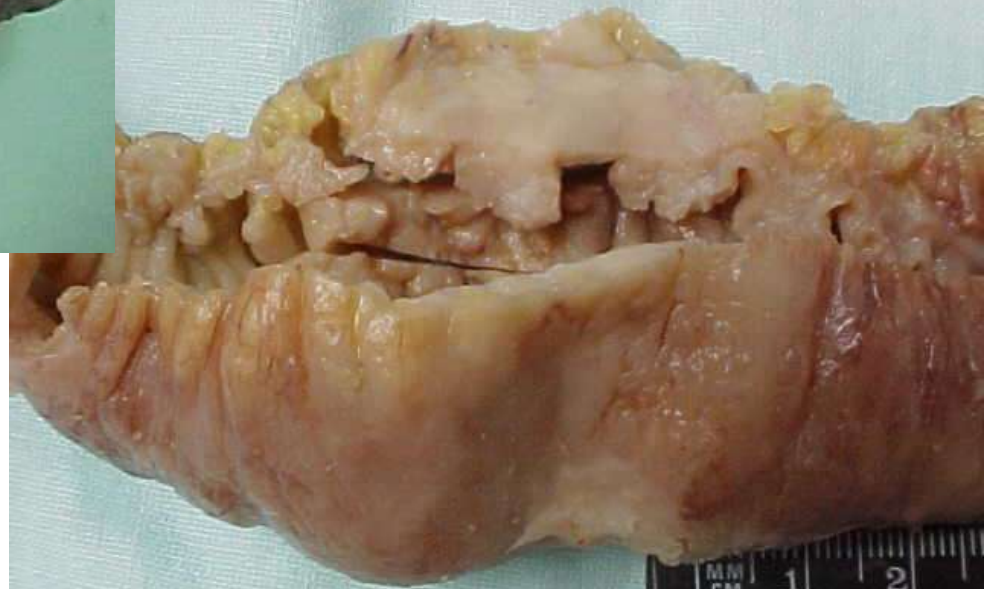
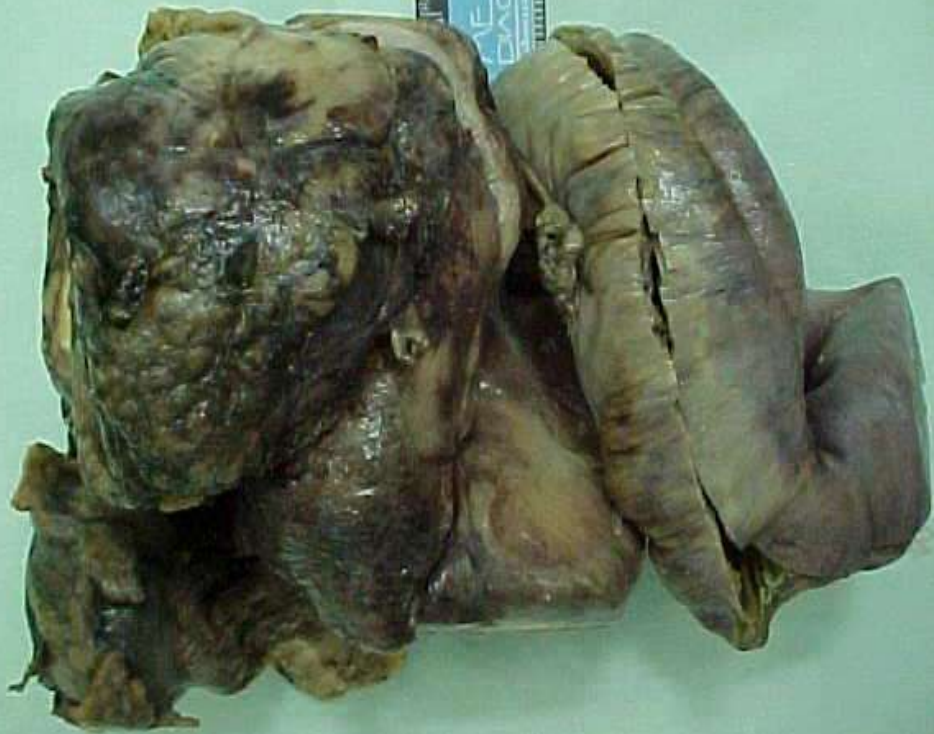


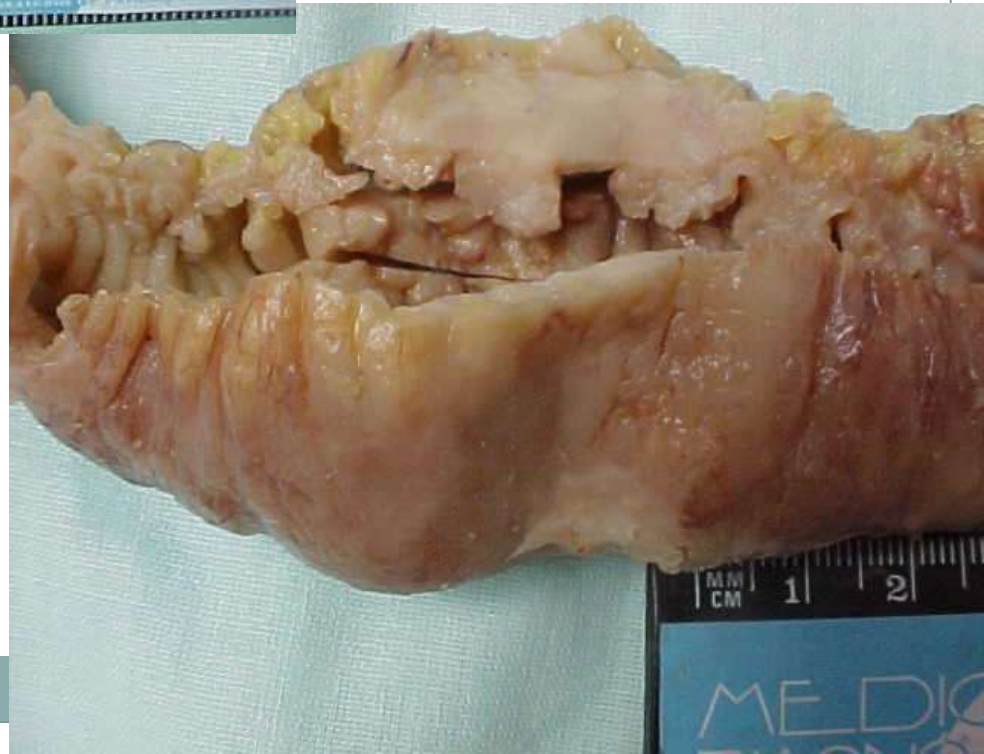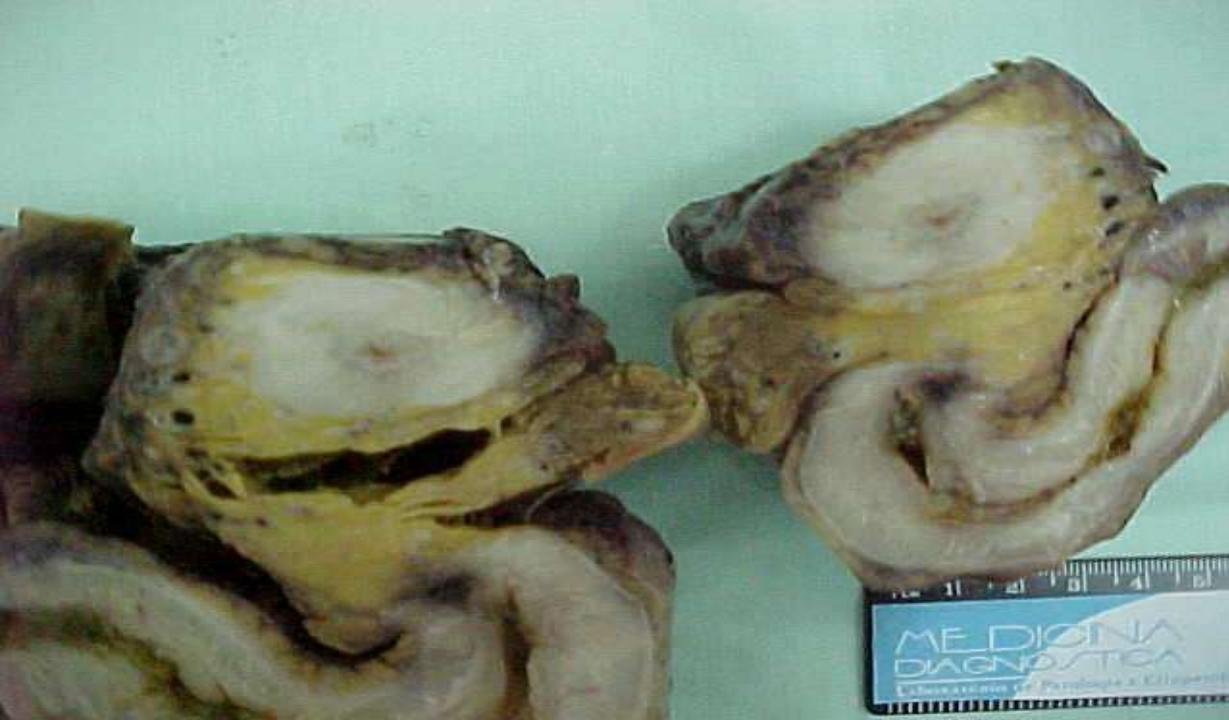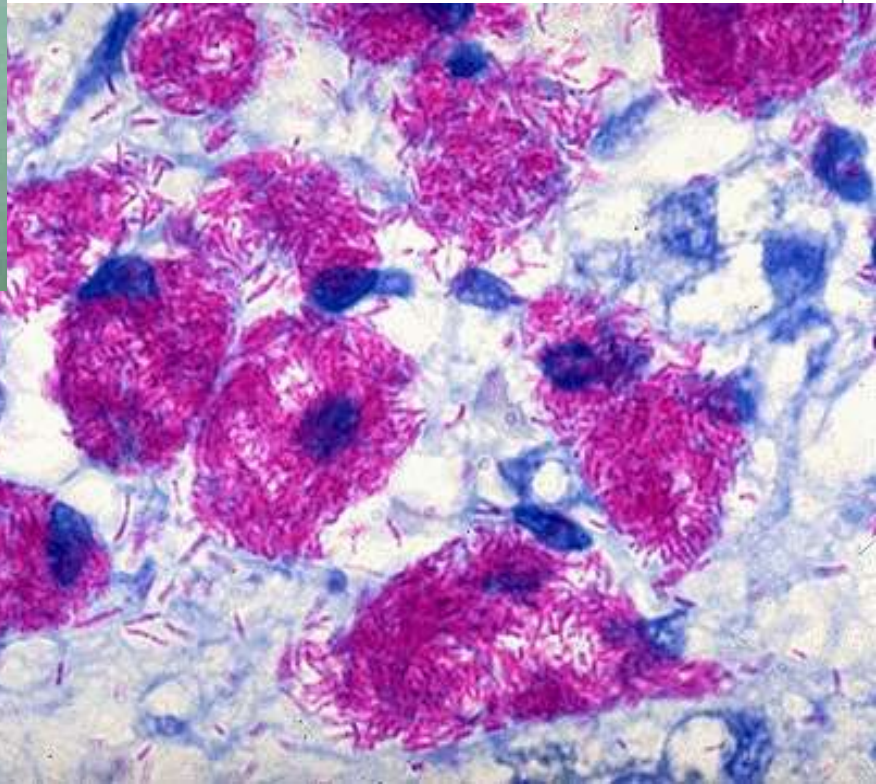




04/06/2009 08:11





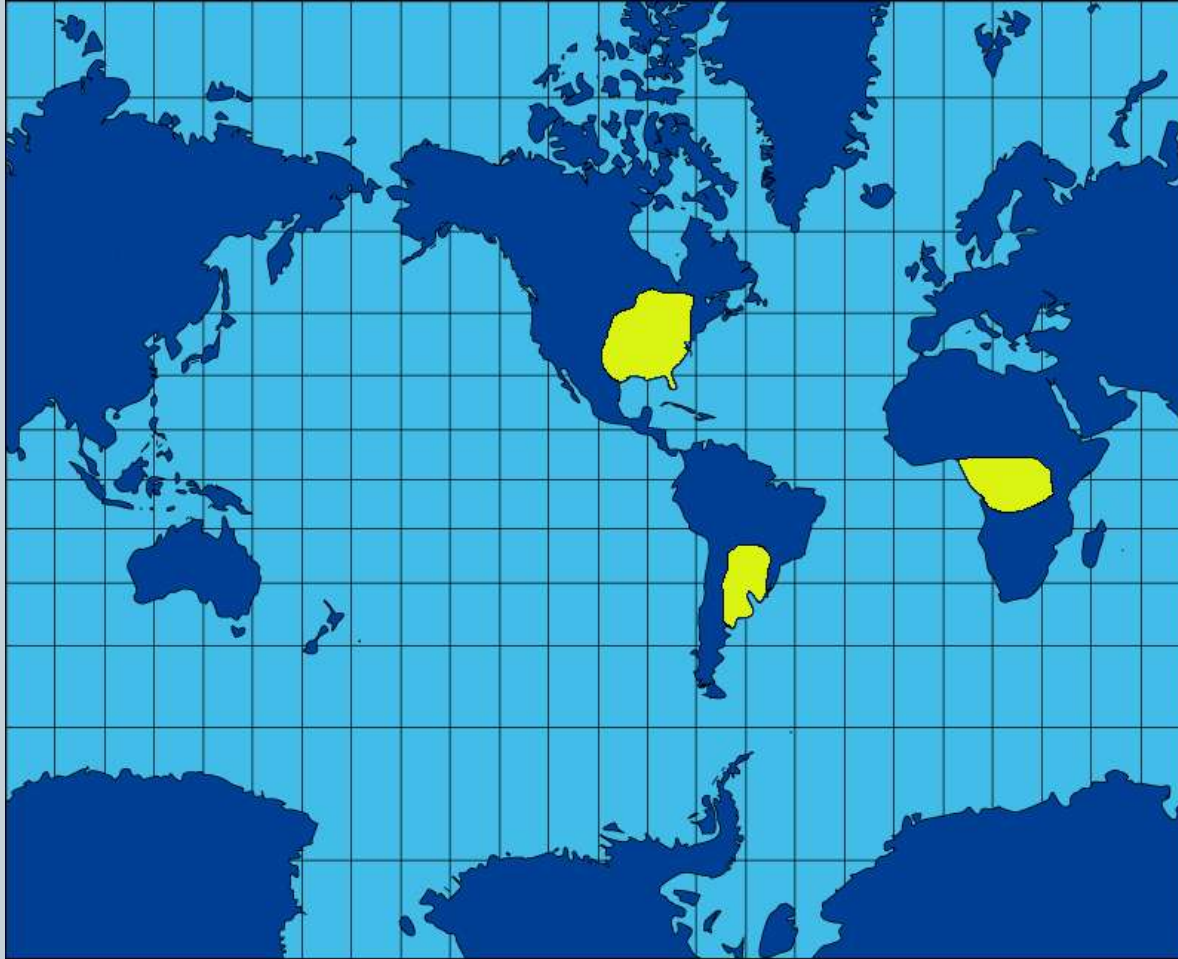


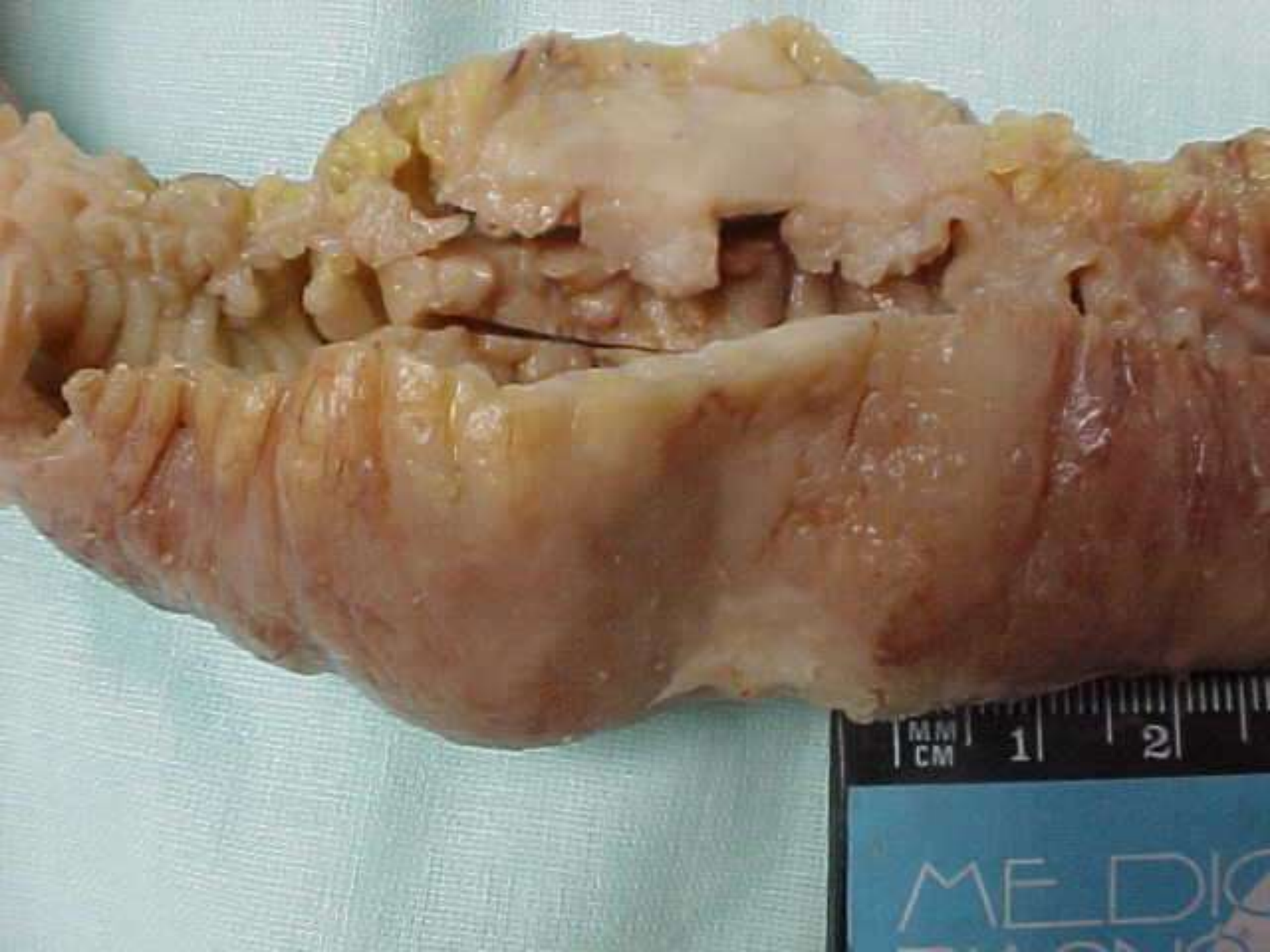Sistema Digestivo

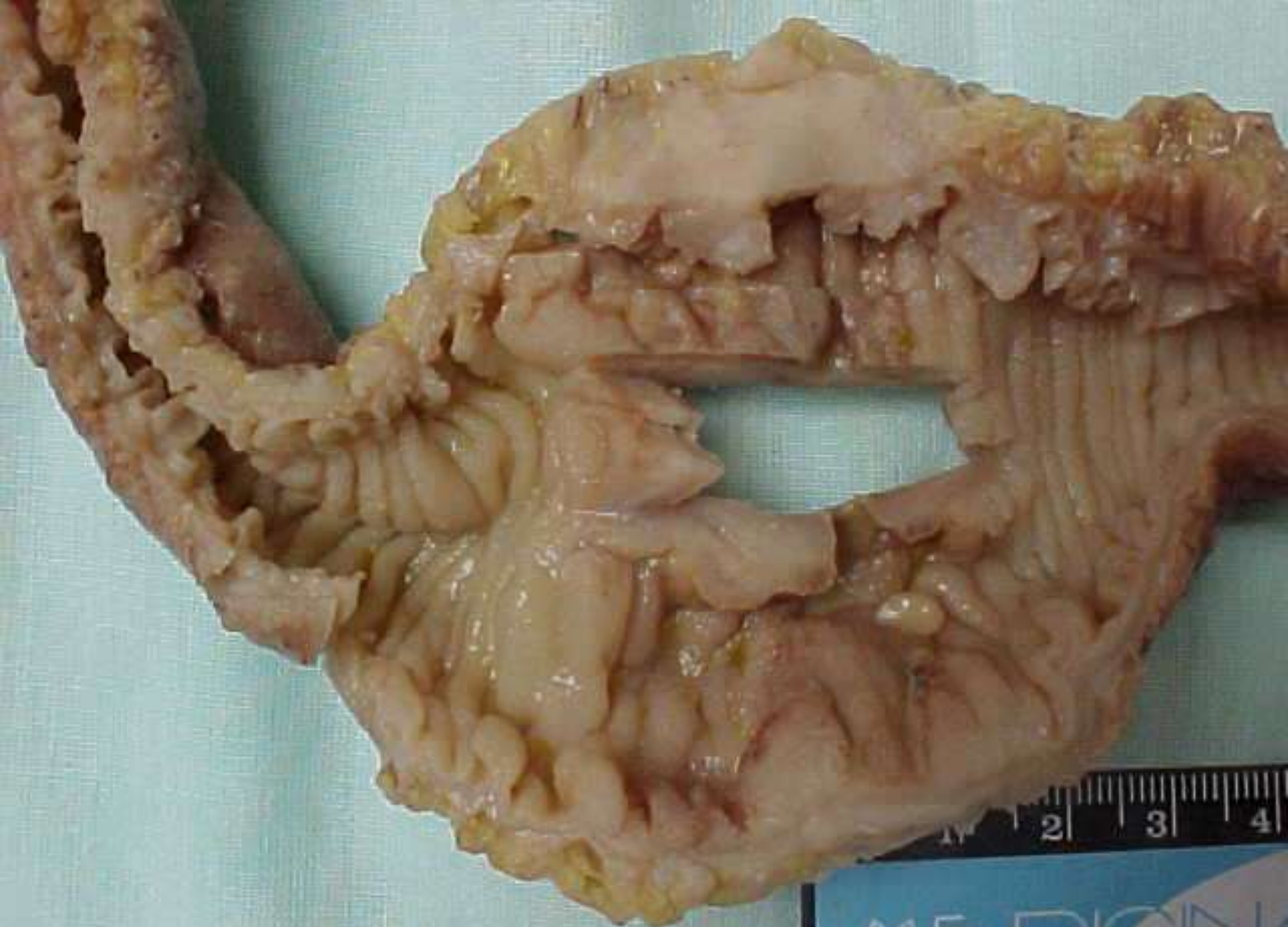

- Histoplasmosis
- Cryptococcosis

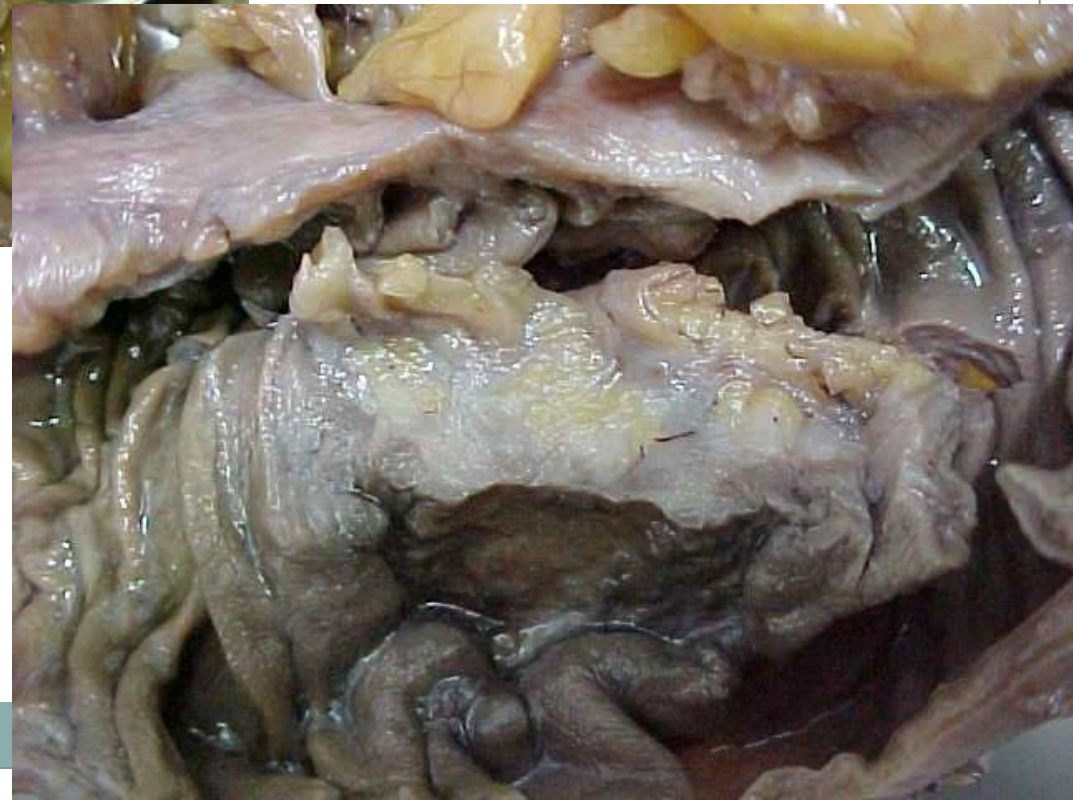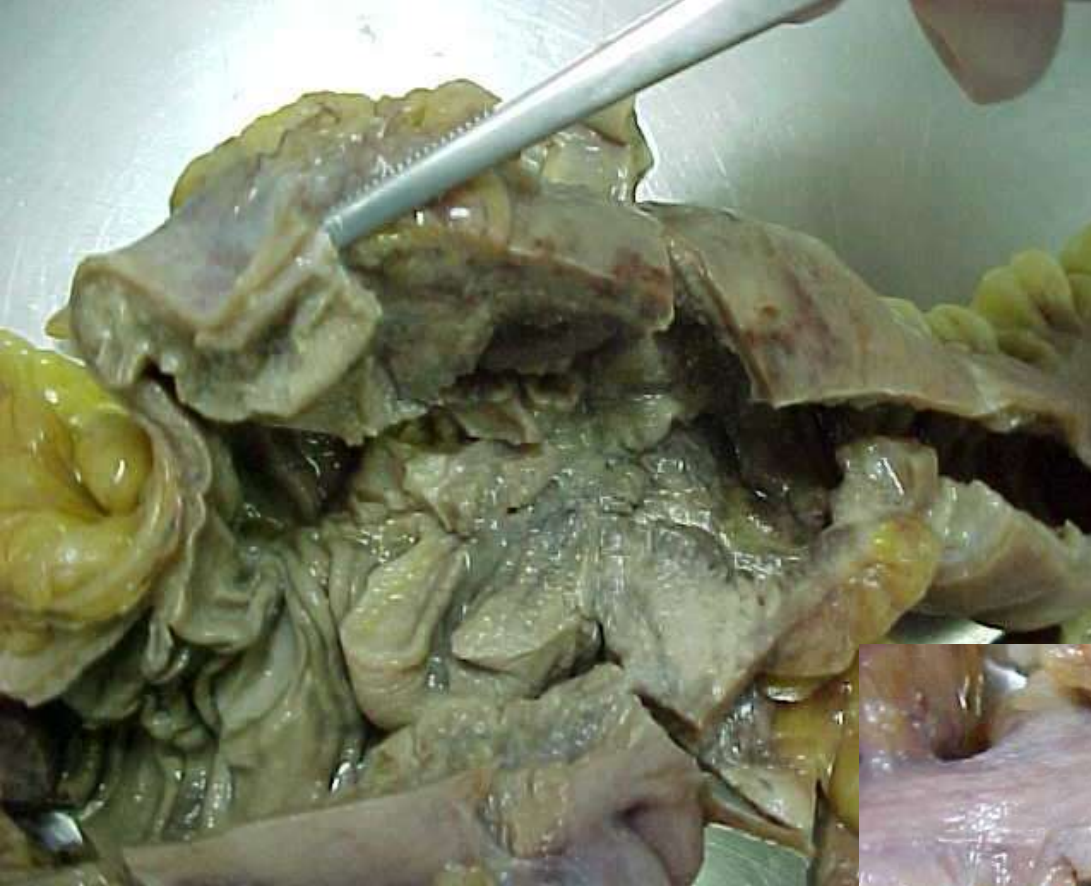HISTOPLAMOSIS

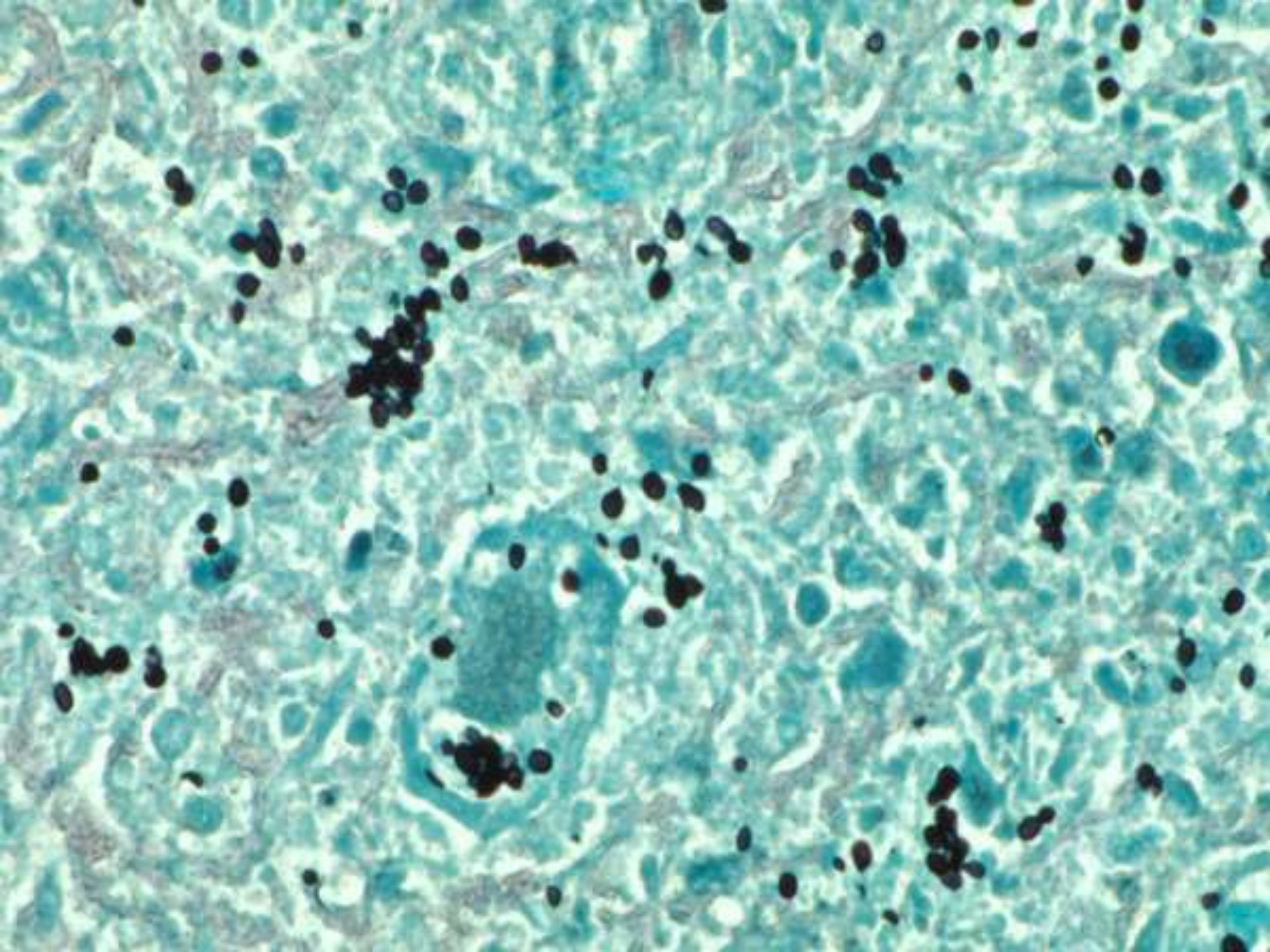


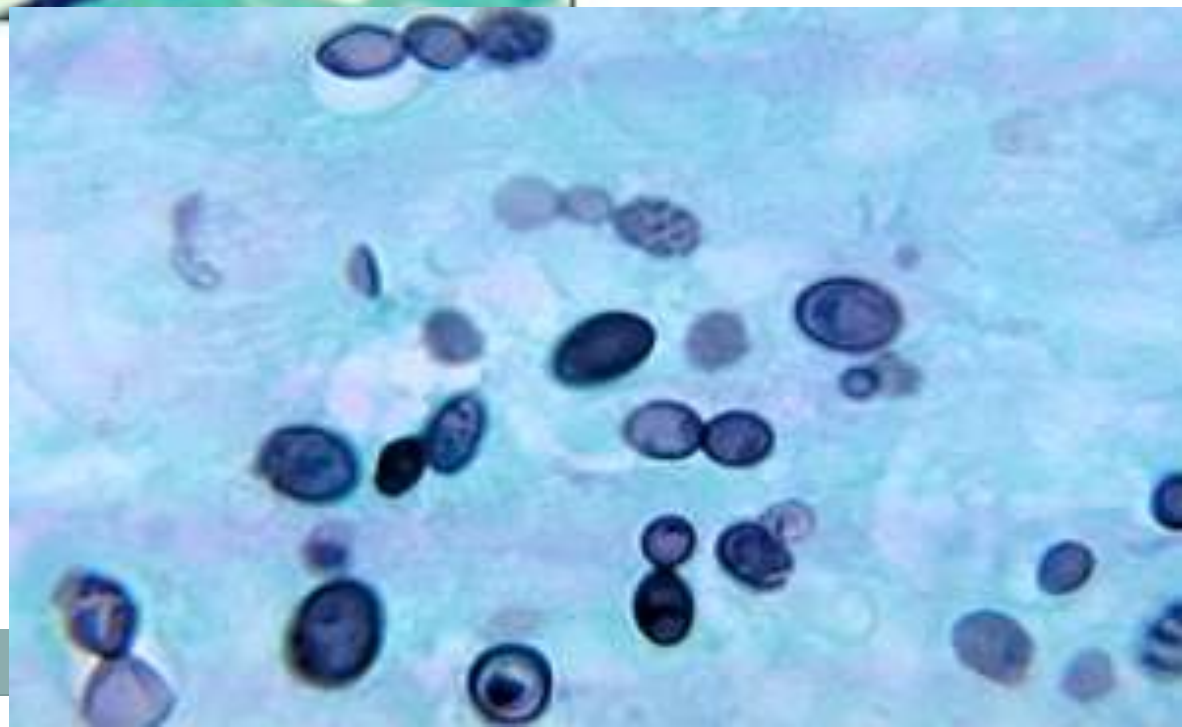
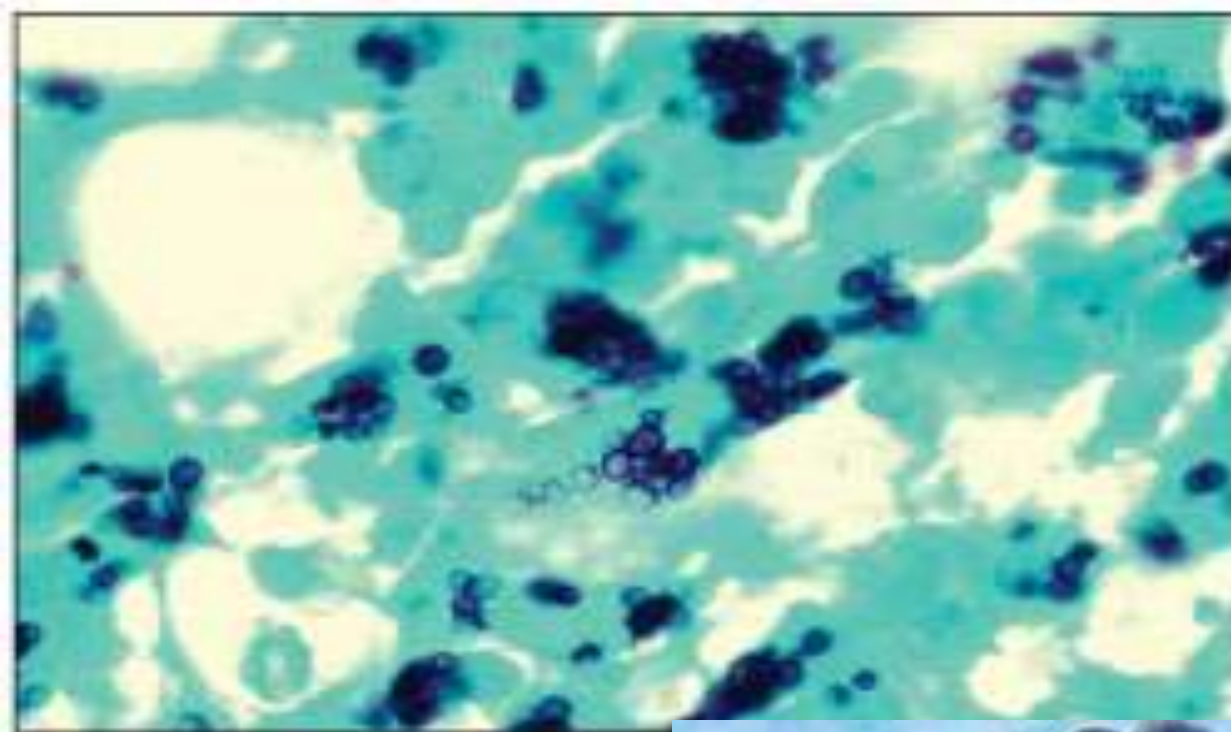




MEDICINA





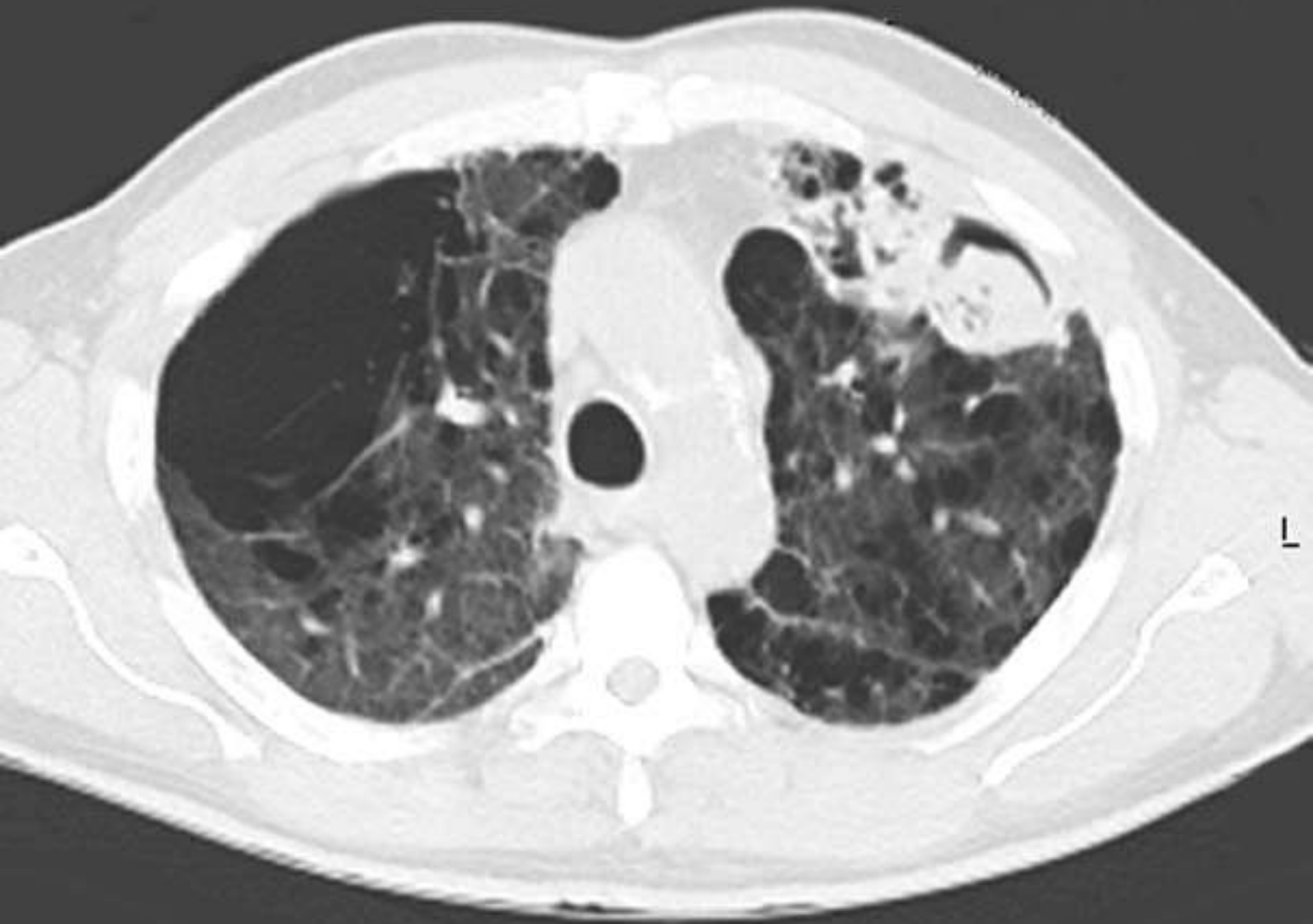


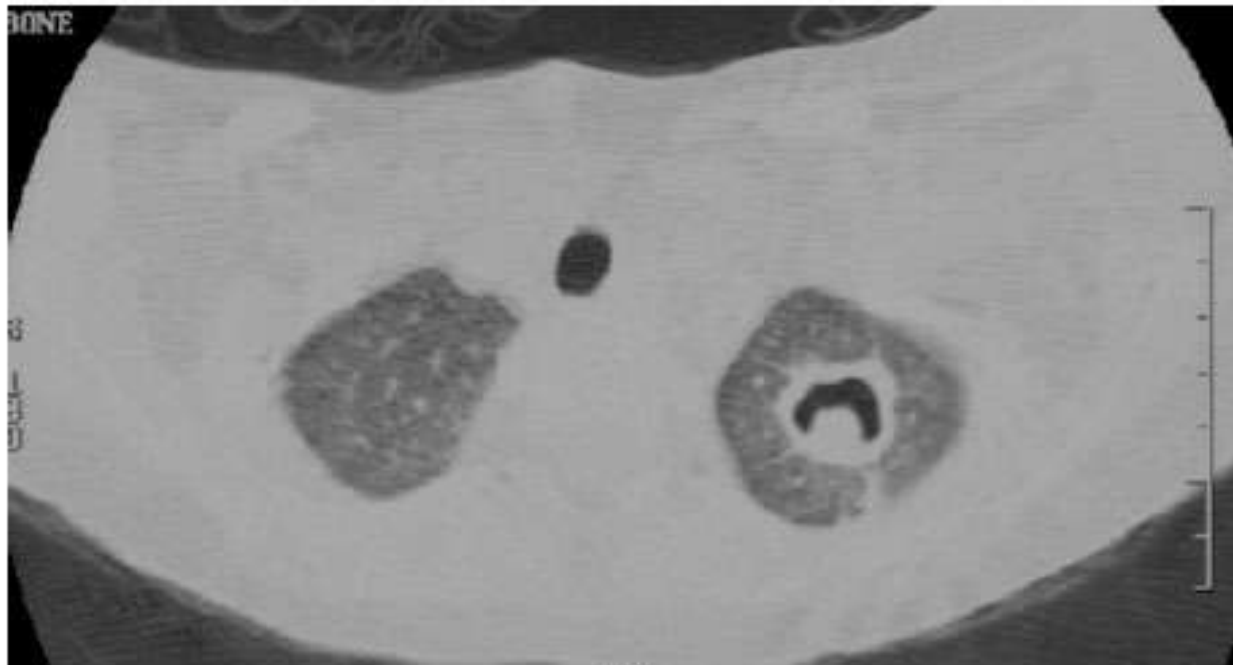
PULMÃO

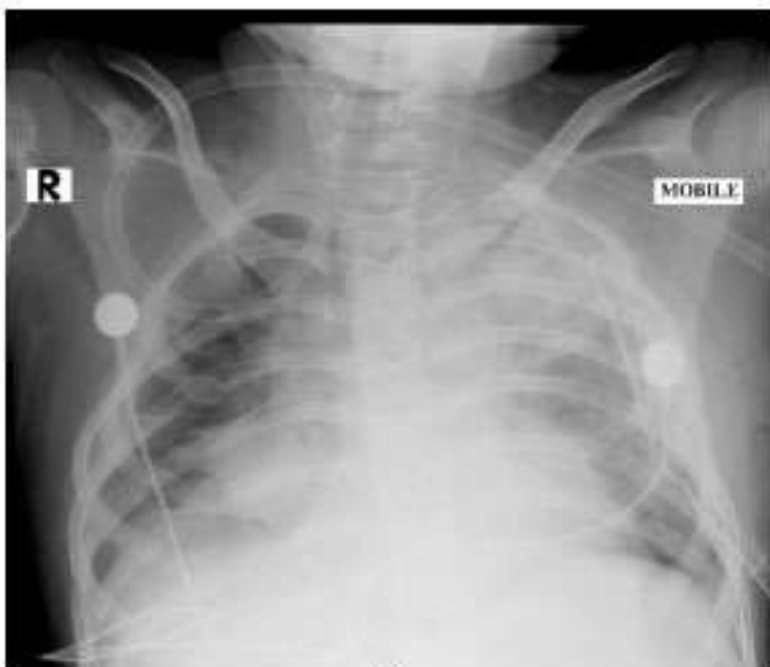

- Cryptococcosis
- Aspergillosis
- *Paracoccidioidomycosis*

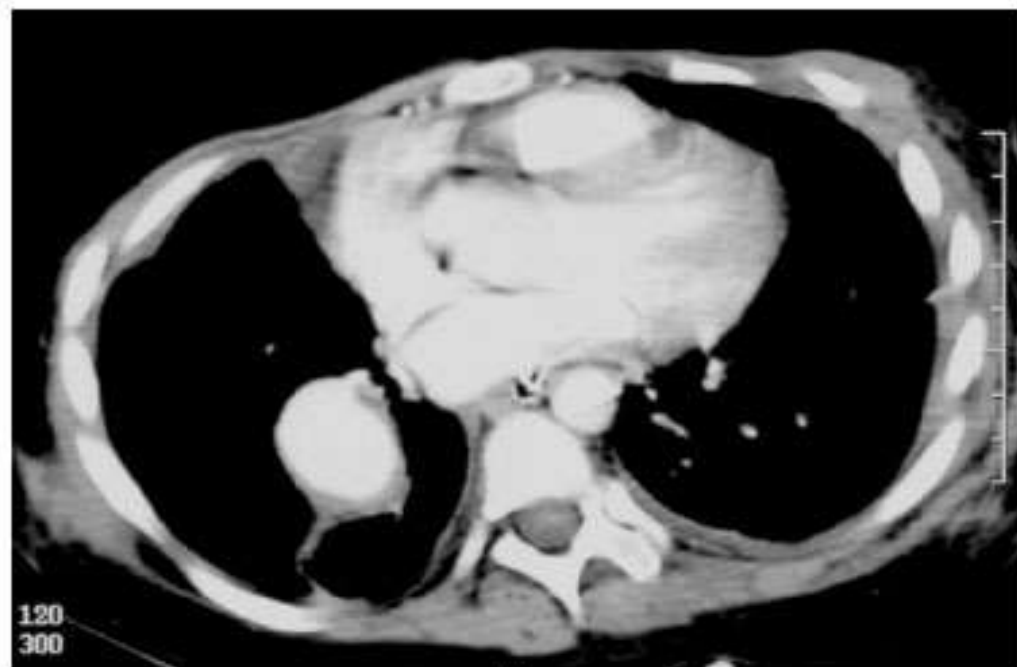



(a)

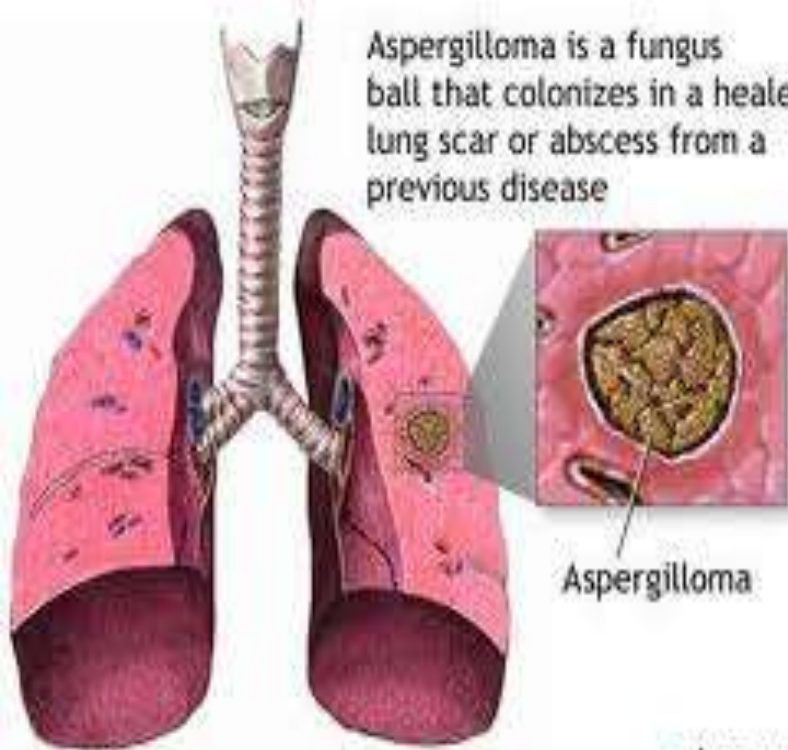


(b)



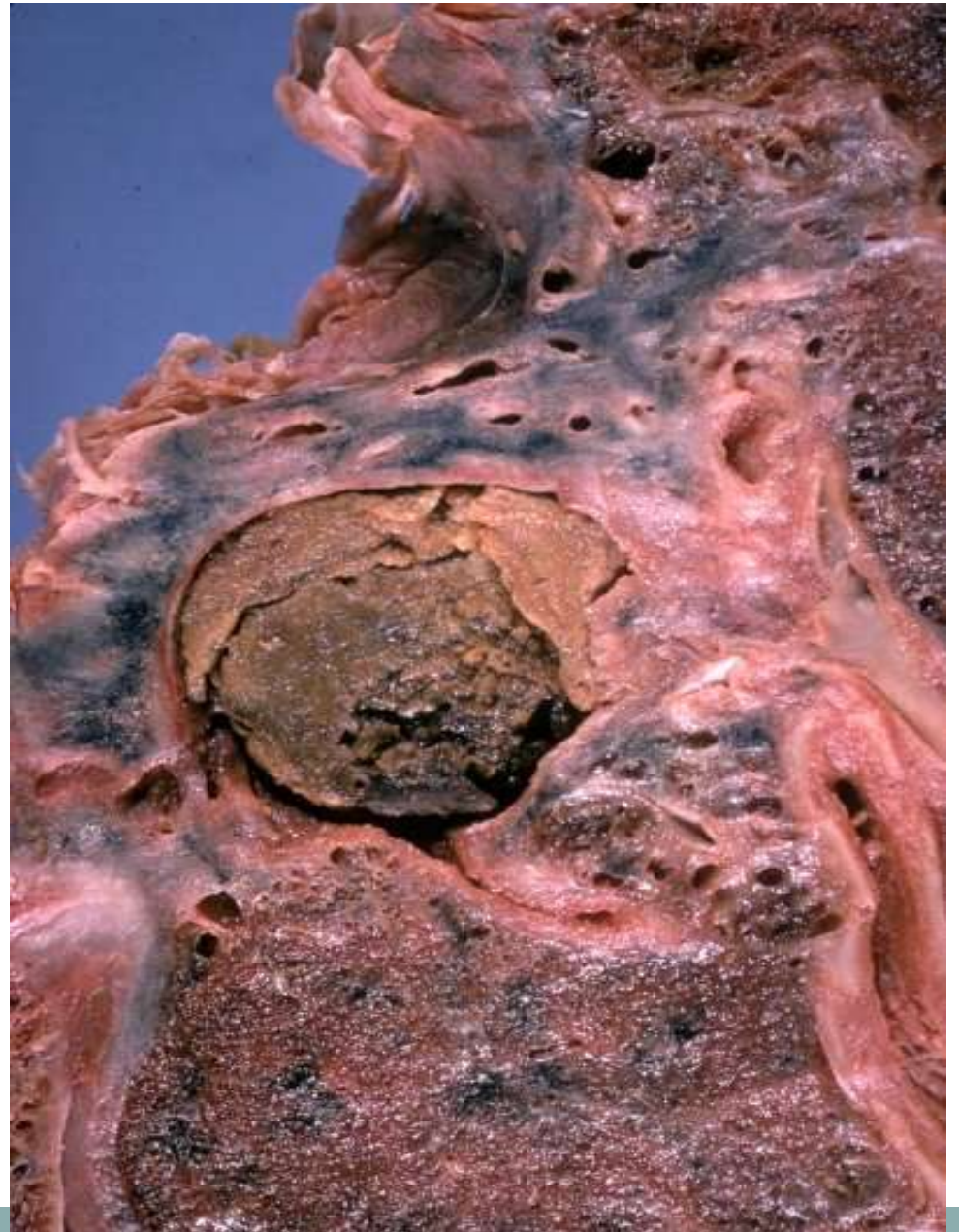(c)

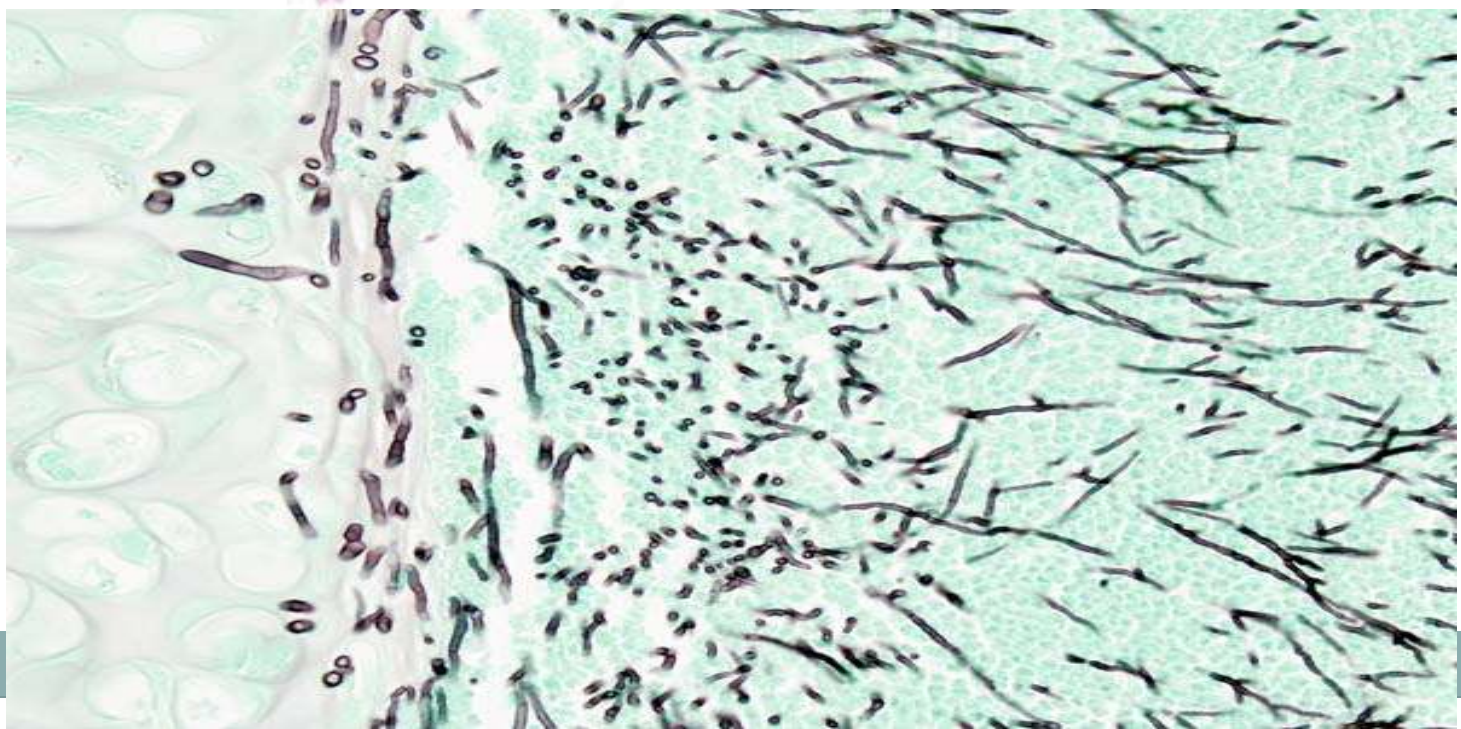
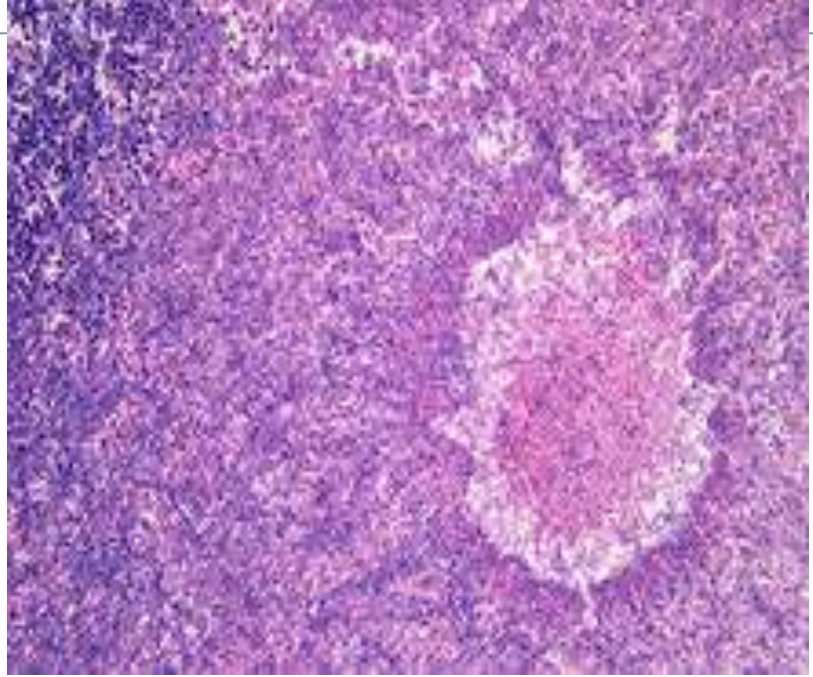
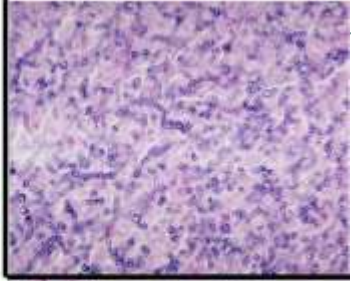
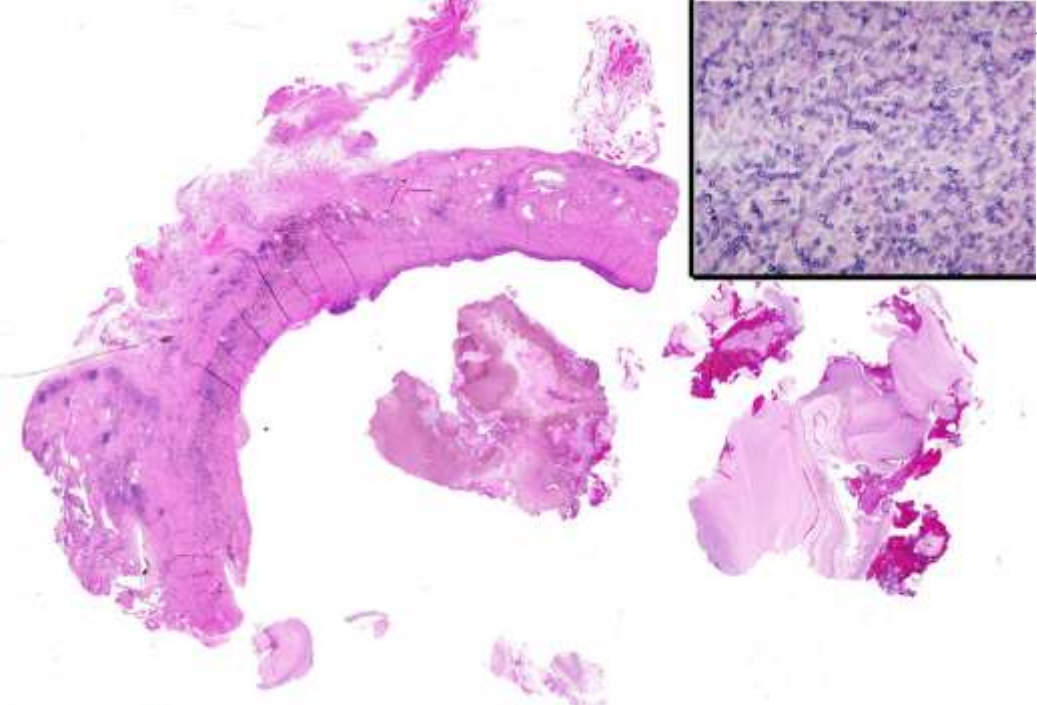
Aspergilloma is a fungus ball that colonizes in a healed lung scar or abscess from a previous disease



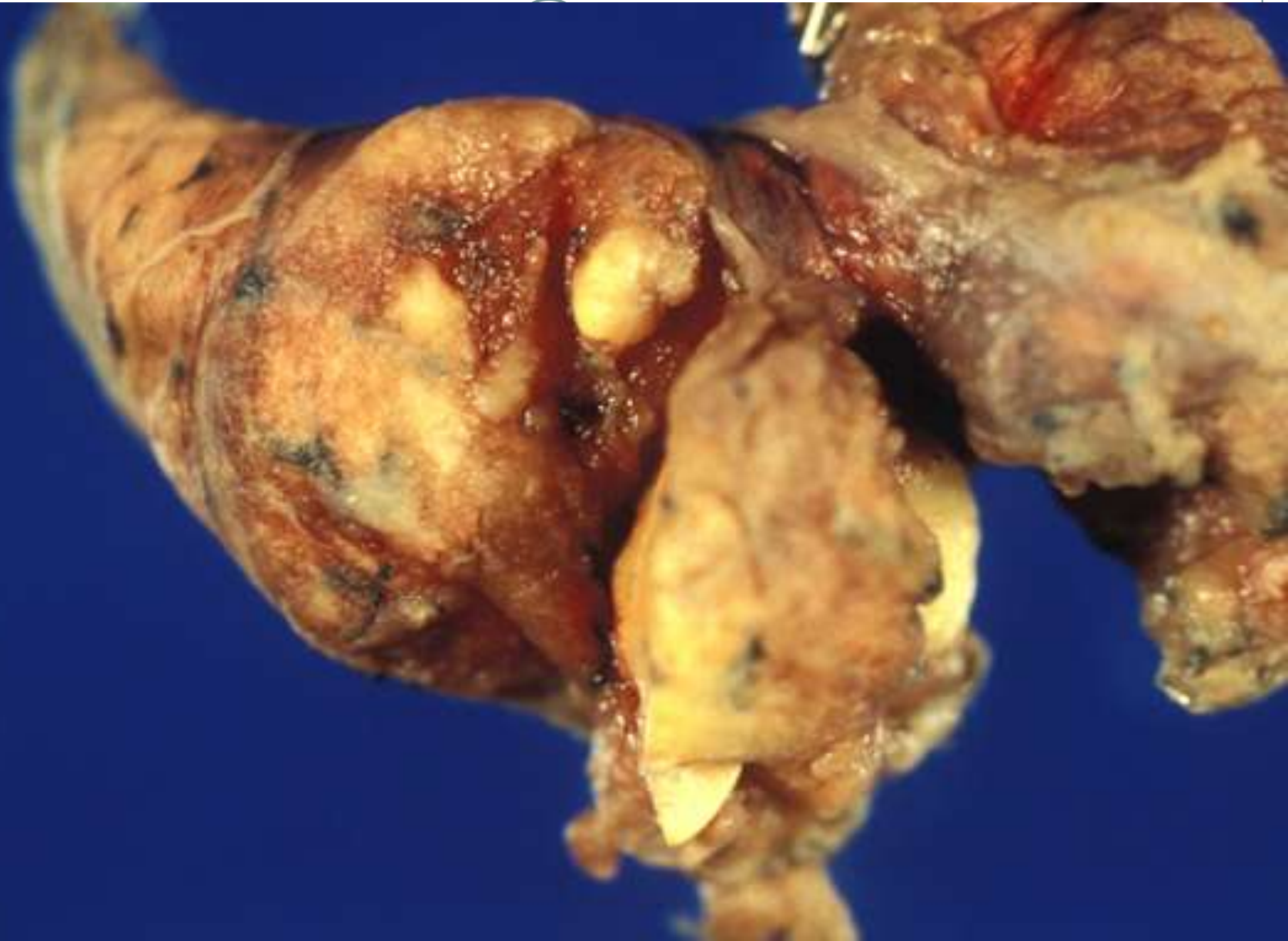Aspergilloma

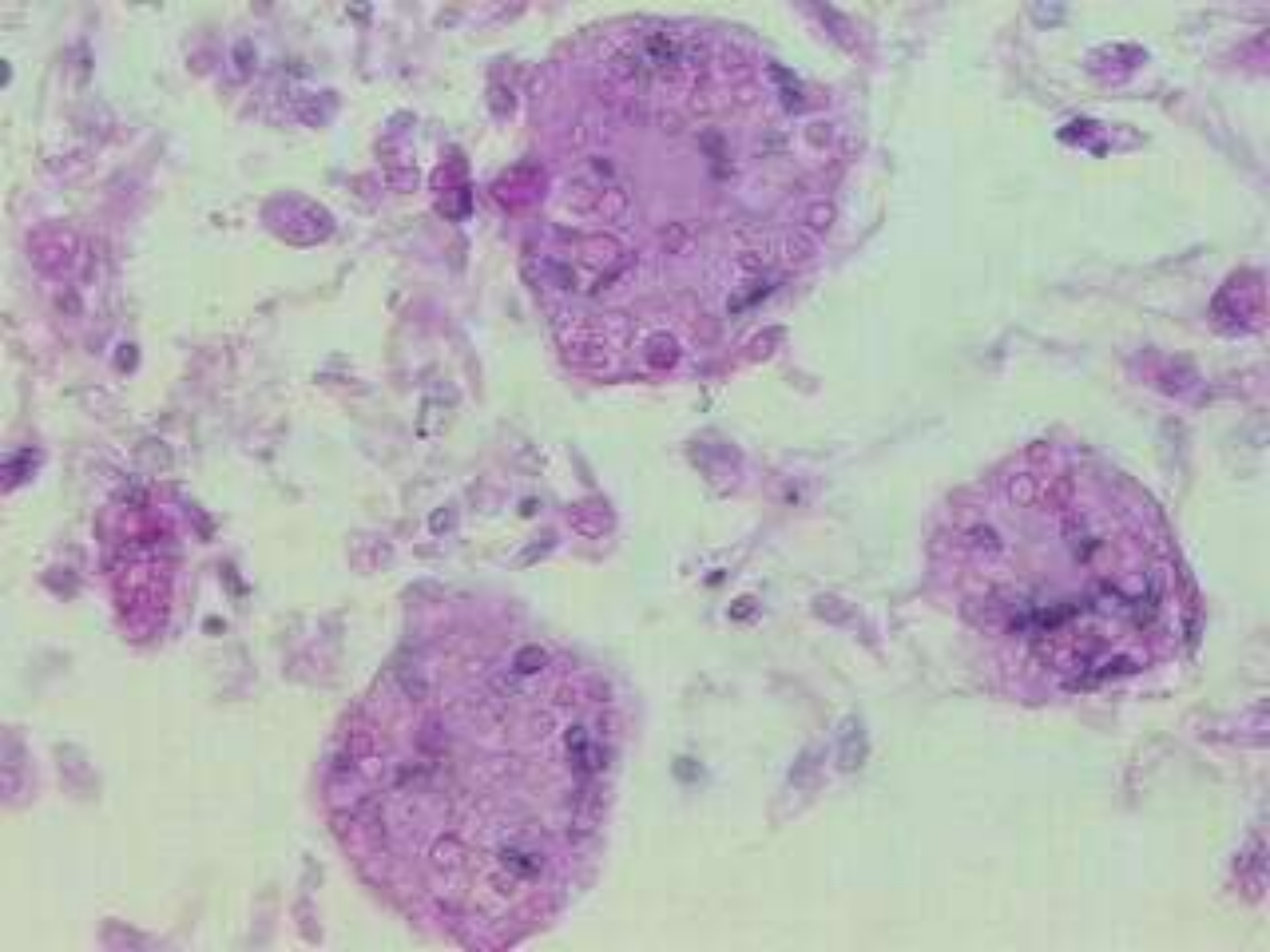
ADAM

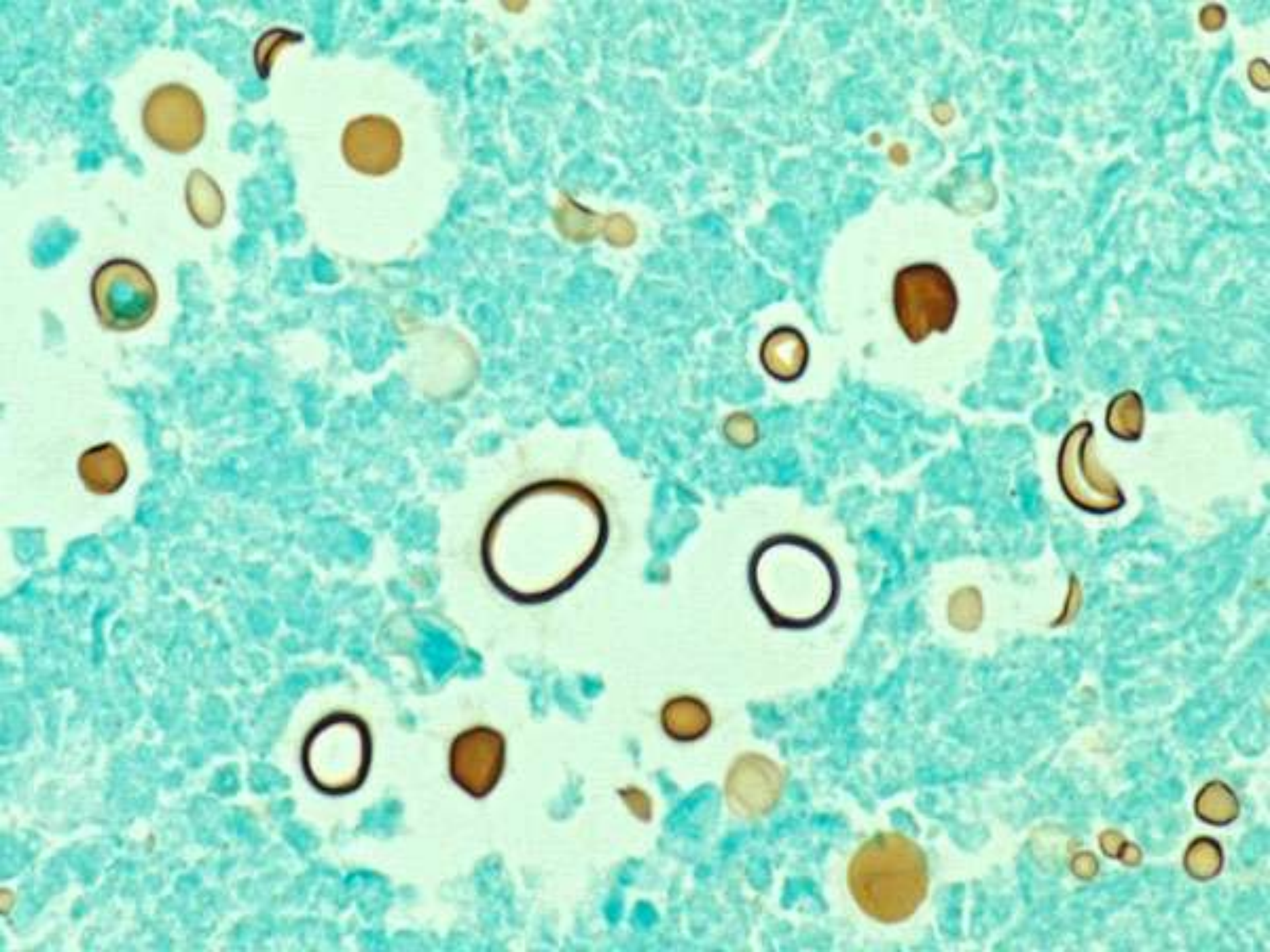


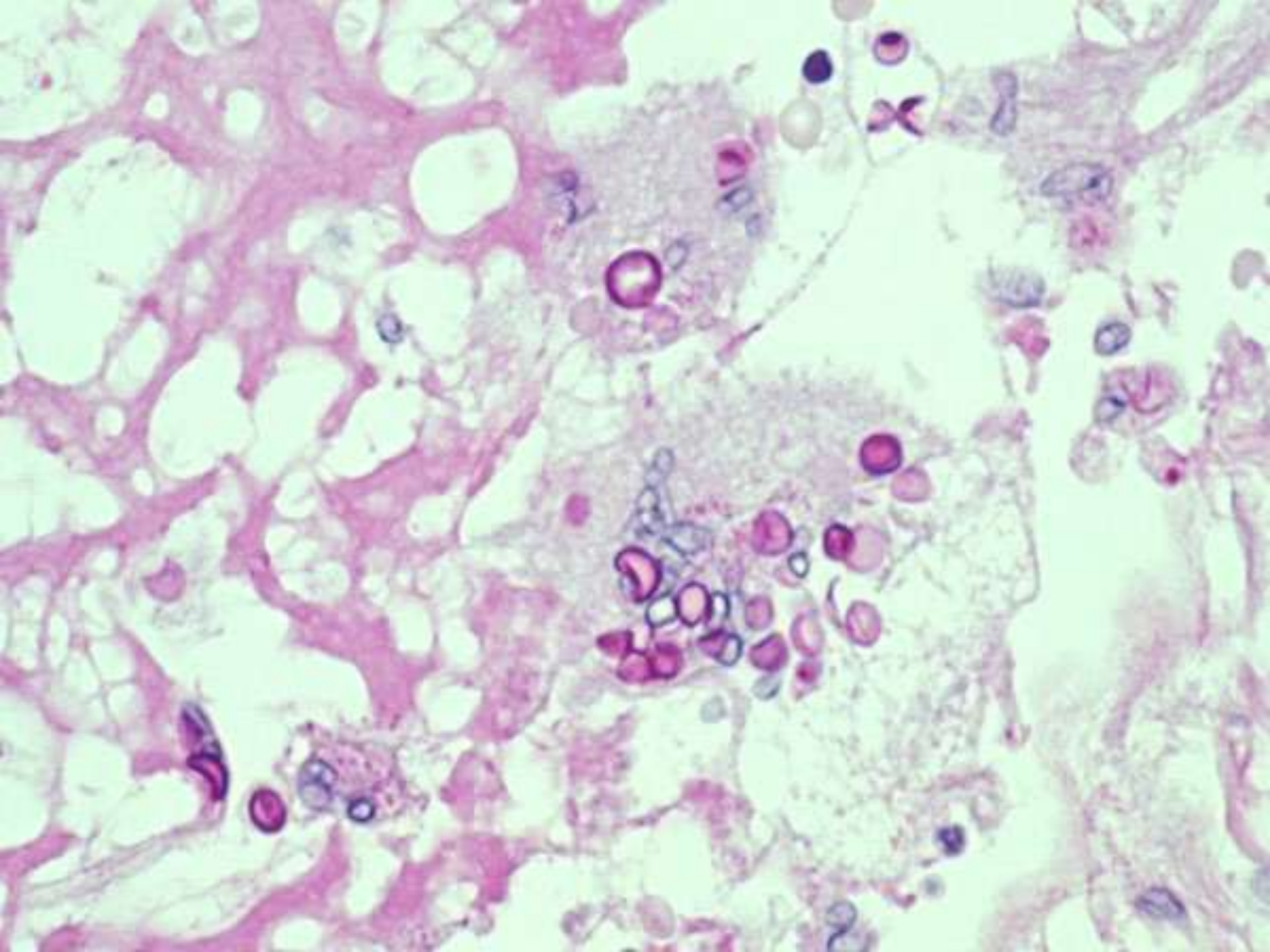


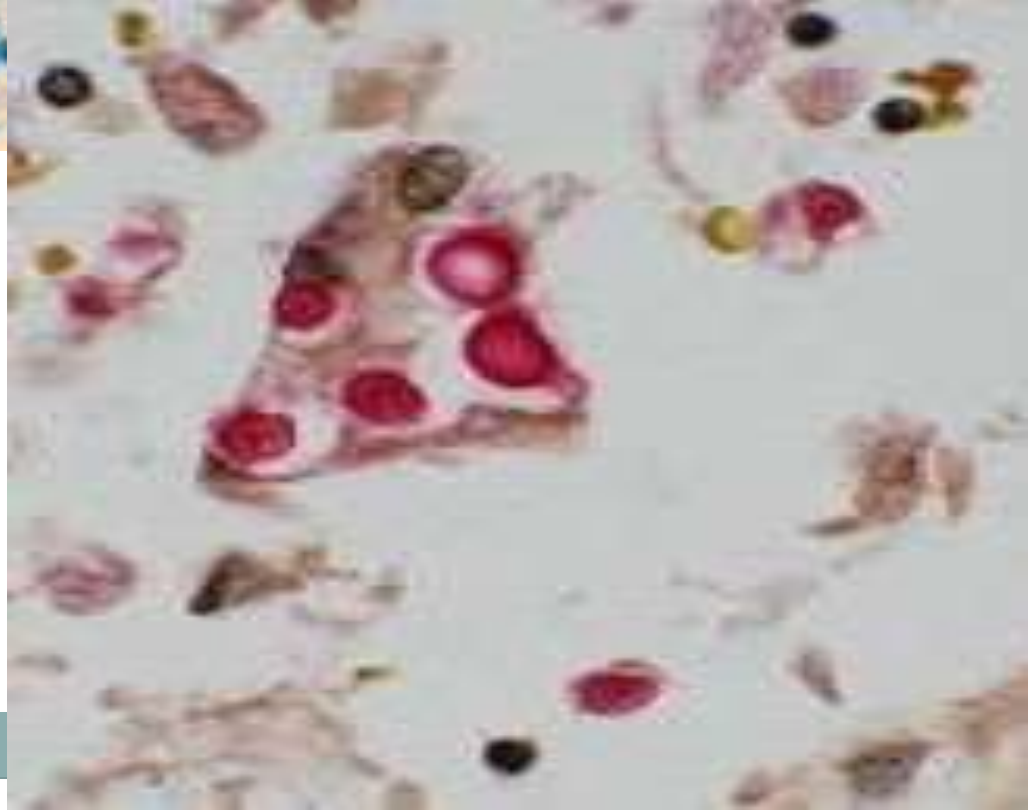

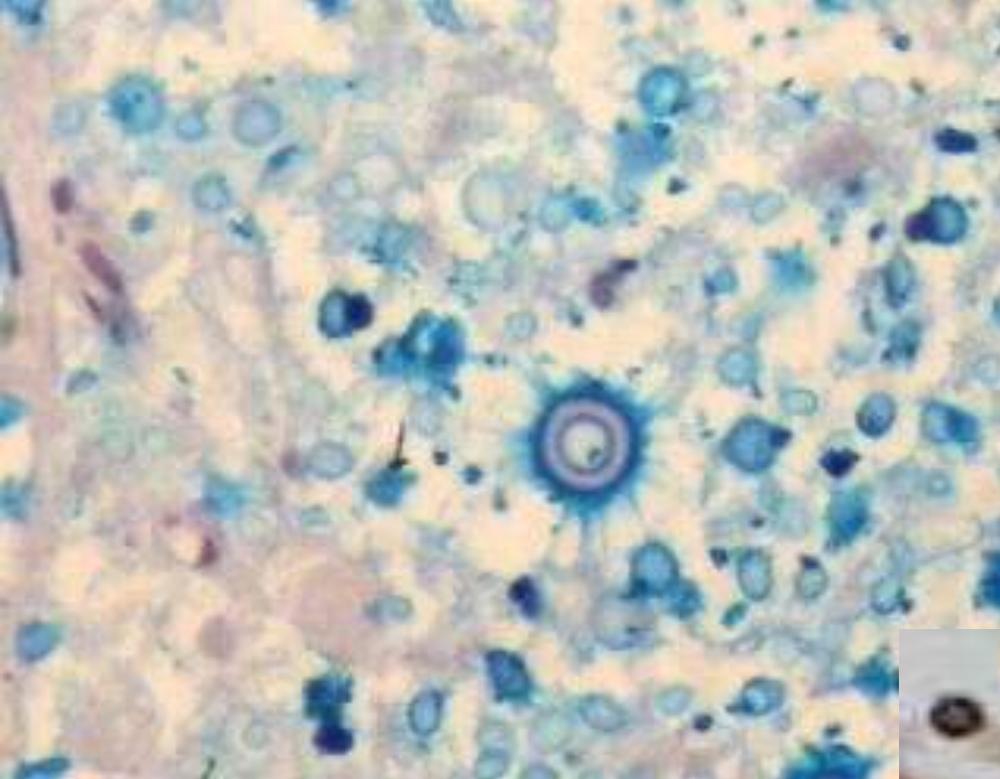
CRYPTOCOCCOMA













SISTEMA MUSCULO-ESQUELÉTICO



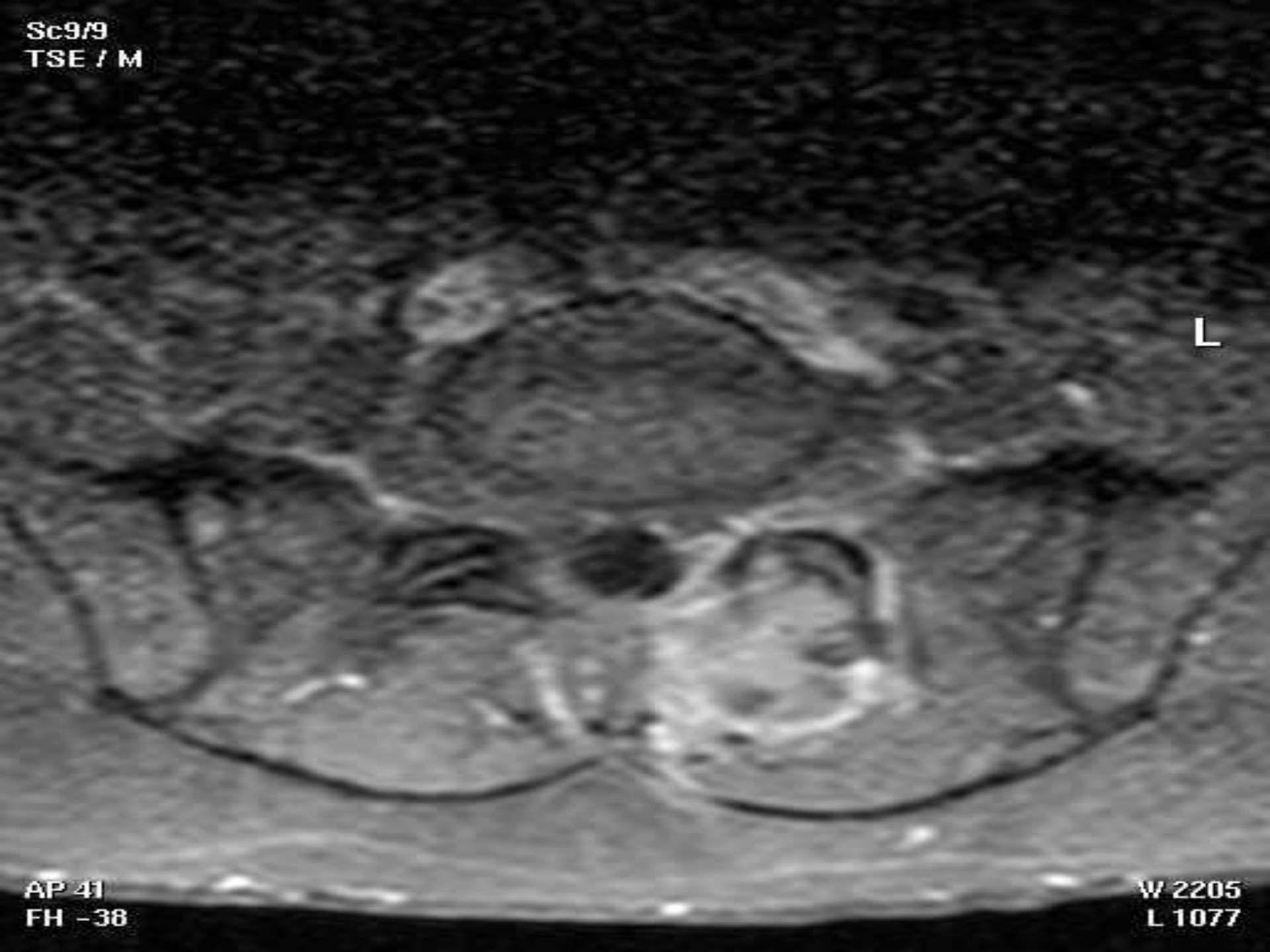
- - *Paracoccidioidomycosis*

Sc9/9
TSE / M

L

AP 41
FH -38

W 2205
L 1077

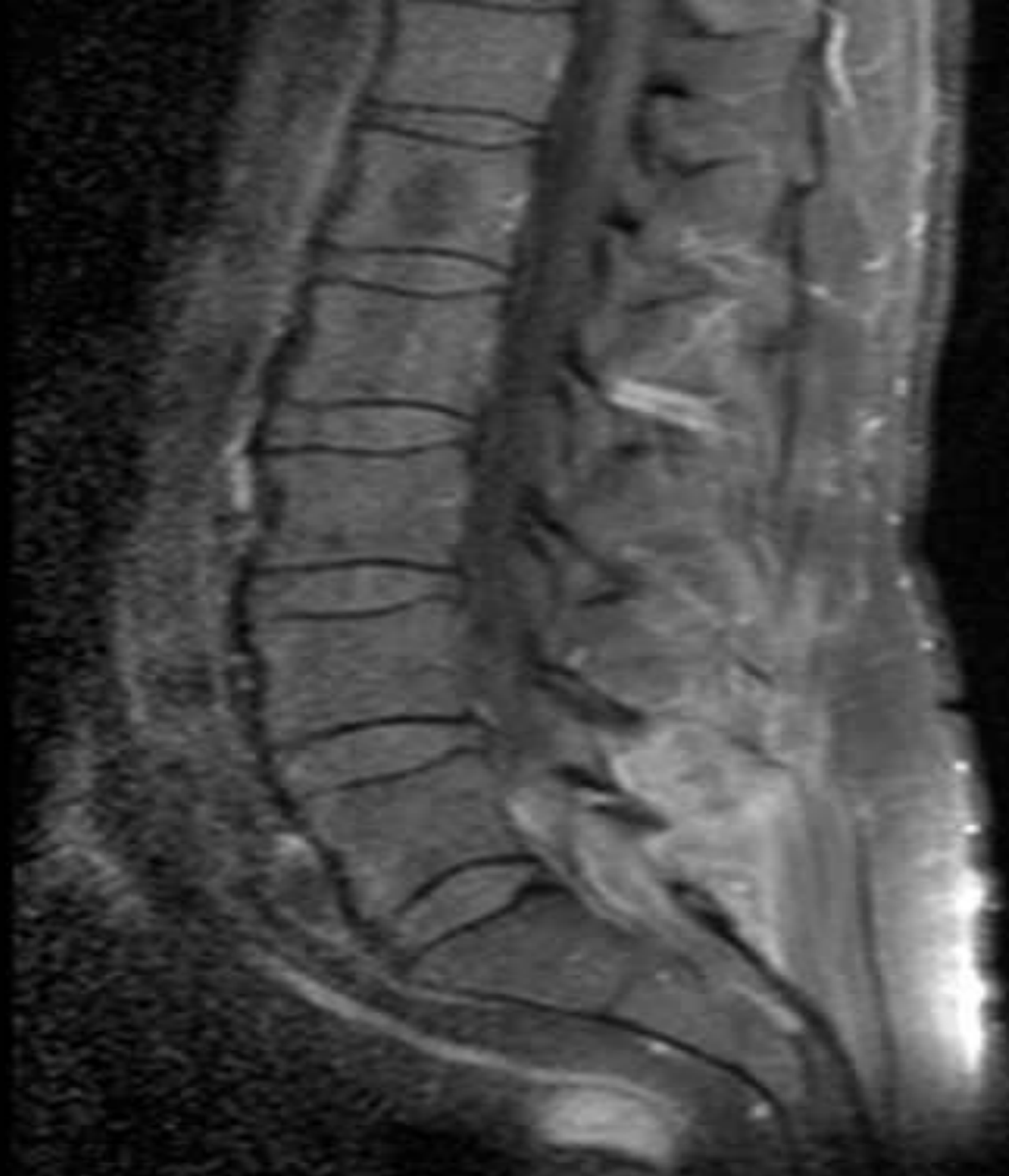

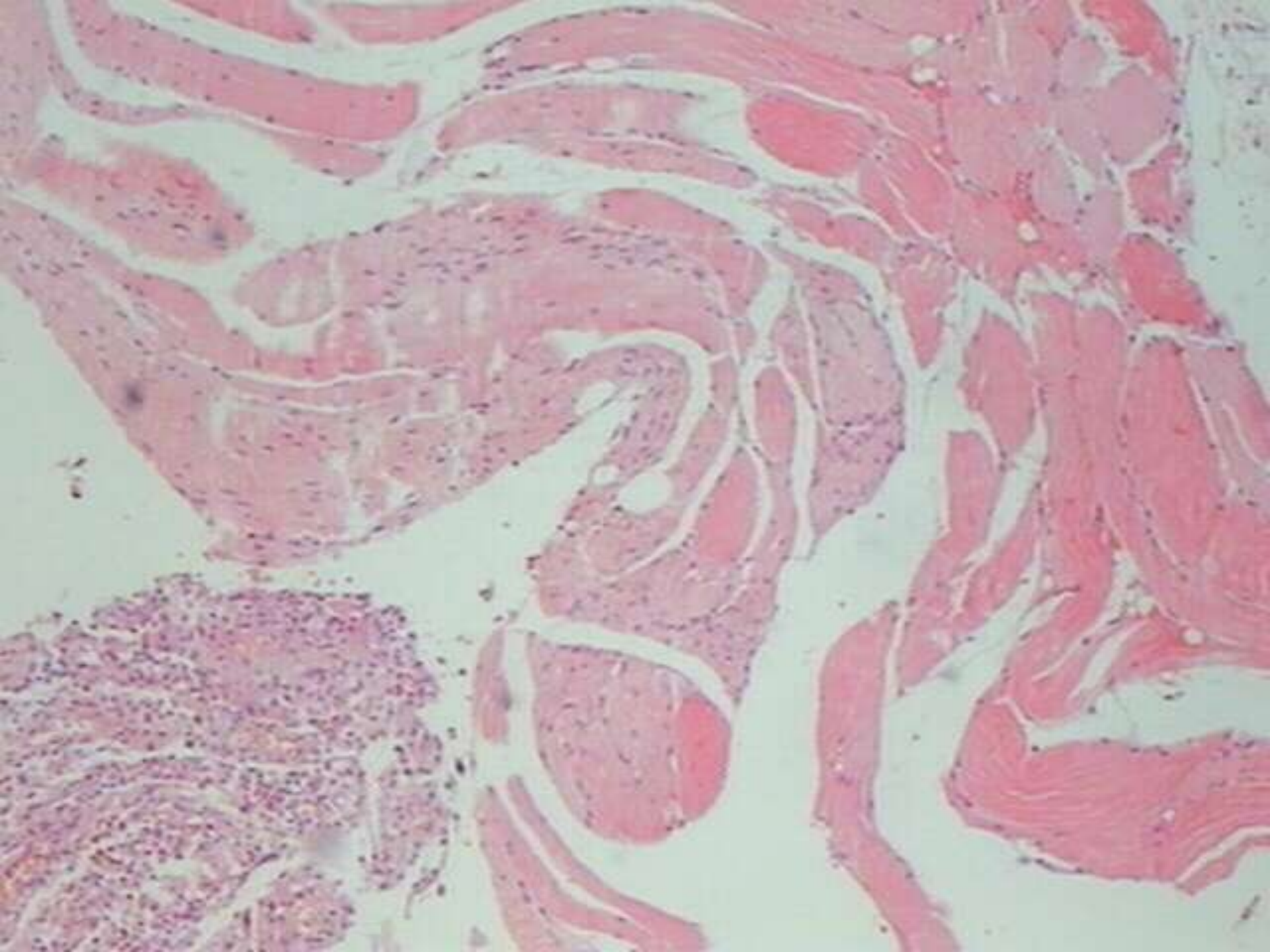
Sc8/5
TSE / M

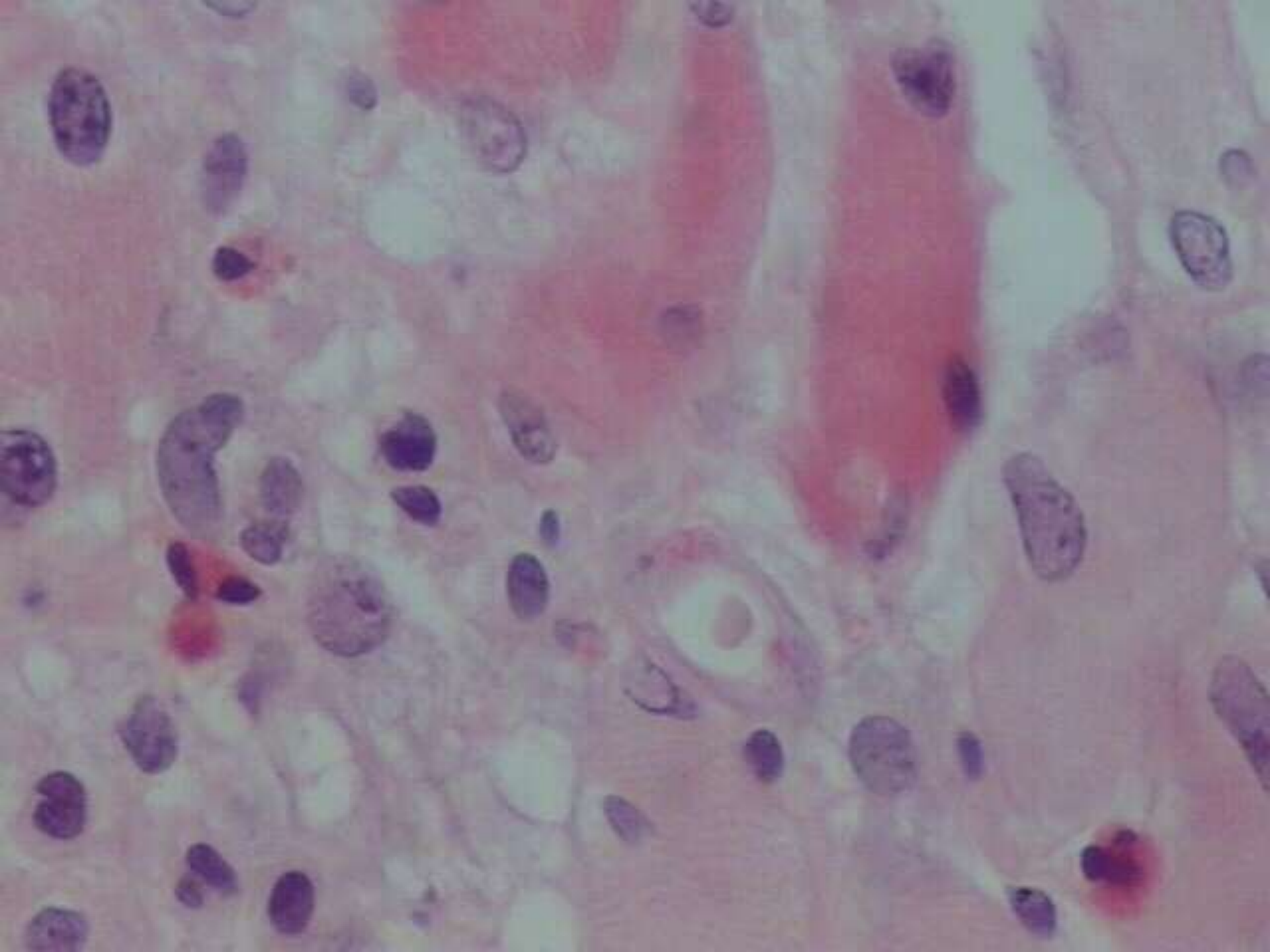
P

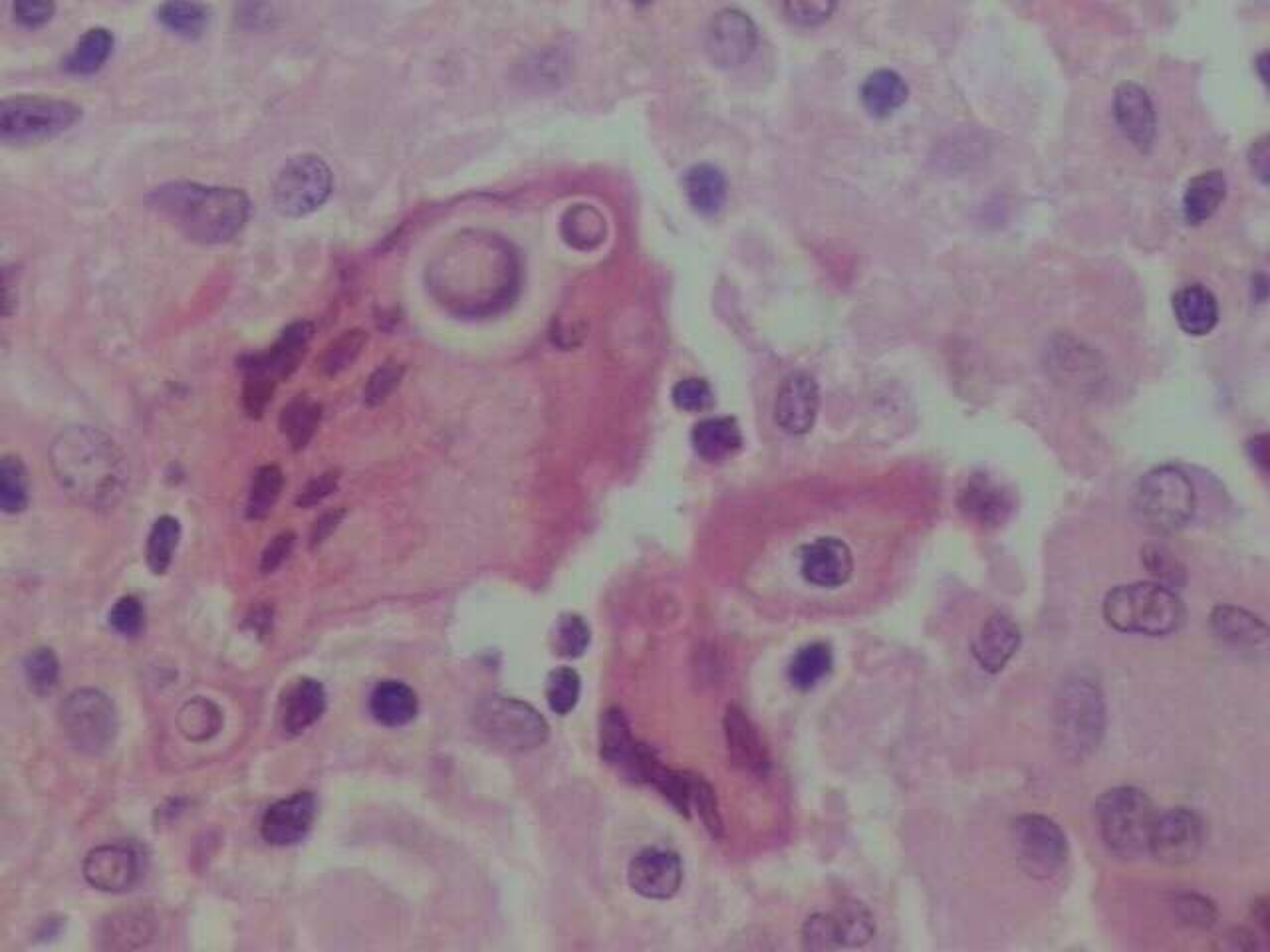AP 26
RL 8
FH -2

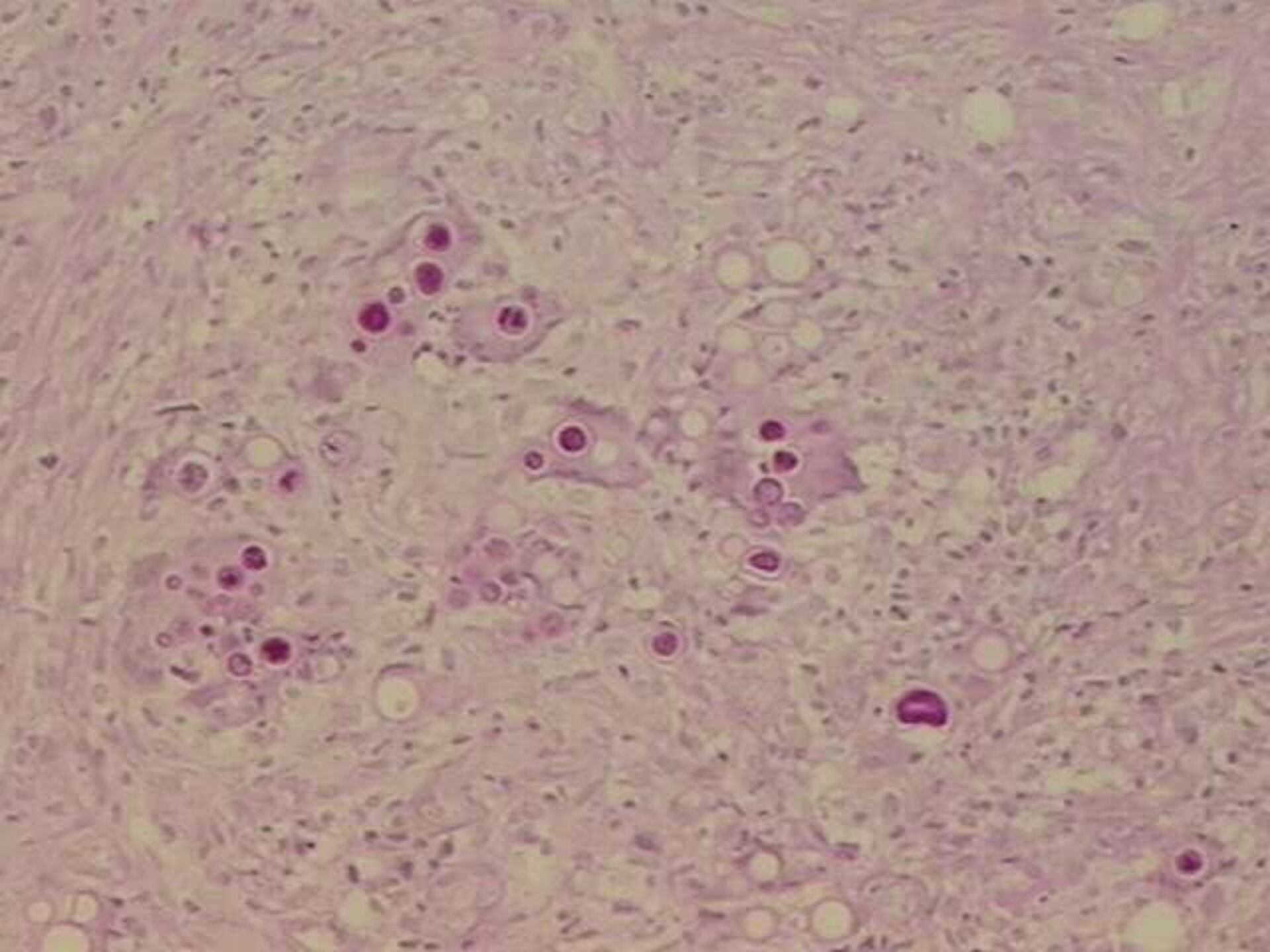
W 2399
L 1180

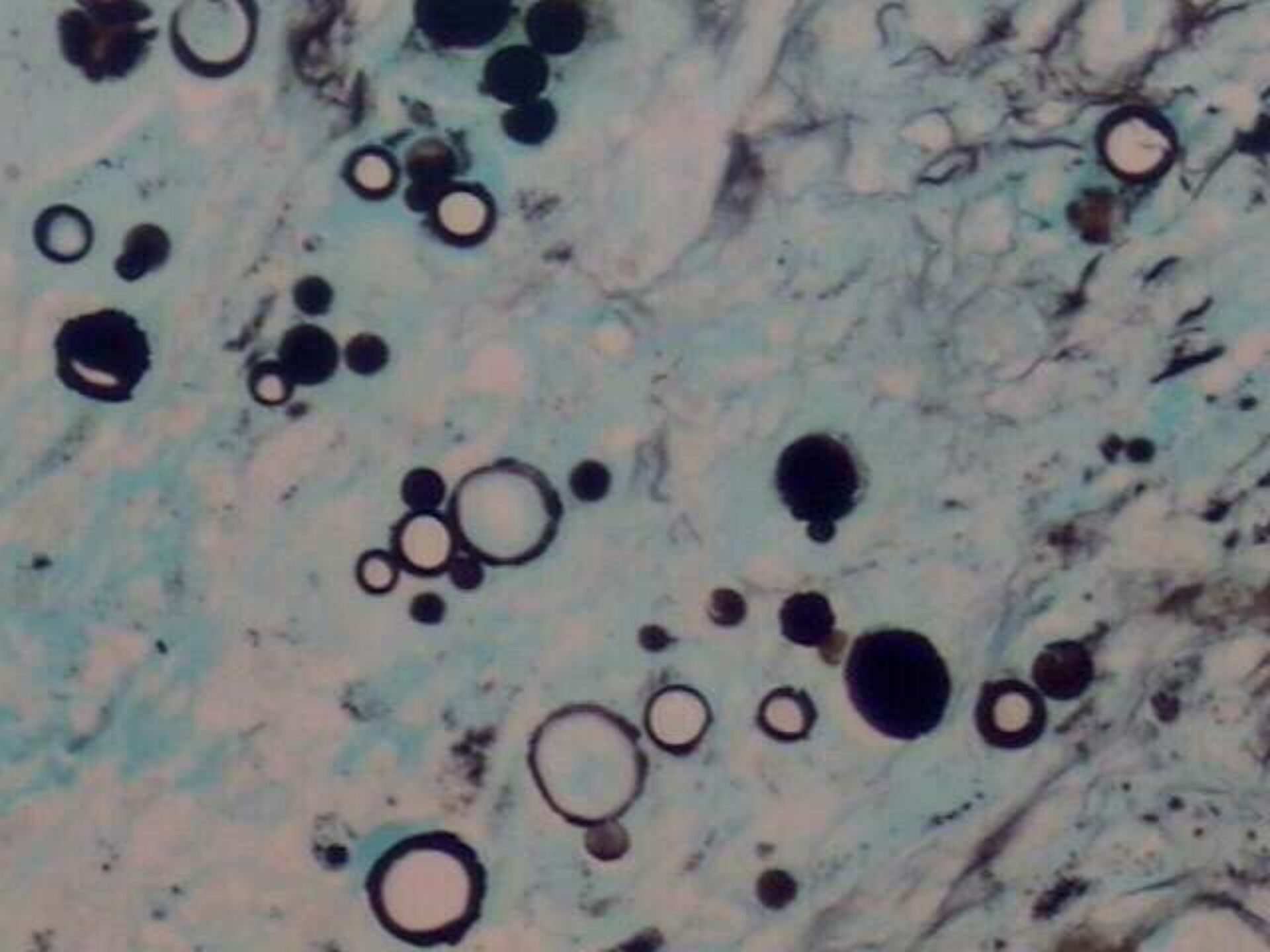


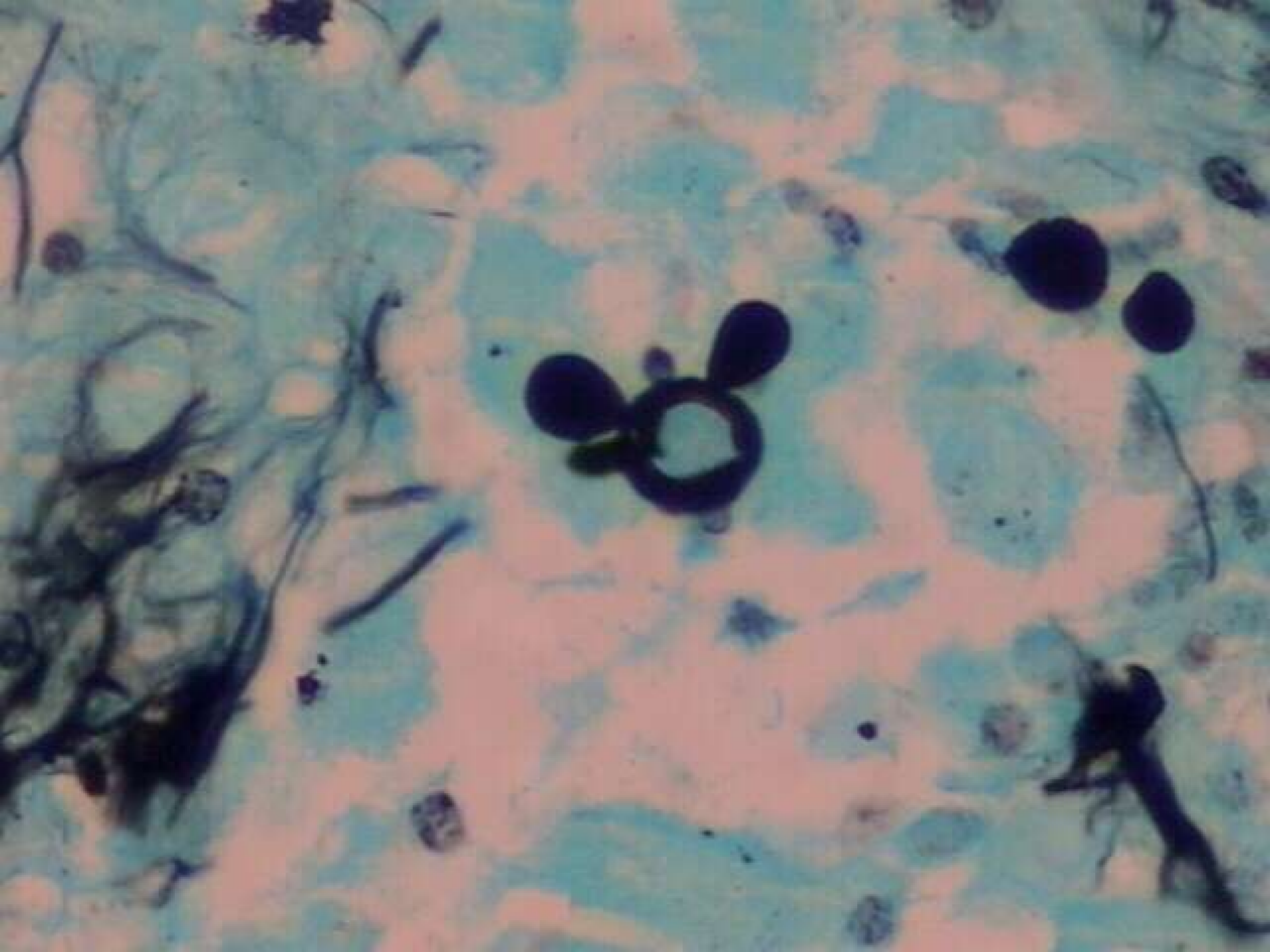
















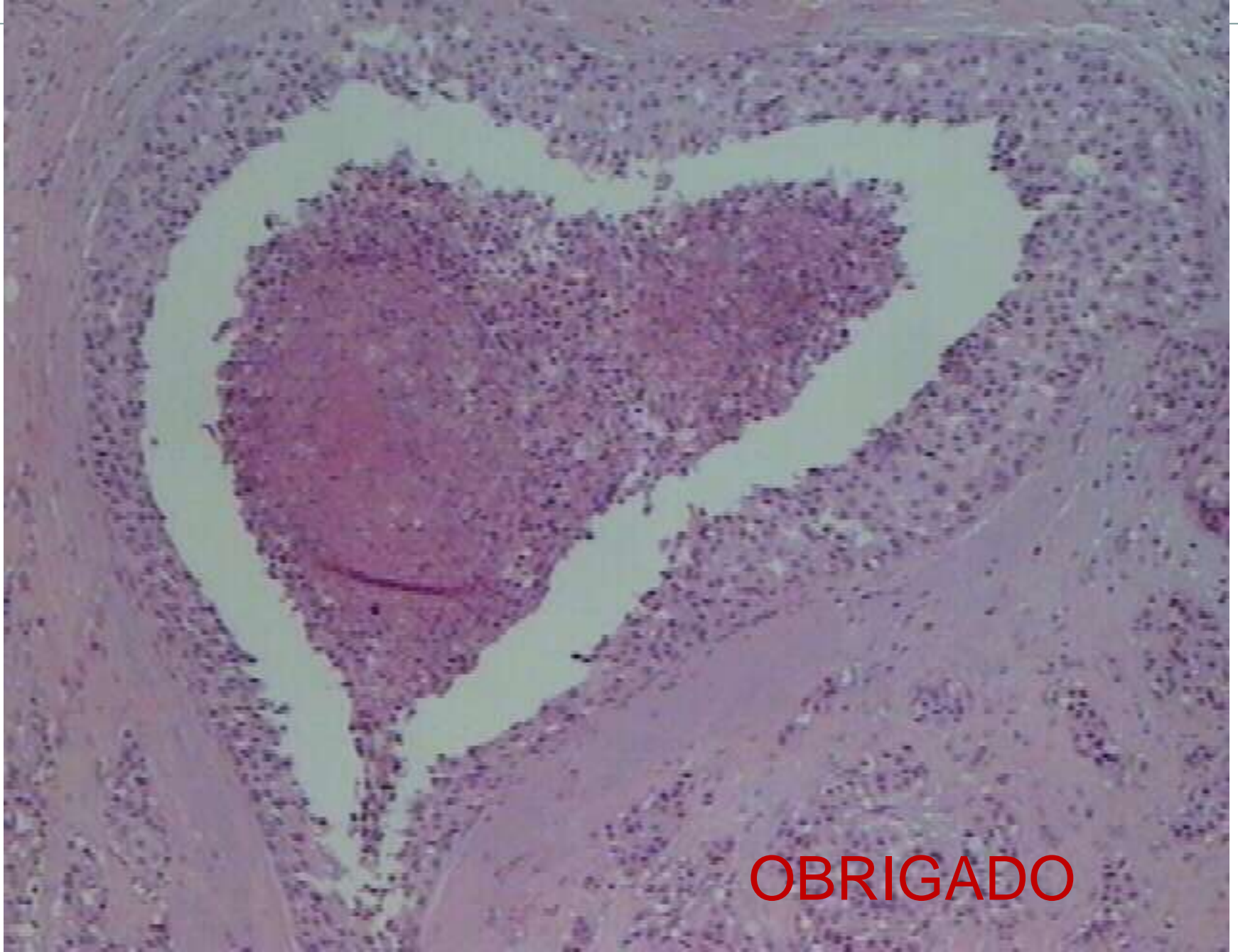


XXVIII
Congresso
Brasileiro
de Patologia
Latinoamericana
de Patologia

Congreso
de la Sociedad
de Patologia

Maceió
Brasil 2011



OBRIGADO